

Recurrent Tracheo-Oesophageal Fistula Mesh in the Trachea – A Rare Clinical Scenario

SRIKANTAI AH H C, RUDRESH H K, ASHOK A C

Key Words: Recurrent tracheo-oesophageal Fistula, Mesh, Cervical approach, Endo-tracheal intubation

INTRODUCTION

The tracheo-oesophageal fistula (TOF) is rare after an asymptomatic interval. We report a case of recurrent tracheo-oesophageal fistula which was recognized immediately; was investigated and treated early. Abnormal communication between the trachea and the oesophagus due to a benign pathology as in our case, which is presented with a swallow cough sequence, should arouse suspicion, as early diagnosis and repair are essential for a successful outcome.

CASE HISTORY

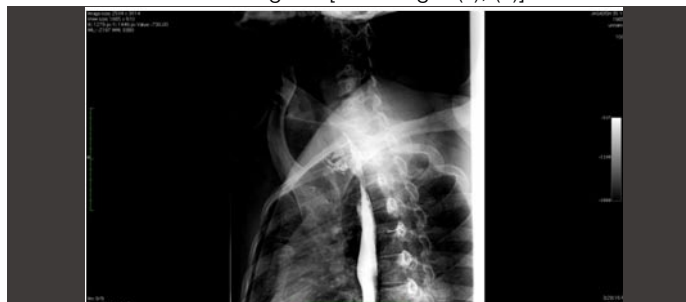Presenting Complaints: A 35year old agriculturist presented to us with cough with expectoration of 2 months duration, which was associated with drinking liquids and not due to solids in particular.

PAST HISTORY

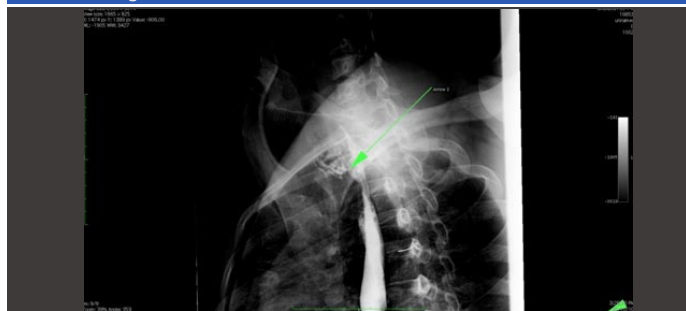1. H/o Organo phosphorus poisoning in 2004
2. Was on airway support with an endotracheal tube for 15 days, followed by tracheostomy.
3. Was decannulated after one and a half months.
4. He was diagnosed to have TOF after 2 months because of recurrent cough and choking with both liquids and solids and was repaired with Dacron mesh interposition [7].
5. The patient was asymptomatic for the last 5 years.

INVESTIGATIONS

Barium swallow: - Tracheo-esophageal fistula level of T1-T2 as observed from a bronchogram [Table/Fig 1 (a), (b)].



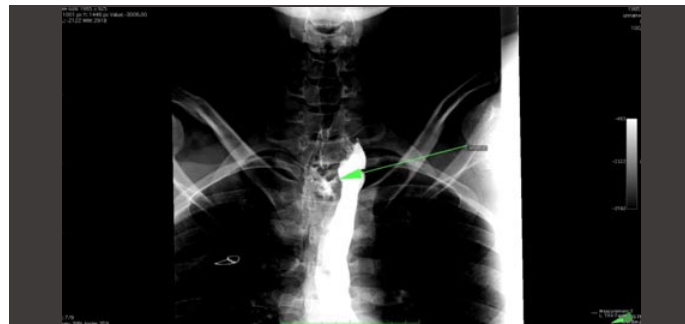
[Table/Fig 1(a)]: Barium swallow pic 1 showing the fistula at t1-t2 level with bronchogram



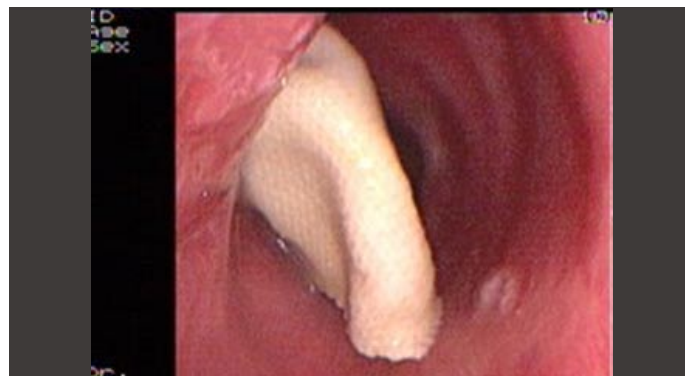[Table/Fig 1(b)]: Barium swallow

Endoscopy: - Oesophageal polypoidal growth, about 9- 10 cm from the incisors and the hiatus hernia.

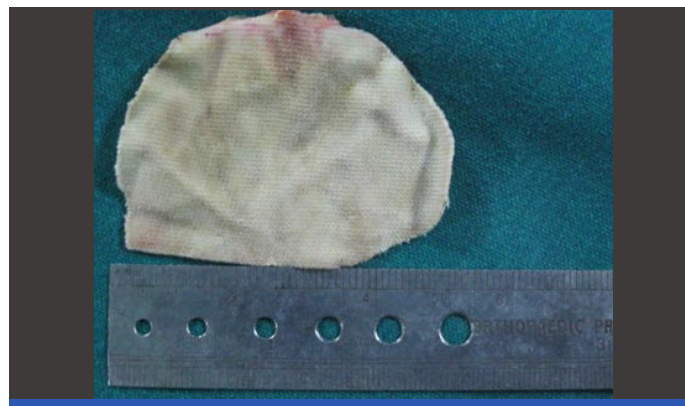
Bronchoscopy: - A mesh was seen hanging from the lateral and the posterior tracheal wall (2" proximal to the carina and 3" distal to the vocal cords) contacting opposite the tracheal wall on deep breathing and coughing. A white granulation tissue was seen behind the mesh [Table/Fig 2], [Table/Fig 3], [Table/Fig 4].



[Table/Fig 2]: Barium swallow



[Table/Fig 3]: Bronchoscopy showing the Mesh

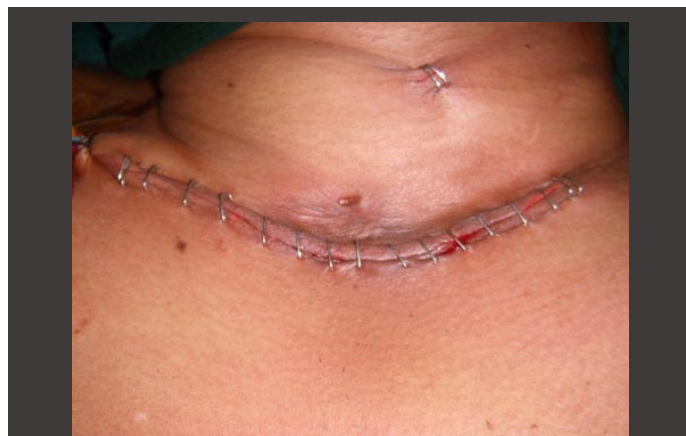

[Table/Fig 4]: Excised mesh

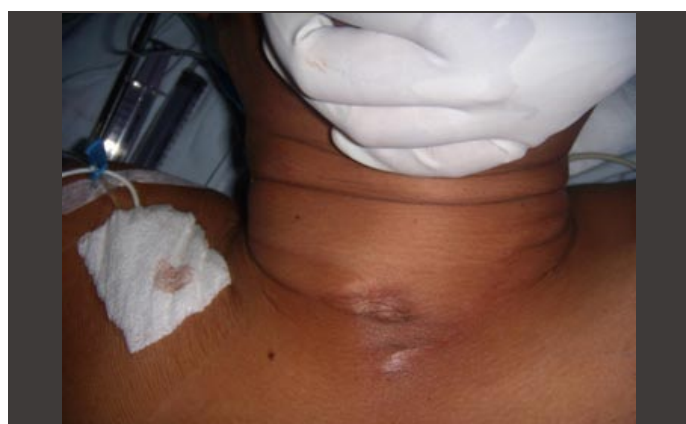MANAGEMENT

Surgery: Bronchoscopy and Mesh removal with TOF repair under general anaesthesia.

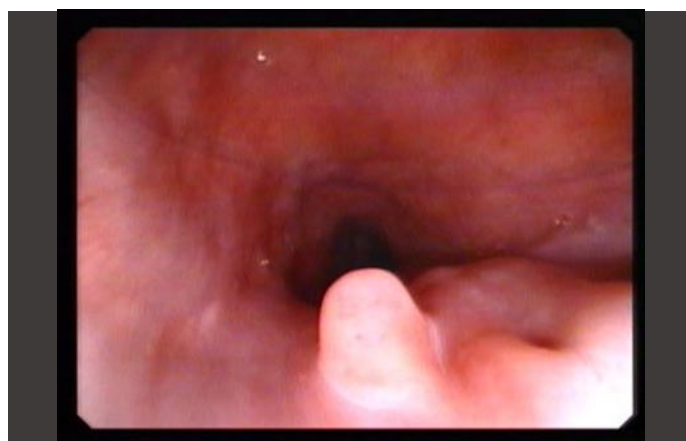Intra-Op: Fiberoptic bronchoscopy assisted intubation was done, followed by rigid bronchoscopy and mesh removal with, minimal mesh site bleeding. The cervical exploration of the TOF was undertaken. The oesophagus couldn't be identified as it was shifted grossly towards the left and lateral to the trachea. Its identification was possible only after a quick feet thinking by the anaesthetist after which an ET tube was placed in the oesophagus and transillumination was done by using a rigid ureteroscope. The oesophagus was dissected and the taped TOF was identified and excised. The trachea and the oesophagus were closed primarily and the sternal head of the sternocleidomastoid was transposed between the trachea and the oesophagus [1] [Table/Fig 5], [Table/Fig 6], [Table/Fig 7].



[Table/Fig 5]: Post-operative wound at the end of Surgery



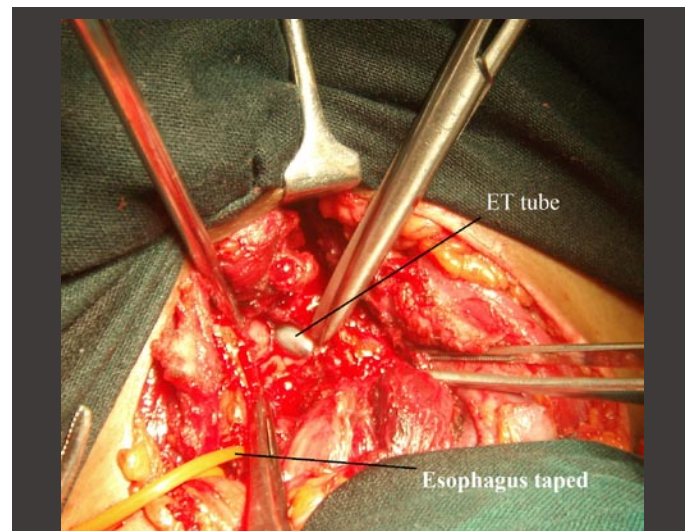
[Table/Fig 6]: Pre-operative photo showing previous scar



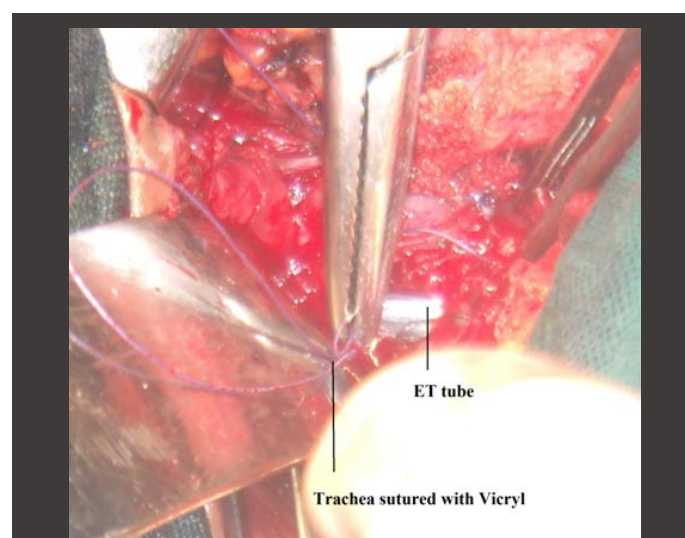
[Table/Fig 7]: Upper G.I. endoscopy view of the fistula

Post-Op : The patient was extubated on post op day 4 and he

could vocalize normally [Table/Fig 8], [Table/Fig 9].



[Table/Fig 8]: Intraoperative pic showing the oesophagus being taped.



[Table/Fig 9]: Intraoperative pic showing the trachea and the ET Tube.

DISCUSSION

Tracheo-oesophageal fistulas in adults, especially the recurrent ones, are usually caused due to malignancy, while those which are caused due to a benign pathology are rare. Non-malignant recurrent tracheo-oesophageal fistulas are caused by post-traumatic causes like trauma, penetrating injuries, endotracheal intubation [3], tracheostomy, caustic injury and mediastinitis. Surgical procedures are used like vagotomy for hiatus hernia, pulmonary resection and aortic aneurysm repair.

Endotracheal intubation can induce iatrogenic laryngeal and tracheal complications, particularly when the intubation lasts for a long time [4]. Direct surgical repair should be the procedure of choice [5].

Tracheo-oesophageal fistula is such a complication.

In thoracic tracheo-oesophageal fistula, the preferred approach should be right postero-lateral thoracotomy, which gives adequate exposure to the oesophagus, the trachea and the right main bronchus.

In cases of tracheo-oesophageal fistulas which occur above the level of the trachea, the cervical oesophagus is preferred, as in our case. As the oesophagus is devoid of serosa, the reinforcement of the repair site with available muscle flap interposition [1] is neces-

sary.

In this case, the patient was in a life threatening situation, with a large foreign body hanging loosely in the airway, with a potential threat for immediate asphyxia and sudden death.

Redoing the TOF isolation and the identification of the trachea and the oesophagus were the most difficult steps.

Injury to the surrounding major vessels and the recurrent laryngeal nerve was a potential threat.

The 1st surgical exercise is the best time for the proper management of TOFs.

A non-absorbable mesh shouldn't be used near any hollow viscus due to its propensity of migration.

CONCLUSION

Success in such a difficult case was only possible due to proper evaluation and a multidisciplinary approach, like in this case. General Surgeon, Pediatric surgeons, Anaesthetists, chest physician, cardiothoracic surgeon and surgical oncologist.

REFERENCES:

- [1] Lee L M, Razi A. Tree layer technique to close a persistent tracheo-oesophageal fistula. *Asian J Surg.* 2004; 27:336-338.
- [2] Delank W, Schma L F, Stoll, Trauma to the membranous trachea managed by ENT Surgeon W. *laryngorhinotologie.* 2002 Apr; 81(4): 299-304.
- [3] Schneider T, Storz K, Dienemann H, Hoffmann H *Ann Thorac surg.* Management of iatrogenic tracheobronchial injuries: a retrospective analysis of 29 cases (*Ann Thorac surg.* 2007). 2007; 2007 Jun; 83(6): 1960-4.
- [4] Massard G, Rong Ac C, Dabagh A, Kesser R, Hentz J G, Roeslin N, Wilhelm J M, Morand G. *Ann Thorac Surg.* 1996 May; 61(5): 1483-7. Tracheobronchial Lacerations after intubation and tracheostomy [*Ann Thorac Surg.* 1996].
- [5] G. Chir. Distal trachea and bronchial large lesions and suture reinforcement with polyglycolic acid (PGA) patch. First clinical experience. 2010 Jan-Feb; 31(1-2):10-5. *Italian.*
- [6] Ten Hallers E J, Marres H A, Vander Houwen E B, Jansen J A, Rakhorst G, Schutte H K, Van Loon J P, Verkerke G J *HeadNeck.* Experimental results of the tracheo-oesophageal tissue connector for improved fixation of shunt valves in laryngectomised patients. 2006 Nov; 28(11): 982-9.
- [7] Bardini R, Radicchi V, Paribelli P, Tosato S M, Narnee S. *Ann Thorac Surg.* Repair of a recurrent benign tracheo-oesophageal fistula with a goretex membrane. 2003 Jul; 76(1):304-6.

AUTHORS:

1. Dr. SRIKANTAIAH H C
2. Dr. RUDRESH H K
3. Dr. ASHOK A C

NAME OF DEPARTMENT(S) / INSTITUTION(S) TO WHICH THE WORK IS ATTRIBUTED:

Dept of General Surgery, M.S. Ramaiah Medical College, Bangalore-54.

NAME, ADDRESS, TELEPHONE, E-MAIL ID OF THE CORRESPONDING AUTHOR:

Dr. H C Srikantaiah, Assistant professor, Dept of General Surgery, M.S. Ramaiah Medical College, Bangalore-54.

DECLARATION ON COMPETING INTERESTS: No competing Interests

Date of Submission: **Jan 16, 2011**
Peer Review Completion: **Jan 31, 2011**
Date of Acceptance: **Feb 03, 2011**
Date of Publication: **Apr 11, 2011**