

Morphological Variations in the origin and insertion of Lumbricals of the Upper Limb in Cadavers

ASHWINI M MUTALIK

ABSTRACT

The human hand represents a revolution in evolution. The muscles of the lumbricals though small in size, have a significantly greater role to play in the intricate movements of the fingers. These muscles show anomalous origins and insertions. Hence, this study was an effort to know more about these muscles, as it is of significant value in the design of surgical procedures.

This study was conducted on 30 (both in the male and female populations) cadavers which were available from the Department of Anatomy. Dissection was carried out according to the Cunningham's manual of practical anatomy.

In the present study, many split insertions and misplaced insertions and even the absence of these muscles were noted. Apart from the anomalies in the attachments, the length, breadth, width and tendon length of all these intrinsic muscles were studied and noted.

In this study, the values of length, breadth, width and tendon length of all the lumbricals, was measured. On applying the test of significance, these values were found to be statistically significant.

Key Words: Lumbricals, Split insertions, Misplaced insertions...etc

INTRODUCTION

The human hand is a prehensile organ, it is endowed with grasping and precision movements for skilled work and it acts as a chief tactile apparatus. This is contributed by a high degree of neuromuscular co-ordination and a larger cortical representation of the hand in the sensory motor cortex of the brain. Thus, the human hand represents a revolution in evolution.

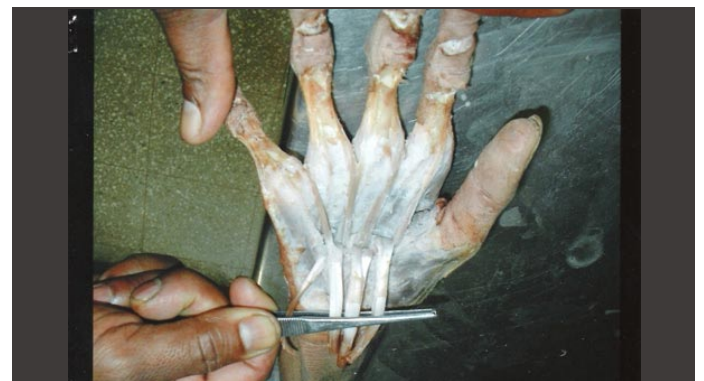Indeed, the lumbricals of the hand, by producing flexion at the metacarpophalangeal joints and at the extension at the interphalangeal joints, help in writing, stitching and any other forms of precision work. Hence, philosophically it may be said that the actions of the lumbricals of the hand are the indices of civilization of a race [1].

The lumbrical muscles, especially the 1st and 2nd ones, are used as muscle flaps for the coverage of the median nerve and its palmar branches [2]. Hypertrophy of the lumbrical muscles causes compression of the radial and ulnar collateral arteries, leading to chronic sub-ischæmia [3].

The lumbricals of the upper limb are four small muscles resembling the shape of earthworms and hence they are named so. They are numbered from the lateral to the medial side. The lumbricals take their origin in the palm from the four tendons of the flexor digitorum profundus and pass distally along the radial side of the corresponding metacarpophalangeal joint, in front of the deep transverse metacarpal ligament. Each muscle forms a narrow tendon and runs in a fascial canal, and on reaching the dorsal surface of the proximal phalanx, joins the radial margin of the dorsal digital expansion as the distal wing tendon. The first and second lumbricals are unipennate, and are supplied by the median nerve, while the third and fourth lumbricals are bipennate and are supplied by a deep branch of the ulnar nerve [1].

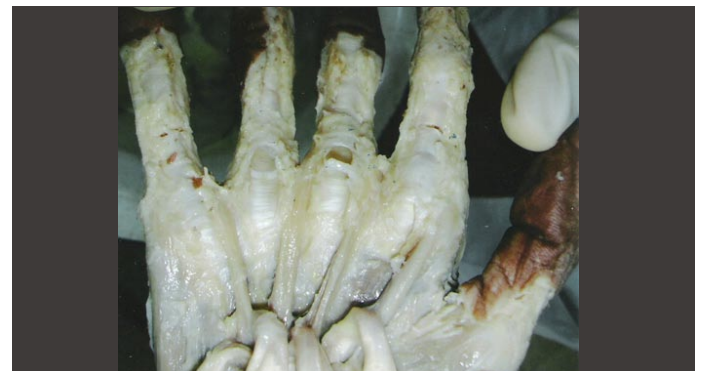Variations in the attachments of the lumbricals are common. In a study which was conducted by Mehta. H. J (1961), it was noted that the lumbricals had an occasional origin in the forearm or from a metacarpal or from the superficial instead of the deep flexor ten-

dons and that the third and fourth lumbricals originated from a single tendon instead of two [4]. [Table/Fig 1]



[Table/Fig 1]: 3rd Lumbrical showing split insertion

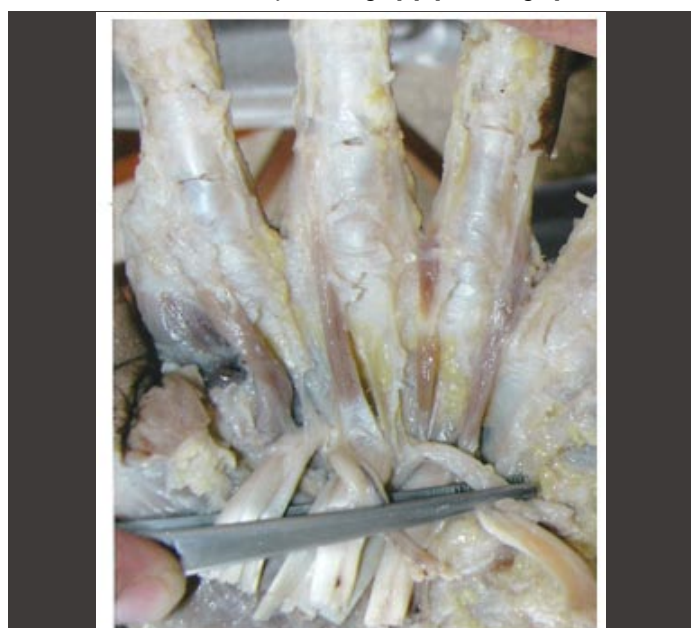
Another study which was done by Kurzumi M (2002) revealed that the lumbrical muscles originated from the intermediate tendon of the deep layer of the flexor digitorum superficialis for the index finger [5]. [Table/Fig 2]



[Table/Fig 2]: 3rd Lumbrical inserted on ulnar side of middle finger

A muscle arose from the anomalous flexor pollicis longus tendon in the region of the metacarpo phalangeal joint, passed across the narrowed first web space, joined the lumbrical belly of the index and inserted into the extensor hood of that digit. Because of its attachments and action, this muscle was given the name, 'musculus lumbricalis pollicis' [6] (Lister G 1991).

The first lumbrical was noted in a study by Singh J (2001), as a bipennate with an additional origin, extending from the distal part of the forearm. Its first origin arose from the flexor digitorum profundus in the hand, distal to the flexor retinaculum [7]. Lumbricals often show split insertions. Basu S (1960), from his study, reported fairly numerous instances in which a lumbrical tendon split to go to the adjacent sides of the two fingers, or less frequently inserted entirely on the ulnar side of the adjacent digit [8]. [Table/Fig 3]



[Table/Fig 3]: 4th Lumbrical inserted on medial side of ring finger

Singh JD (1975) found that the 3rd or 4th or both the lumbricals divided into two tendons which joined the extensor expansions of the adjacent fingers i.e. showing split insertions. In misplaced insertions, the 3rd or 4th lumbricals, instead of joining the extensor expansion on the radial side of the corresponding finger, joined one on the ulnar side of the adjacent finger, thus resulting in two lumbrical insertions in the adjacent finger and none in the corresponding finger [9].

The lumbricals also show variations in being unipennate or bipennate. If the first lumbrical is bipennate instead of unipennate, then the two heads arise from the flexor digitorum profundus and the flexor pollicis longus [10] (Goldberg S 1970). [Table/Fig 4]

Lumbricals	Right hand	Left hand
Normal	43.3%(13)	53.3%(16)
Proximal origin	26.6%(8)	16.6%(5)
Bipennate 2nd lumbrical	3.3%(1)	3.3%(1)
Split insertion of 3rd lumbrical	16.6%(5)	10%(3)
3rd lumbrical inserted on medial side of middle finger	3.3%(1)	Nil
4th lumbrical insertion on ulnar side of ring finger	6.6%(2)	13.3%(4)
Split insertion of 4th lumbrical	0.0%	3.3%(1)

[Table/Fig 4]: Comparison among the lumbricals of right and left hand observed in 30 cadavers

A rare variation of a unipennate fourth lumbrical muscle of the right hand was observed. At the level of the 5th metacarpophalangeal joint, its tendon divided into one radial and one ulnar slip. Both heads surrounded the tendons of the flexor digitorum superficialis

and the profundus muscles, and found their insertion into the flexor digitorum superficialis tendon, as well as their bony attachment found its insertion into the proximal phalanx and even more into the middle phalanx [11] (Windisch G 2000).

Studies done by Braithwaite F (1948) quoted evidence that more than four lumbricals occurred frequently and that the third was most frequently missing [12]. In another study, there were no instances of an additional lumbrical muscle and they found that it was the fourth lumbrical which is missing more frequently and not the third one [8]. In another study which was conducted, it was noted that the fourth lumbrical was missing more frequently [5].

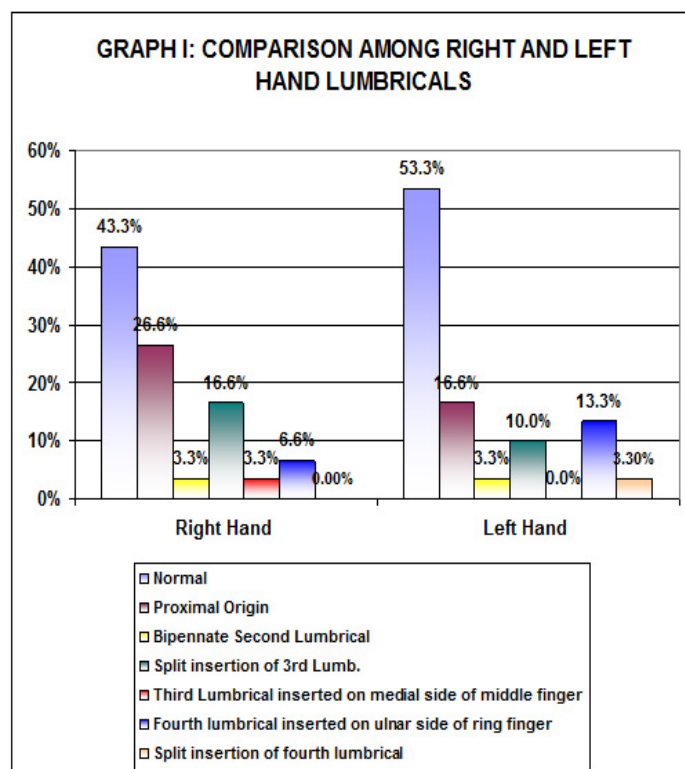
MATERIAL AND METHODS

Source of the data

This study was done on 30 cadavers which were available from the Department of Anatomy.

Method

The dissection was carried out according to the Cunningham's manual of practical anatomy as follows: A longitudinal incision was taken from the distal end of the flexor retinaculum, up to the level of the metacarpophalangeal joint of the middle finger. The skin, the superficial fascia, the deep fascia and the flexor retinaculum were dissected and reflected. Then, the palmar aponeurosis and the slips which pass from its distal margin to each of the fingers was dissected and reflected. Then, the tendons of the flexor digitorum superficialis and the flexor digitorum profundus were reflected distally. The lumbrical muscles which were situated at the distal end of the flexor digitorum profundus tendons were carefully observed. The lumbrical muscles were followed to their tendons which pass with the proper digital vessels and nerves to the lateral side of the base of each finger and later, the tendons of each of the lumbrical muscles were traced up to their insertion. [Table/Fig 5]



[Table/Fig 5]: Comparison among right and left hand lumbricals

Observations

The following parameters were noted:

1. Site of origin and insertion of the lumbricals.
2. The architecture of the muscles was noted i.e. unipennate or bipennate pattern.
3. The length, breadth and width of the muscle bellies of the lumbricals were measured.
4. The tendon lengths of all the lumbricals were also measured.

RESULTS

[Table/Fig 6]

	Right Hand			Left Hand			p	T
	Min.	Max.	Aver.	Min.	Max.	Aver.		
Length in Cms								
1	4.50	7.30	5.53	4.20	7.00	5.95	0.049	2.003
2	3.50	6.75	5.10	3.90	7.30	5.77	0.097	1.685
3	3.20	6.80	5.48	3.80	6.80	5.43	0.068	1.853
4	3.00	6.60	4.79	3.80	6.60	5.18	1.273	0.208
Breadth in Cms								
1	0.40	1.30	0.66	0.40	1.30	0.64	2.239	0.812
2	0.30	1.30	0.52	0.35	1.40	0.60	0.262	1.113
3	0.30	1.10	0.41	0.30	1.10	0.53	0.347	0.947
4	0.20	1.00	0.37	0.30	1.10	0.48	0.044	2.060
Width in Cms								
1	0.25	0.90	0.46	0.30	1.00	0.47	0.466	0.733
2	0.20	1.00	0.36	0.30	1.10	0.40	0.214	1.256
3	0.20	1.00	0.37	0.20	1.10	0.34	0.550	0.664
4	0.15	0.80	0.33	0.20	0.80	0.35	0.729	0.348
Tendon Length in Cms								
1	1.00	3.40	2.30	1.60	3.40	2.45	0.345	0.952
2	1.10	3.40	2.38	1.10	3.40	2.49	0.488	0.699
3	0.85	3.10	2.23	1.20	3.20	2.43	0.220	1.241
4	0.95	3.10	2.06	0.90	3.00	2.13	0.655	0.450

[Table/Fig 6]: Lumbricals

In the present study, the right hand lumbricals [43.3% [13]] were normal, 26.6% [8] hands showed a proximal origin from the tendons of the flexor digitorum profundus and 3.3% [1] of the second lumbricals were bipennate. 6.6% [2], of the fourth lumbrical tendons were inserted on the ulnar side of the ring finger, 16.6% [4], of the third lumbricals showed split insertion and in 3.3% [1], the lumbricals were inserted on the medial side of the middle finger. On the left hand, 53.3% [16] of the lumbricals were normal. The second lumbrical was bipennate in 3.3% [1], 16.6% [4] showed a proximal origin from the tendons of the flexor digitorum profundus, 10% (3), of the third lumbricals showed split insertion and 3.3% [1], of the fourth lumbricals showed split insertion, while 13.3% [4], of the fourth lumbricals were inserted on the ulnar side of the ring finger. [Table/Fig 7]

Authors	No of hands examined	2 nd	3 rd	4 th
Eyler and Markee (1954)	33	--	5 (15.6%)	2 (6.06%)
Basu and Hazary (1960)	72	2 (2.8%)	15 (20.8%)	8 (11.2%)
Mehta and Gardner (1961)	75	1 (1.3%)	29 (38.7%)	6 (8%)
J.D. Singh, P. B. Raju and Shamer Singh (1975)	107	--	29 (27.1%)	27 (25.20%)
Present Study	60	--	7 (13.3%)	1 (1.66%)

[Table/Fig 7]: Comparison of frequency of split insertion of hand lumbricals as reported by various authors

[Table/Fig 8]

Authors	No of hands examined	3 rd	4 th
Eyler and Markee (1954)	33	1 (3.03%)	2 (6.06%)
Basu and Hazary (1960)	72	9 (12.5%)	4 (5.6%)
Mehta and Gardner (1961)	75	7 (9.3%)	6 (8%)
J.D. Singh, P. B. Raju and Shamer Singh (1975)	107	2 (1.86%)	10 (9.34%)
Present Study	60	1 (1.66%)	5 (9.95%)

[Table/Fig 8]: Comparison of frequency of misplaced insertion of hand lumbricals as reported by various authors

DISCUSSION

The pre-eminent position that man enjoys amongst the animals, is partly due to the functional specialization of the human hand that can perform very intricate and highly skilled precision movements. In the present study, it was found that 3.3% [1] of the 2nd lumbricals in both the hands were bipennate. It was also found by Siegel DB (1995), that in cases of the carpal tunnel syndrome and in those in which repetitive hand motions were performed, the lumbricals had a significantly larger and proximal origin in the carpal tunnel, which could be the cause of the carpal tunnel syndrome [13]. In the present study, it was observed that 26.6% [8] of the cadavers in the right hand and 16.6% [5] in the left hand, had the proximal origin of the lumbricals, especially from the flexor digitorum profundus and the flexor digitorum superficialis.

A study was conducted by Joshi SD (2005) on 70 normal hands to know the functional significance and variations of the lumbricals. It was found that 50% cases of the first lumbrical was bulky, 45% of the 2nd lumbrical was bipennate and 20% showed proximal attachment [14].

In a study which was conducted on the variations in the lumbricals, it was found that the absence of the 4th lumbrical was very common and that it was absent in 3% of the cases. In contrast to this study, the authors revealed 1.4% and 5.3% of the cases to have the absence of the 4th lumbrical.

Misplaced insertions i.e. the lumbrical being inserted to the ulnar side of the adjacent extensor expansion, is also not uncommon. Similar findings, that is, 3.3% of the 3rd lumbrical and 6.6% of the 4th lumbrical in the right hand and 13.3% of the 4th lumbrical in the left hand, showed misplaced insertions in the present study.

CONCLUSION

In the present study, the values of length, breadth, width and tendon length of all the lumbricals of the right and left side hands were compared. On applying the test of significance, these values were found to be statistically significant.

1. The length of the 1st lumbrical of the left hand was more than that of the right hand ($P = 0.049$).
2. The breadth of the 4th lumbrical of the left hand was more than that of the right hand. ($P = 0.044$)

ACKNOWLEDGEMENTS

With a profound sense of gratitude and humbleness, I express my most sincere thanks to Dr.G.B.Rairam, HOD, my mentor Dr.G.C.Javalagi and all my colleagues under whose constant guidance, inspiration, encouragement and supervision, I could successfully complete my present study in the Department of Anatomy of S. Nijalingappa Medical College, Bagalkot.

I am thankful to my loving parents, in-laws, daughters and son, who have been the wind below my wings.

I certainly owe thanks to my friend, Ms. Surekha Kamble, who helped me directly or indirectly in accomplishing this work.

I thankfully acknowledge the help of the technical and menial staff of the Department of Anatomy for their co-operation.

My husband, Mr. V. J. Markod, deserves to be thanked in more ways than one, whose role has been all the more credit worthy.

REFERENCES:

- [1] Datta AK. Essentials of Human Anatomy. 2nd Ed. Calcutta: Current Books International 1995.
- [2] Koncilia H, Kuzbari R, Worseg A, Tschabitscher M, Holle J. The lumbrical muscle flap: anatomic study and clinical application. J Hand Surg [Am]. 1998; 23(1):111-9.
- [3] Chaudruc JM, Florenza F, Riviere C, Arnaud JP. White finger and hypertrophy of the lumbrical muscles. Chir Main. 2000 Sep; 19(4):232-4.

- [4] Mehta H.J, and Gardner WU. A study of lumbrical muscles in the human hand. *Am. J. Anat* 1961; 109: 227.
- [5] Kurzumi M, Karwai K, Honma S, Kodama K. Anomalous lumbrical muscles arising from the deep surface of flexor digitorum superficialis muscles in man. *Ann Anat.* 2002; 184(4):387-92.
- [6] Lister G. Musculus lumbricalis pollicis. *J Hand Surg [Am]*. 1991; 16(4): 622-5.
- [7] Singh G, Bay BH, Yip GW, Tay S. Lumbrical muscle with an additional origin in the forearm. *ANZ J Surg* 2001; 71: 301-2.
- [8] Basu S, Hazary SS. Variations of the lumbrical muscle of the hand. *Anat. Rec.*, 1960; 136; 501-4.
- [9] Singh JD, Raju PB, Singh Shamer. Anomalous insertion of Hand Lumbricals. *J Anat Soc India* 1975; 24(3): 122-5.
- [10] Goldberg S. The origin of the lumbrical muscles in the hand of the South African native. *The Hand* 1970; 2: 168-71.
- [11] Windisch G. The fourth lumbrical muscle in the hand: A variation of insertion on the fifth finger. *Surg Radiol Anat.* 2000; 22 (3-4): 213-5.
- [12] Braithwaite F, Channel GD, Moore FT, Whillis J. The applied anatomy of the lumbrical and interosseous muscles of the hand. *Guy's Hosp. Reports*, 1948; 97: 185-95.
- [13] Siegel DB, Kuzma G, Eakins D. Anatomic investigation of the role of lumbricals muscle in carpal tunnel syndrome. *J. Hand Surg (Am)* 1995; 20(5): 860-3.
- [14] Joshi SD, Joshi SS, Athavale SA. Lumbrical Muscles and Carpal Tunnel. *J Anat Soc India* 2005; 54(1): 12-5.

AUTHORS:

1. Dr. ASHWINI M MUTALIK

NAME OF DEPARTMENT(S) / INSTITUTION(S) TO WHICH THE WORK IS ATTRIBUTED:

Dept of Anatomy, S. N. Medical College, Bagalkot

NAME, ADDRESS, PHONE, E-MAIL ID OF THE CORRESPONDING AUTHOR:

Dr. Ashwini M. Mutalik, Asst. Professor, Dept of Anatomy, S. N. Medical College, Bagalkot

Email: dr.ashwinimutalik@gmail.com, Phone: 9900130146

DECLARATION ON COMPETING INTERESTS: No competing Interests

Date of Submission: **Nov 07, 2010**
Peer Review Completion: **Dec 29, 2010**
Date of Acceptance: **Jan 29, 2011**
Date of Publication: **Apr 11, 2011**