

# Iatrogenic Subcutaneous Emphysema of Endodontic Origin – Case Report with Literature Review

LORA MISHRA<sup>1</sup>, SWARNAV PATNAIK<sup>2</sup>, SANGRAM PATRO<sup>3</sup>, NITAI DEBNATH<sup>4</sup>, SATYARANJAN MISHRA<sup>5</sup>

## ABSTRACT

Surgical emphysema is well known and many case reports have been published on this. Many authors have reported this as a complication post dentoalveolar treatment. Diffusion of air into facial planes and periorbital area during endodontic procedures has been rarely reported. The use of three way air syringe and forceful irrigation of root canal can lead to surgical emphysema of subcutaneous tissue planes in and around the teeth which are involved. This case report highlights one such complication seen during endodontic treatment, discusses aetiology, complications and conservative management of this dental office emergency.

**Keywords:** Diffusion, Iatrogenic diseases, High pressure air instruments, Root canal therapy

## CASE REPORT

A local dentist referred a 53-year-old female patient with swelling and redness below her left eye, to our hospital. She had developed swelling below her left eye, 10 minutes after conventional endodontic treatment (with sodium hypochlorite and EDTA) of left maxillary central incision. She also complained of persistent and severe sensitivity at the same tooth region and face [Table/Fig-1]. The local dentist, when consulted, admitted that compressed air from three way syringe had been used to dry the canal.

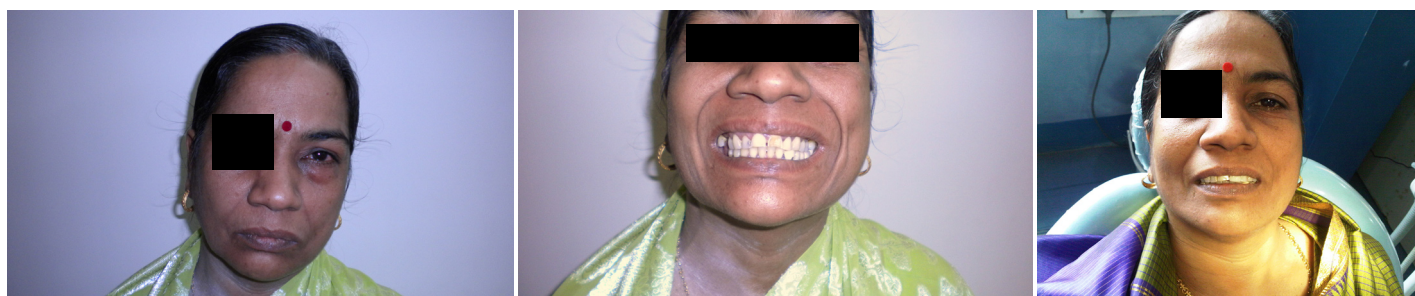On examination, she was found to have soft swelling with obvious unilateral crepitus below the suborbital region. The swelling was diffuse. The extent of swelling was superiorly from lower eyelid to 3 cm from inferior border of mandible inferiorly. Medially, the extent of swelling was 1cm from bridge of nose to the outer canthus of eye laterally. Eye on same side appeared smaller and it was reddish in colour [Table/Fig-1].

The patient was prescribed tab Augmentin Duo 625mg B.D. for five days. Over the next 7 days, the subcutaneous emphysema resolved progressively and she became asymptomatic [Table/Fig-2]. The fascia under the eye also appeared normal [Table/Fig-2 and 3].

## DISCUSSION

The word emphysema is derived from Greek word, 'whick', which means 'to blow in' [1]. The use of air syringe for drying the canal during root canal procedure is common practice of most of the clinicians [Table/Fig-4]. Air/ gas can be introduced to soft tissue spaces through either root canal or dentoalveolar membrane [Table/Fig-5] [2]. Two procedures in endodontics, if carried out improperly, have the potential to cause a problem. Firstly, during canal preparation, a blast of air to dry the canal, and secondly,

during apical surgery, air from a high-speed drill, can lead to air emphysema. In our case, the air entrapment in sub-orbital space was caused by air blown through air syringe into the root canal. Air syringe operates at 20-25 PSI, this might result in air embolism during root canal therapy [3]. Air can escape into many adjacent spaces [Table/Fig-5]. This might lead to complications [Table/Fig-6]. Differential diagnosis of this complication, that may also produce volume increase, are haematomas, allergic reactions or angio-oedema [4]. The main characteristic signs and symptoms of subcutaneous emphysema are diffuse swelling and characteristic palpable crepitus. Hayduk et al., reported that crepitus was a pathognomonic sign of tissue space emphysema and that therefore, it could be easily distinguished from angio-oedema [Table/Fig-7] [5]. Radiographs can also be more definitive diagnostic clue for identification of surgical emphysema [Table/Fig-8] [26]. These facial and suborbital planes consist of loose connective tissue containing potential spaces between layers of muscles, organs and other structures. Once air enters the deep soft tissue under pressure, as is the case when air-water cooled handpieces or air-water syringes are used, it will follow the path of least resistance through the connective tissue, along the facial planes, spreading to distant spaces [26]. Most patients who develop subcutaneous emphysema after dental procedures have only moderate local swellings [27]. Root canal treatment induced emphysema resolves in few days, administration of prophylactic antibiotics and analgesics can prevent complications because dissemination of oral flora microorganisms along the emphysematous tracts may be responsible for soft tissue infections (e.g. deep neck infection and mediastinitis) and sepsis [28]. This case which has been presented here is unique, as there was only suborbital emphysema with slight redness of the eye [Table/Fig-9].



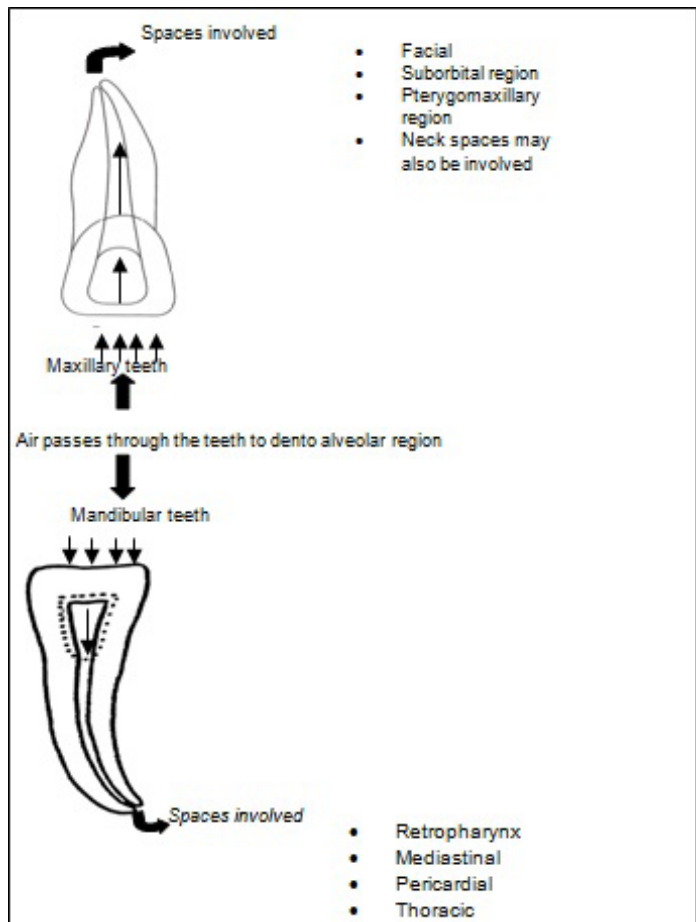
[Table/Fig-1]: Swelling in left suborbital space

[Table/Fig-2]: Post 1 week after antibiotic and analgesics administration

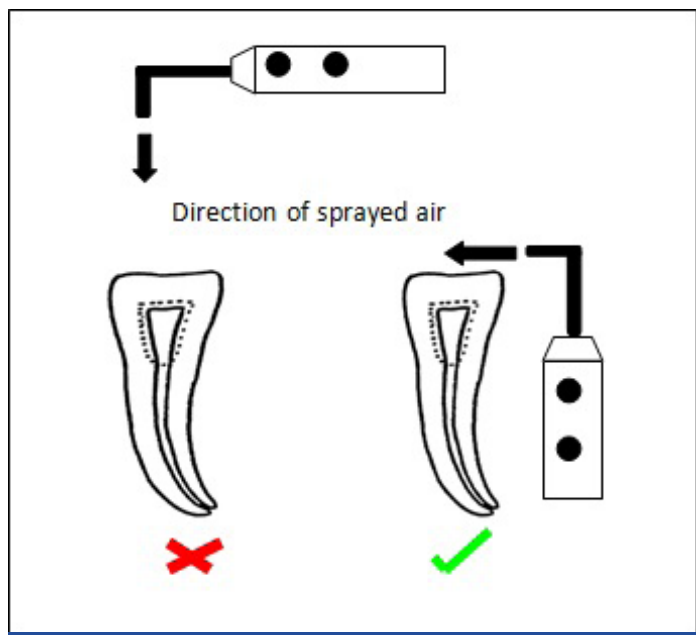
[Table/Fig-3]: Root canal treated and post 2 week the facia under the left eye appears normal

Pressure drying of any canal seems very unwise and especially so, where the apex is size 25 or larger. In addition to the larger diameter, air flow is probably aided, as the instruments smooth irregularities of the canal walls [29]. Low pressure and side vent needles have been suggested to lessen the danger. But study done by Bradford et al., stated that there was no way to ensure complete safety when canals were dried with pressurized air instead use of vacuum. Rather, air under pressure, may be a superior means for canal drying [30]. If at all air syringe had to be used, Jerome suggested that the horizontal

**[Table/Fig-4]:** Equipment and procedure that can lead to surgical emphysema during endodontic procedure



**[Table/Fig-5]:** Subcutaneous spaces that may get involved if forced air passes through access cavity



**[Table/Fig-6]:** Depicting the direction of air syringe used during drying of root canal

Ref no.	Author	Year	Area involved
[6]	Shovelton	1957	Facial, suborbital region & neck
[7]	Sumita M, Suzuki S, Fujii K	1970	Facial subcutaneous tissue
[8]	Walker JE	1975	Facial subcutaneous tissue
[9]	Vasileva M	1977	Face and neck subcutaneous tissue
[10]	Arieh Y. Kaufman	1981	Facial subcutaneous tissue
[11]	P.N.Hirschmann and R.T. Walker	1983	Facial subcutaneous tissue
[12]	Falomo OO.	1984	Facial subcutaneous tissue
[13]	Bottinelli G, Arrigoni C, Flecchia G	1986	Facial subcutaneous tissue
[14]	O. Nahlieli, A. Neder	1991	Pneumomediastinum
[15]	Wright KJ, Derkson GD, Riding	1991	Facial subcutaneous tissue
[16]	KH	2001	Cervicofacial
[17]	Penna KJ, Neshat K	2004	Pneumomediastinum and facial subcutaneous tissue
[18]	Y Smatt et al	2007	Prevertebral region.
[19]	Sujeet K, Shankar S	2009	Facial subcutaneous tissue
[20]	de Sermeño RF et al	2009	Neck and periorbital region
[21]	Parkar A et al	2010	Cervicofacial & Pneumomediastinum
[22]	Kim Y, Kim MR, Kim SJ Coulier J, Deprez FC	2011	Facial and below the eye subcutaneous tissue
[23]	Lokman Onur Uyanik et al	2011	Periorbital area
[24]	Hsu HL, Chang CC, Liu KL	2011	Facial subcutaneous tissue and eye
[25]	Durukan P et al	2012	Cervicofacial emphysema and pneumomediastinum

**[Table/Fig-7]:** Case Reports on Endodontic treatment induced surgical emphysema Also add etiology, treatment and complication if any in this table. it seems incomplete in present state

Early Complication	Delayed complications
Involve retropharyngeal, mediastinal and peritoneal spaces which may lead to cardiopulmonary distress.	Secondary infections The secondary infection of the necrotic infraorbital tissues by S. aureus and mortality from sepsis and air embolism

**[Table/Fig-8]:** Complications of Subcutaneous emphysema

Immediate	Subsequent
Local swelling Crepitus Local discomfort	Diffuse swelling Local erythema Pyrexia and Pain

**[Table/Fig-9]:** Clinical features of cervicofacial emphysema

Diagnostic clues
Soft tissue radiograph of neck Anteroposterior chest radiograph Lateral chest radiograph CT scan

**[Table/Fig-10]:** Severe subcutaneous emphysema the above mentioned radiographs can reveal the involvement and spread of emphysema in subcutaneous spaces

use of air syringe, in other words, Venturi effect could aid canal drying [Table/Fig-5] Air should be blown across the canal opening to aid drying, and a hand-piece should be employed, that exhausts the spent air out the back of the hand-piece rather than into the operating field [Table/Fig-5] [31].

Various events in the peri-operative period, including endotracheal intubation and positive pressure ventilation, which have also been reported in association with subcutaneous emphysema, can be prevented by following the manufacturer's recommendations, as to the proper use and maintenance of the air-driven turbine. The usage of rubber dam during dental procedure can also reduce the risk of surgical emphysema. After a dental or surgical procedure, postoperative instructions should include avoidance of coughing,

smoking, blowing the nose, using straws, vomiting, or any other activity that may increase pressure in the oral cavity. Excessive inspiratory pressures and volumes should be avoided in cases requiring endotracheal intubation and care should be taken to decrease injury to the tracheal mucosa [Table/Fig-10].

## CONCLUSION

Iatrogenic subcutaneous emphysema can have serious and potentially life-threatening effects. When subcutaneous emphysema does arise, it must be quickly diagnosed, understood, and effectively managed, to reduce the incidence of further complications.

## REFERENCES

- [1] Kaufman E, Leviner E, Galli D, Garfunkl AA. Subcutaneous air emphysema - A rare condition. *J Oral Med.* 1984; 39: 47-50.
- [2] Battrum DE, Gutmann JL. Implications, prevention and management of subcutaneous emphysema during endodontic treatment. *Endod Dent Traumatol.* 1995; 11: 109-14.
- [3] Max J, Trummer, Richard G. Fosburg . Mediastinal emphysema following the use of a high-speed. *Ann Thorac Surg.* 1970; 9: 378-81.
- [4] Gamboa Vidal CA, Vega Pizarro CA, Almeida Arriagada A. Subcutaneous emphysema secondary to dental treatment: Case Report. *Med Oral Patol Oral Cir Bucal.* 2007; 12: E76-8.
- [5] Hayduk S, et al. Subcutaneous emphysema after operative dentistry: report of a case. *J Am Dent Assoc.* 1970; 80: 1362.
- [6] Shoveton DS. Surgical emphysema complications of dental operations. *Br Dent J.* Feb 19, 1957; 102: 25.
- [7] Sumita M, Suzuki S, Fujii K. Three cases of accidental occurrence of the facial subcutaneous emphysema following root canal treatment. *Aichi Gakuin Daigaku Shigakkaishi.* 1970; 8(2): 106-12.
- [8] Walker JE. Emphysema of soft tissues complicating endodontic treatment using hydrogen peroxide: a case report. *Br J Oral Surg.* 1975; 13(1): 98-99.
- [9] Vasileva M. Face and neck subcutaneous emphysema in root canal therapy]. *Stomatologia (Sofia).* 1977; 59(2): 119-21.
- [10] Kaufman AY. Facial emphysema caused by hydrogen peroxide irrigation: report of a case. *J Endod.* 1981; 7(10): 470-72.
- [11] Hirschmann PN, Walker RT. Facial emphysema during endodontic treatment - two case reports. *Int Endod J.* 1983; 16(3): 130-32.
- [12] Falomo OO. Surgical emphysema following root canal therapy. Report of a case. *Oral Surg Oral Med Oral Pathol.* 1984; 58(1): 101-2.
- [13] Bottinelli G, Arrigoni C, Flecchia G. Description of a case of subcutaneous emphysema as a consequence of endodontic treatment. *Ann Osp Maria Vittoria Torino.* 1986; 29(1-6): 43-9.
- [14] Nahlieli O, Neder A. Iatrogenic pneumomediastinum after endodontic therapy. *Oral Surg Oral Med Oral Pathol.* 1991; 71(5): 618-9.
- [15] Wright KJ, Derkson GD, Riding KH. Tissue-space emphysema, tissue necrosis, and infection following use of compressed air during pulp therapy: case report. *Pediatr Dent.* 1991; 13(2): 110-3.
- [16] Penna KJ, Neshat K. Cervicofacial subcutaneous emphysema after lower root canal therapy. *N Y State Dent J.* 2001; 67(5): 28-29.
- [17] Smatt Y, Browaeys H, Genay A, Raoul G, Ferri J. Iatrogenic pneumomediastinum and facial emphysema after endodontic treatment. *Br J Oral Maxillofac Surg.* 2004; 42(2): 160-62.
- [18] Sujeet K, Shankar S. Images in clinical medicine. Prevertebral emphysema after a dental procedure. *N Engl J Med.* 2007; 356(2): 173.
- [19] de Sermeño RF, da Silva LA, Herrera H, Herrera H, Silva RA, Leonardo MR. Tissue damage after sodium hypochlorite extrusion during root canal treatment. *Oral Surg Oral Med Oral Pathol Oral Radiol Endod.* 2009; 108(1): e46-9.
- [20] Parkar A, Medhurst C, Irbash M, Philpott C. Periorbital oedema and surgical emphysema, an unusual complication of a dental procedure: a case report. *Cases J.* 2009; 2: 8108.
- [21] Kim Y, Kim MR, Kim SJ. Iatrogenic pneumomediastinum with extensive subcutaneous emphysema after endodontic treatment: report of 2 cases. *Oral Surg Oral Med Oral Pathol Oral Radiol Endod.* 2010; 109(2).
- [22] Coulier J, Deprez FC. Iatrogenic Facial subcutaneous emphysema after endodontic treatment. *JBR-BTR.* 2011; 94(1): 38.
- [23] Uyanik LO, Aydin M, Buhara O, Ayali A, Kalender A. Periorbital emphysema during dental treatment: a case report. *Oral Surg Oral Med Oral Pathol Oral Radiol Endod.* 2011; 112(6): e94-6.
- [24] Hsu HL, Chang CC, Liu KL. Subcutaneous emphysema after dental procedure. *QJM.* 2011; 104(6): 545.
- [25] Durukan P, Salt O, Ozkan S, Durukan B. Cervicofacial emphysema and pneumomediastinum after a high-speed air drill endodontic treatment procedure. *Am J Emerg Med.* 2012; 30(9): 2095.
- [26] Mather J Andrew, Stoykewych A Andrew. Cervicofacial and Mediastinal emphysema complicating a dental procedure. *J Can Dent Assoc.* 2006; 72(6): 565-6.8.
- [27] Frühauf J, Weinke R, Pilger U, Kerl H, Müllegger RR Soft tissue cervicofacial emphysema after dental treatment: report of 2 cases with emphasis on the differential diagnosis of angioedema. *Arch Dermatol.* 2005; 141(11): 1437-40.
- [28] Hülsmann, Hahn. Complications during canal irrigation. *International Endodontic Journal.* 2000; 33: 186-93.
- [29] Paul D. Eleazer, Kristen R. Eleazer. Air pressures developed beyond the apex from drying root canals with pressurized air. *Journal of Endodontics.* 1998; 24, (12): 833-36.
- [30] Bradford CE, Eleazer PD, Downs KE, Scheetz JP. Apical pressures developed by needles for canal irrigation. *J Endod.* 2002; 28(4): 333-35.
- [31] John I. Ingle, Bakland Leif K. *Endodontics.* 6<sup>th</sup> ed; University of Michigan, William and Willking. 1994; 8: 215-34.

### PARTICULARS OF CONTRIBUTORS:

1. Assistant Professor, Department of Conservative Dentistry & Endodontics, Institute of Dental Sciences, S'O' A University, Bhubaneswar, Odisha, India.
2. Assistant Professor, Department of Oral & Maxillofacial Surgery, Hitech Dental College, Bhubaneswar, Odisha, India.
3. Associate Professor, Department of Oral & Maxillofacial Surgery, Hitech Dental College, Bhubaneswar, Odisha, India.
4. Assistant Professor, Department of Prosthodontics, College of Dental Sciences and Hospital, Indore, India.
5. Associate Professor, Department of Oral Medicine and Radiology, Institute of Dental Sciences, S'O' A University, Bhubaneswar, Odisha, India.

### NAME, ADDRESS, E-MAIL ID OF THE CORRESPONDING AUTHOR:

Dr. Lora Mishra,  
Assistant Professor, Department of Conservative Dentistry & Endodontics, Institute of Dental Sciences.  
K-8, Ghatikia, Bhubaneswar, Odisha-751003, India.  
Phone: +918895266363, E-mail: loraprankster@yahoo.co.in; misspranky@gmail.com

### FINANCIAL OR OTHER COMPETING INTERESTS: None

Date of Submission: **Jul 10, 2013**  
Date of Peer Review: **Oct 10, 2013**  
Date of Acceptance: **Oct 28, 2013**  
Date of Publishing: **Jan 12, 2014**