

Epithelial Cyst of the Spleen with Squamous Metaplasia: A Rare Entity

VISSA SHANTHI¹, VENGALA CHIDANANDA REDDY², NANDAM MOHAN RAO³, BHAVANA GRANDHI⁴, SUNEETHA KONA⁵

ABSTRACT

Epithelial splenic cysts are uncommon lesions which occur the spleen. The aetiopathogenesis of these cysts is not clear. We are reporting a case of an epithelial cyst which occurred in the spleen in a 40-year-old female, which was multi loculated and which had flattened lining epithelium. Some foci showed squamous metaplasia.

Keywords: Spleen, Epithelial cyst

INTRODUCTION

Splenic epithelial cysts are a rare entity, which is usually asymptomatic and is detected incidentally during use of imaging techniques. Large cysts may produce pressure symptoms and pose complications of splenic rupture, leading to intra-abdominal bleeding, which can be life threatening. Treatment of choice during such complications is splenectomy [1].

CASE REPORT

A 40-years-old female was admitted with left upper quadrant discomfort of 5-months duration and pain in abdomen of 3 months duration. A history of bloating, which was often accompanied by feeling of fullness on eating even a small meal, was reported. There was no history of trauma or surgical interventions which were done in the past. Abdominal examination revealed mild tenderness in left hypochondriac region and splenomegaly, with a palpable splenic notch. Other blood investigations were normal.

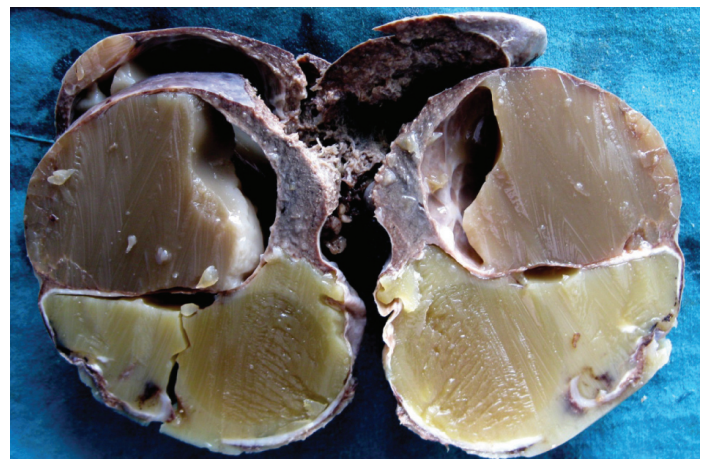Ultrasound of the abdomen showed an enlarged spleen which measured 13x10x6cm, with well-defined homogenous non enhancing lesions in the superior and inferior poles of the spleen, which measured 6x6cm each. The enlarged spleen compressed the greater curvature of stomach. There was no evidence of cysts in kidney, liver or any other major organs. Splenectomy was done and specimen was sent for a histopathological examination

MORPHOLOGY

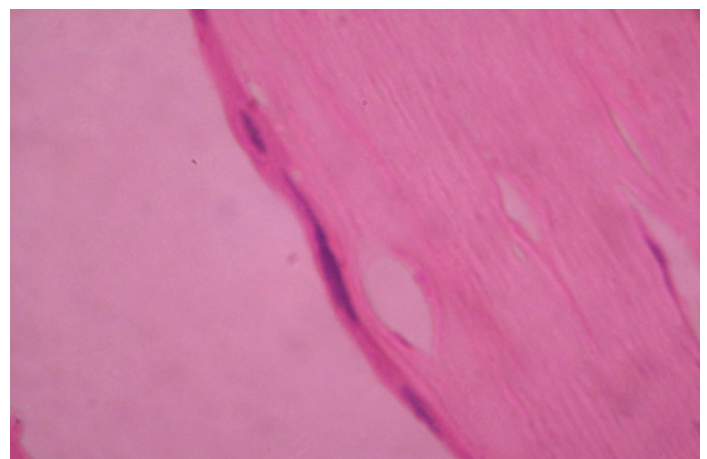
Gross: We received a splenectomy specimen which measured 12x9x6cm. Cut section showed two cysts which were filled with grey white, thick, mucinous material. Each cyst measured 6x5cms [Table/Fig-1]. Microscopically, the cyst wall showed flattened lining epithelium [Table/Fig-2]. In some foci, squamous epithelium [Table/Fig-3] and hob nail cells were noted. Adjacent to cyst wall, normal splenic parenchyma with congested sinusoids and lymphoid follicles was noted and they were diagnosed as an epithelial splenic cyst.

DISCUSSION

Splenic cysts are rare, with an incidence of 0.07%. Fowler, after an extensive review of world literature, proposed first pathological classification in 1953 [2]. This was thought of as a complex method and later, Martins proposed a simpler and a more practical clinical version, which became popular [3]. Cysts may be parasitic (75%)

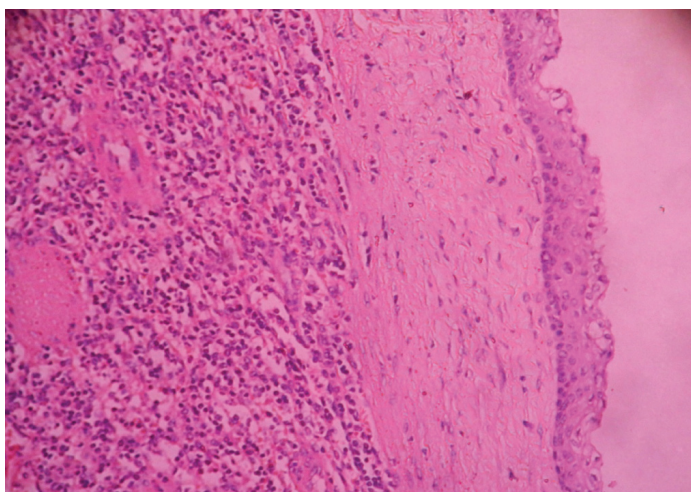


[Table/Fig-1]: Multiloculated splenic cyst filled with mucinous material



[Table/Fig-2]: Splenic Cyst wall with flattened lining epithelium (H&E,X400)

or non parasitic. Non parasitic cysts are divided into primary or true cysts and secondary or false cysts, depending on presence or absence of cellular lining of the cyst wall [4]. Regarding the histogenesis of the epithelial splenic cysts, Burrig [5] and Ough et al., [6] reported that these cysts originated from invagination of capsular peritoneal mesothelium or collection of peritoneal mesothelial cells which were trapped in splenic sulci, as were also congenital



[Table/Fig-3]: Splenic Cyst wall with squamous lining epithelium (H&E,X400)

cysts. Congenital cysts which arose from normal lymph spaces in the spleen have also been also postulated [7]. The mesothelium subsequently undergoes squamous metaplasia, which probably occurs secondarily to chronic irritation.

Spontaneous intra-splenic bleeding or collection of fluid after an injury, results in epithelial cyst of spleen. Presence of haemosiderin in cyst fluid and wall supports the bleeding hypothesis. Bleeding from ectatic veins in the wall, which causes causing initial cyst formation and further enlargement due to osmotic effect of the retaining fluid, has also been proposed [8]. Immature metaplasia in the lining epithelium expresses intermediate filaments (keratin and cam 5.2) and surface epithelial marker (CEA) is expressed weakly [9].

Squamous epithelium of epidermoid splenic cyst, either of teratomatous derivation or which arises from foetal epithelial inclusion is supported by a similar CK profile, as is expressed by an ovarian mature teratoma [10]. Parasitic lesions of Echinococcus, intrasplenic pancreatic pseudocysts, pseudocysts from splenic trauma can also present as cystic lesions of spleen. Infection, infarction, pyogenic abscess, metastatic diseases and cystic lymphangioma or haemangioma can also present as cystic lesions of spleen.

Making a histological distinction between epidermoids and mesothelial cysts may be difficult, but they can be differentiated on the basis of immunohistochemistry. Epidermoid cysts are positive for CEA, CA 19-9 and cytokeratin, but they are negative for calretinin, whereas mesothelial cysts are positive for cytokeratin and calretinin, but negative for CEA and CA 19-9. Occasionally, lining epithelium of the typical cyst can be mistaken for endothelium, leading to a false diagnosis of lymphangioma or haemangioma. In the typical true splenic cysts, the lining epithelium is positive for keratins (epithelium) and negative for factor VIII (endothelium).

Primary splenic cysts are encountered more commonly in children and young adults [11].

Few familial cases have been reported in the literature [12]. Among adults, it is more common in second and third decades of life, with a female preponderance. The clinical manifestation of splenic cysts is non-specific. Small cysts are usually asymptomatic. An asymptomatic painless abdominal mass is the presenting feature in 30-45% of cases. Other symptoms are, pressure exerted by the

cysts on other organs such as the stomach (reflux oesophagitis), the kidney or left renal artery (hydronephrosis, hypertension), the diaphragm (coughing and pain in the left shoulder) or the heart (arrhythmias).

Laboratory studies may show elevated levels of tumour markers, carcinoembryonic antigen (CEA) and CA 19-9. Ultrasonography shows that the cysts are either anechoic or hypoechoic. Infection, intracystic haemorrhage, rupture, either spontaneous or traumatic, leading to haemoperitoneum and peritonitis, are complications of epithelial cysts.

Histology of epidermoid cysts shows squamous epithelium and thick collagenous walls with inter connecting bridges. Presence of a thick trabeculated fibrous band which is covered by epithelium is seen in the interior cyst wall. Cholesterol crystals, breakdown products of haemorrhages or protein particles are seen in cyst fluid.

Treatment depends on the size of the splenic cyst. Non parasitic cysts which are larger than 5 cm are susceptible to haemorrhage, rupture, and infection. Therefore, a surgical treatment is recommended for symptomatic, large (more than 5cm), or complicated cysts [13]. The options of treatment are percutaneous aspiration or sclerosis. Partial splenectomy, total cystectomy, marsupialization or cyst decapsulation (unroofing), colposcopic puncture and creation of a cyst peritoneal window, are the various conservative surgeries which are available. If the cyst is very large and if there are multiple cysts, a complete splenectomy should be performed.

CONCLUSION

For the abdominal masses which occur in young individuals, splenic epithelial cysts should be considered as one option of the differential diagnosis. Splenic cysts increase the risk of splenic rupture in conditions like blunt abdominal injuries and increased intraabdominal pressure. In cases where there is adequate splenic parenchyma, an attempt to preserve the spleen should be done, whereas splenectomy is recommended when there is splenic rupture with intraabdominal haemorrhage.

REFERENCES

- [1] G Fragandreas, S Papadopoulos, I Gerogiannis, C Spyridis, D Tsantilas, I Venizelos, et al. Epithelial splenic cysts and life-threatening splenic rupture. *Chirurgia*. 2011;106:519-22
- [2] Fowler RH. Non parasitic benign cystic tumors of the spleen. *Int Abstr Surg*. 1953;96:209-27.
- [3] Martin JW. Congenital splenic cysts. *Am J Surg*. 1958;96:302-7
- [4] Williams RJ, Glazer G. Splenic cysts: changes in diagnosis, treatment and etiological concepts. *Ann R Coll Surg Engl*. 1993;75:87-89.
- [5] Burring KF. Epithelial (true) Splenic cysts. Pathogenesis of the mesothelial and so called epidermoid cyst of the spleen. *An I Surg Pathol*. 1988;12:275-81.
- [6] Ough YD, Nash HR, Wood DA. Mesothelial cysts of the spleen with squamous Metaplasia. *Am J Clin Pathol*. 1981;76:666-69.
- [7] Robbins FG. Splenic epidermoid cysts. *Ann Surg*. 1978;187:231-35.
- [8] Touloukian RJ, Maharaj A, Ghoussoub R, Reyes M. Partial decapsulation of splenic epithelial cysts: Studies anetiology and outcome. *J Pediatr Surg*. 1997;32:272-74.
- [9] Lee YS, The M. Histogenesis of true splenic cysts: a histological and immunohistochemical study. *Ann Acad Med Singapore*. 1993;22:372-76.
- [10] Lifschitz-Mercer B, Open M, Kushnir I, Czernobilsky B. Epidermoid cyst of the spleen: a cytokeratin profile with comparison to other squamous epithelia. *Virchows Archiv*. 1994;424:213-16.
- [11] Younger KA, Hall CM. Epidermoid cyst of the spleen: A case report and review of literature. *Br J Radiol*. 1990;63: 652-53.
- [12] Singletary H Patrick R. Familial splenic epidermoid cyst. *AJR*. 1990;155: 1233-34.
- [13] Hansen MB, Moller AC. Splenic cysts. Surgical Laparoscopy, *Endoscopy and Percutaneous Techniques*. 2004; 14(6):316-22.

PARTICULARS OF CONTRIBUTORS:

1. Associate Professor, Department of Pathology, Dr. NTR University of Health Sciences Vijayawada, Andhra Pradesh, India.
2. Assistant Professor, Department of Pathology, Dr. NTR University of Health Sciences Vijayawada, Andhra Pradesh, India.
3. Associate Professor, Department of Pathology, Dr. NTR University of Health Sciences Vijayawada, Andhra Pradesh, India.
4. Assistant Professor, Department of Pathology, Dr. NTR University of Health Sciences Vijayawada, Andhra Pradesh, India.
5. Assistant Professor, Department of Pathology, Dr. NTR University of Health Sciences, Vijayawada, Andhra Pradesh, India.

NAME, ADDRESS, E-MAIL ID OF THE CORRESPONDING AUTHOR:

Dr. V. Shanthi,
Flat No. 301, Anjani SVGK Towers, Sri Hari Nagar, Ramalingapuram, Nellore, Andhra Pradesh, India.
Phone: 91-9849052179, E-mail: santhijp@gmail.com

FINANCIAL OR OTHER COMPETING INTERESTS: None.

Date of Submission: Oct 03, 2013

Date of Peer Review: Feb 01, 2014

Date of Acceptance: Feb 02, 2014

Date of Publishing: Apr 15, 2014