

An Unusual Branch of Celiac Trunk Feeding Suprarenal Gland - A Case Report

MUNMUN SARKAR¹, PRANAB MUKHERJEE², HIRONMOY ROY³, SANDIP KUMAR SENGUPTA⁴, AMARENDRA NATH SARKAR⁵

ABSTRACT

During routine dissection, variation in branching pattern of celiac trunk has been observed in adult 54-year-old male cadaver. Instead of normal three branches an additional branch i.e., Left inferior phrenic artery originated from it as fourth branch. Then it divided into two branches, one directly supplied the diaphragm and other branch divided into three sub-branches. First and second branch entered into the left suprarenal gland at its upper and middle pole and third one finally terminated by supplying to the diaphragm. There is no separate middle suprarenal artery on the left side, but inferior suprarenal artery was as usual. No variations have been found on right side in the lateral branches of abdominal aorta. Such a quadrifurcation of celiac trunk to supply suprarenal gland is quiet unique so far searched in literature.

Keywords: Inferior Phrenic artery, Suprarenal Artery

CASE REPORT

During routine dissection of undergraduate abdomen part for the session 2013-14; in a 54-years adult male cadaver, it has been found that the celiac trunk instead of its normal three branches, provided another branch as left inferior phrenic artery [Table/Fig-1].

That artery just after its origin bifurcated [Table/Fig-2]. One branch passed to the diaphragm as left inferior phrenic artery, while the other provided two successive branches at middle part and upper part of left suprarenal gland; and finally terminated by supplying the diaphragm behind the stomach [Table/Fig-2].

The usual left middle suprarenal artery was found absent. On the right side all the above mentioned branches are as usual. Inferior suprarenal artery has been found as a branch of renal artery and following the normal course on both sides.

DISCUSSION

First ventral branch of abdominal aorta is celiac trunk and has a character of its length (1-3 cm) which is lesser than its breath. It has three branches i.e. left gastric artery, Hepatic artery and splenic artery which is supplying derivatives of fore gut [1]. Elongated celiac trunk with variation of its branching pattern has been noted in pertinent literature [2].

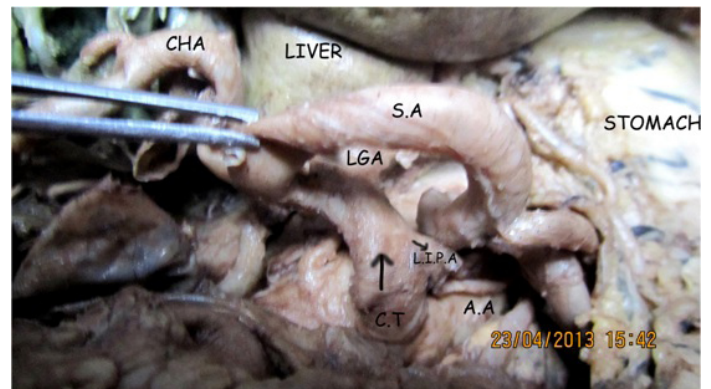
Suprarenal glands are highly vascular and received blood flow of about 5 ml/min. The required demand is supplied by three arteries namely superior, middle and inferior suprarenal arteries. Superior suprarenal artery arises from inferior phrenic artery. Middle suprarenal artery arises from lateral aspect of abdominal aorta at the level of superior mesenteric artery Inferior suprarenal arises from renal artery [3].

In our case the left inferior phrenic artery originated from the celiac trunk and has been noticed as first branch of celiac trunk. Then it divided into two branches. Usual three branches of celiac trunk followed normal branching pattern, i.e. Left gastric artery followed by common hepatic artery and splenic artery as mentioned in literature [4]. There, it has also been reported for a small phrenic branch as fourth branch of celiac trunk.

Inferior phrenic artery of one side or both phrenic arteries as common stem arising from celiac trunk has been reported earlier [5]. A dorsal pancreatic artery has been described as important branch of celiac trunk by previous authors [6]. Inferior phrenic arteries are arising as common trunk from renal artery along with variation or absence

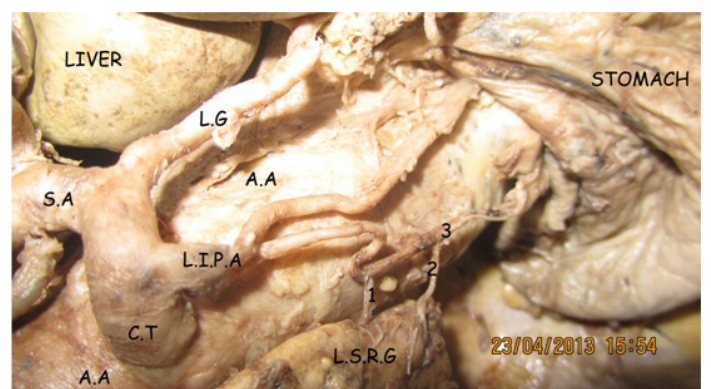
of one of three suprarenal arteries has been reported in pertinent literature [7].

Dutta S et al., has studied a total number of 68 cadavers and reported that in 18% of cases left superior suprarenal artery as a branch of splenic artery or directly from abdominal aorta [7]. He also reported absence of middle suprarenal artery on right side in 29% of cases. A common trunk arising from abdominal aorta at the level of renal artery and trifurcate to supply the right suprarenal gland has been reported by Pai V [8].



[Table/Fig-1]: Showing four branches of celiac trunk.

CHA-common hepatic artery, SA-Splenic artery, LGA-Left gastric artery, L.I.P.A-Left inferior phrenic artery (right turned arrow), C.T-Celiac trunk (upward arrow), A.A-Abdominal aorta



[Table/Fig-2]: Splenic artery and common hepatic artery has been turned into right to show the branching pattern of left inferior phrenic artery and its branches.

1 and 2-Suprarenal branches, 3-Phrenic branch

Dorsal aorta in primitive embryo gives of three sets of branches namely dorsal somatic branches, Lateral visceral branches and ventral splanchnic branches. At first there are multiple serial ventral splanchnic branches develops but only three arteries i.e. celiac trunk, superior mesenteric artery and inferior mesenteric artery persist below the diaphragm. Due to gradual development of kidney through pronephric, mesonephric and metanephric phase and lastly ascent of metanephric kidney to adult lumbar position along with descent of gonads from lower thorax to pelvis or scrotum, most of the lateral visceral branches atrophies and only three suprarenal arteries persist. This happened due to the relatively static position of suprarenal gland. Inferior phrenic artery which developed from superior suprarenal artery and renal artery originates from inferior suprarenal artery.

Later, due to increased blood flow gradient through these newly developed circuit, these channels become prominent and superior suprarenal artery and inferior suprarenal artery seems to be branch of Inferior phrenic artery and renal artery respectively. Furthermore in the region of ventral splanchnic branches, two sets of anastomotic channels (ventral and dorsal) communicate among ventral splanchnic branches and due to growth of embryo along with caudal movement and enlargement of gut, celiac trunk moves caudally from 7th cervical segment to 12th thoracic region. Anastomotic channels mostly atrophied but a ventral anastomotic channel, i.e. left gastric artery persist and become the first branch of celiac trunk. Hepatic and splenic arteries developed from celiac trunk to supply liver, spleen and pancreas which developed in the vicinity. During caudal migration, there is unequal growth of ventral and dorsal wall of Aorta as reported by Arey LB [9]. This unequal growth of walls of aorta helps to fuse different branches like inferior phrenic artery with celiac trunk as happens in this case. Superior and middle suprarenal arteries are connected to the inferior phrenic

arteries by establishment of new communicating channels due to change in gradient in blood flow.

CONCLUSION

Such anomalous origin and supply of suprarenal artery as well as inferior phrenic artery becomes important to not only for surgeons but also in embryological point of view. In case of, severe abdominal vascular occlusions the Inferior phrenic artery can serve as important source of collateral circulation with superior suprarenal artery. Surgical procedure for adrenal gland and specially the modern minimal invasive technique need knowledge of such variations. Radiologist can conclusively diagnose such variant vessels and help surgeon to prevent mortality and morbidity.

REFERENCES

- [1] Borley NR. Abdomen and Pelvis. In: Standring, S. Eds. Gray's Anatomy. 40th Ed. Edinburgh Churchill Livingstone. Elsevier. Reprinted 2010. 1197-1201 and 1072-74.
- [2] Hollinshead WH. Suprarenal artery. In: Anatomy For Surgeons. First Edition Reprint, Tokyo, Harper And Row, 1966; 452-63.
- [3] Eaton, P.B. The Coeliac Axis. *Anatomy*. 1917: 13; 369
- [4] Pick JW, Anson BJ. The Inferior Phrenic Artery: Origin And Suprarenal Branches. *Anatomy*. 1940;78:413
- [5] Michels NA. Blood Supply of The Stomach. *Anat. Rec.* 1952; 112:361
- [6] Topaz O, et al. Origin of A Common Trunk For The Inferior Phrenic Arteries From The Right Renal Artery: A New Anatomic Vascular Variant With Clinical Implications Cardio Vascular Revascularization Medicine. 2010; 57-62.
- [7] Dutta S. Suprarenal Gland – Artery Supply: An Embryological Basis And Applied Importance. *Romanian Journal Of Morphology And Embryology*. 2010; 51: 139-40.
- [8] Pai V. Variation of blood supply of suprarenal gland- a case report. *Anatomica Karnataka*. 2010; 4 (2): 57-60.
- [9] Arey LB. Development Arteries – The Vascular System. In: 'Developmental Anatomy A Text Book And Laboratory Manual of Embryology.' W.B. Saunders Company. Philadelphia And London. 7th Ed, 1966; 350-58.

PARTICULARS OF CONTRIBUTORS:

1. Postgraduate Student, Department of Anatomy, RG Kar Medical College, Kolkata, India.
2. Professor, Department of Anatomy, RG Kar Medical College, Kolkata, India.
3. Assistant Professor, Department of Anatomy, North Bengal Medical College, Darjeeling, India.
4. RMO-cum-Clinical Tutor, Department of Obstetrics and Gynaecology, North Bengal Medical College, Darjeeling, India.
5. Associate Professor and MSVP, Department of General Surgery, North Bengal Medical College, Darjeeling, India.

NAME, ADDRESS, E-MAIL ID OF THE CORRESPONDING AUTHOR:

Dr. Hironmoy Roy,
Assistant Professor, Department of Anatomy,
North Bengal Medical College, P.O. Sushrutanagar, Siliguri-734012, West Bengal, India.
Phone: +91 9748828588, E-mail: hironmoy19@gmail.com

FINANCIAL OR OTHER COMPETING INTERESTS: None.

Date of Submission: **Jan 06, 2014**
Date of Peer Review: **Feb 05, 2014**
Date of Acceptance: **Feb 12, 2014**
Date of Publishing: **Apr 15, 2014**