

To Evaluate the Feasibility of Neurotisation of Facial Nerve Branches with Ipsilateral Masseteric Nerve: An Anatomic Study

RAVI CHANDER RAO ANNAMANENI¹, MUKUNDA REDDY D.², SRIKANTH R.³, SRIDHAR MOTURI⁴, ARPITHA KOMURAVELLY⁵, SRINIVASA RAO SADAM⁶, SHASHI KANTH V.⁷, BHADRA RAO V.⁸

ABSTRACT

Context: Facial palsy is a common problem encountered in clinical practice. These patients suffer serious functional, cosmetic & psychological problems with impaired ability to communicate. Functional problems around the eye are usually a first priority for the patient with facial palsy. The nerve to masseter as a direct nerve transfer to the zygomatic branch of facial nerve to reinnervate viable facial muscles within a year after the onset of paralysis has been scarcely reported. This study was contemplated to evaluate the feasibility of neurotisation of zygomatic branch of facial nerve with masseteric nerve branch of the trigeminal nerve

Objectives: Establishing the anatomic relationship of masseteric nerve to masseteric muscle, determining feasibility of neurotisation of zygomatic branch of facial nerve using the nerve to the masseter and establishing fascicular correlation of the donor and the recipient nerves.

Materials and Methods: Nineteen hemi-faces in ten fresh cadavers (6 Male and 4 Female) were dissected in a forensic morgue and access was by a standard preauricular incision and anterior skin flap is elevated in a subcutaneous plane.

Facial nerve and its two main divisions are dissected in its full A*/extratemporal course. Zygomatic branch dissected upto zygomatic arch and the nerve to the masseter is identified within the masseter muscle, dissected proximodistally to isolate it. Feasibility of transfer of this masseteric nerve to the zygomatic branch without using nerve graft is determined. At the completion of dissection, the ends of both nerves are sent for HPE analysis to determine fascicular anatomy and count.

Results: The dissection of masseteric nerve was done taking into consideration of 3 axes, that is anteroposterior (x), vertical (y) axes and mediolateral (z) for locating the nerve and for standardization of the dissection. The nerve was cut and stored in glutaraldehyde solution and subjected to histopathologic examination after fixing and staining with Haematoxylin-eosin stain. Donor masseteric nerve has 7-10 fascicles. Recipient zygomatic branch has 2-3 fascicles. And the buccal branch has 5-6 fascicles.

Conclusion: The use of the nerve to masseter offers a simpler ipsilateral alternative for neurotisation of the facial nerve branches in patients who have an early facial nerve paralysis.

Keywords: Facial palsy, Masseter nerve, Orbicularis oculi, Nerve grafting

INTRODUCTION

Facial palsy is a common problem encountered in clinical practice. These patients suffer serious functional, cosmetic & psychological problems with impaired ability to communicate [1]. Functional problems around the eye are usually a first priority for the patient with facial palsy [2]. The reduced or missing protections of the vulnerable cornea lead to a continuous need for artificial tears, ointments or occlusion with a wet chamber. Impaired vision, corneal ulceration, conjunctivitis, epiphora and increased sensitivity of the eye to light, wind or sun may impair the quality of everyday life.

A host of procedures have been described to correct the loss of innervations of the orbicularis oculi consequent to facial paralysis. Early on after facial paralysis, procedures utilizing nerve donors to innervate the paralyzed muscle are preferred as they are the most physiological of all methods. These include facial nerve suture or nerve grafting of the facial nerve; and if the ipsilateral proximal facial nerve is not available, extra-facial motor nerves that can permit the innervations of the target muscles are used. Nerve surgery is indicated when the main trunk of the facial nerve is damaged or unavailable but the distal nerve branches and facial muscles remain viable. These techniques are best suited to cases of facial paralysis less than 1 year in duration.

In facial nerve paralysis that one encounters in common clinical practice, the proximal facial nerve is not available for neurotisation; hence the "cross facial nerve grafting" method is the gold standard

[3]. The advantages are in using a donor that mimics the normal facial nerve without causing any morbidity on the donor side of the face; the disadvantages are longer duration for recovery associated with the use of sural nerve grafts, synkinesia- if multiple recipient branches are neurotised with a single branch of the contra lateral facial nerve, and in most cases the operation is two-staged.

Among the extra-facial nerves, the hypoglossal nerve has been most commonly used [4]. Though return of facial muscle function is good after this transfer, there is facial synkinesia and substantial morbidity on account of hemi lingual atrophy [5]. The spinal branch of cranial nerve XI has also fallen into disfavor because of the significant donor morbidity [6].

All said and done, most of the studies have concentrated on the function of the orbicularis muscle to get a symmetric smile; methods to achieve eye closure use passive methods like the gold weight or palpebral spring or unphysiological dynamic methods such as transfer of the temporalis muscle [7].

Akin to the upper limb where target neurotisation has successfully supplanted tendon transfers in irreparable nerve injuries, nerve transfers are feasible in innervations of the paralyzed voluntary muscle in other regions of the body.

The nerve to masseter has been used successfully for reinnervation of microvascular functioning muscle transfers for facial reanimation in established facial palsy [8]. However, its use as a direct nerve transfer to the zygomatic branch of facial nerve to reinnervate

viable facial muscles within a year after the onset of paralysis has been scarcely reported.

This study was contemplated to evaluate the feasibility of neurotisation of zygomatic branch of facial nerve with masseteric nerve branch of the trigeminal nerve. The permanent difficulties with speech and swallowing associated with more traditional nerve transfers are also avoided utilizing this technique.

MATERIALS AND METHODS

In this study, 19 hemi-faces in 10 fresh cadavers (6 Males and 4 Females) were dissected in a forensic morgue

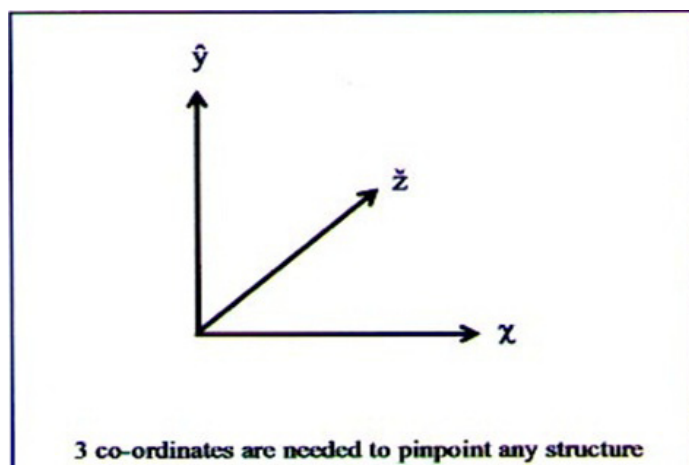
- Access was by a standard preauricular incision with neck extension just below the line of the jaw in a convenient neck crease.
- Anterior skin flap is elevated in a subcutaneous plane forward up to an imaginary vertical line dropped at the lateral canthus of the eye.
- Facial trunk identified by one of the following methods-
 - a. Looking for the “tragal pointer” –the facial nerve is on a deeper plane inferior to the tragal cartilage, or
 - b. It is identified by retrograde dissection of the terminal branches anterior to the parotid fascia.
- Facial nerve and its two main divisions are dissected in its full extratemporal course.
- Zygomatic branch dissected upto zygomatic arch
- The nerve to the masseter is identified within the masseter muscle, dissected proximodistally to isolate it.
- Feasibility of transfer of this masseteric nerve to the zygomatic branch without using nerve graft is determined.
- At the completion of dissection, the ends of both nerves are sent for HPE analysis to determine fascicular anatomy and count.

RESULTS

Nineteen hemi-faces were dissected in 10 cadavers (1 hemi-face was decomposed and not dissectable). Three co-ordinates are needed to pinpoint a structure in the 3 dimensions of space; hence the dissection of masseteric nerve was done taking into consideration of 3 axes, that is anteroposterior (x), vertical (y) axes and mediolateral (z) for locating the nerve and for standardization of the dissection [Table/Fig-1].

Anteroposterior plane (x)

The dissection is done along a vertical line dropped in the center of the anterior and posterior borders of the masseter muscle; this approximates to the vertical line drawn from outer canthus of eye in front and posterior border of the ascending ramus of the mandible behind [Table/Fig-2].



[Table/Fig-1]: Axis

Vertical plane (y)

It is easier to dissect for the nerve at the junction of the upper 1/3rd and middle 1/3rd of the muscle that is the upper third of the area between the lower border of the mandible below to the Zygomatic arch above border; the nerve is thicker in this area risk of damage to the buccal and the zygomatic branches of the facial nerve and the parotid duct is minimal [Table/Fig-3].

Mediolateral plane (z)

The thickness of the masseter plane has 3 distinct layers; the nerve enters the masseter muscle between the intermediate and posterior layers; while dissecting through the inter muscular course there is a plane of tendinous tissue in the intermediate layer, deep to which the nerve can be identified [Table/Fig-4].

Lengths of masseteric nerve available for transfer to the zygomatic branch of facial nerve [Table/Fig-5].

After dissecting the intramuscular course of the nerve, measurements were taken from the point of the masseter nerve where the first branch is given off proximally to the distal end before arborisation into tertiary muscular branches [Table/Fig-6,7].

Direct coaptation

The zygomatic branch is divided as its origin from the temporozygomatic division of facial nerve and sutured to the donor masseter nerve.

In all the 19 hemi faces dissected, is of sufficient length of the donor masseteric nerve was available to allow direct end to end coaptation with the zygomatic branch of the facial nerve [Table/Fig-8,9].

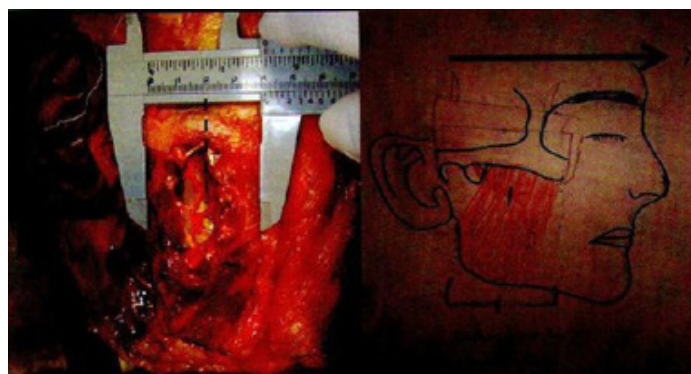
Fascicular count

The nerve was cut and stored in glutaraldehyde solution and subjected to histopathologic examination under 40x and 200x magnification after fixing and staining with Haematoxylin-eosin stain [Table/Fig-10-12].

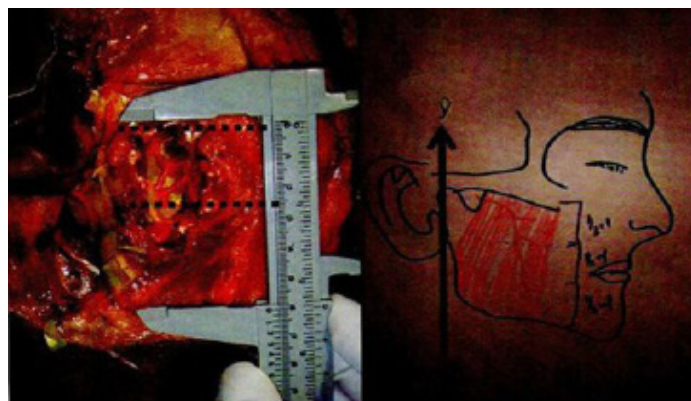
On an Average

Donor masseter nerve has 7-10 fascicles

Recipient zygomatic branch has 2-3 fascicles



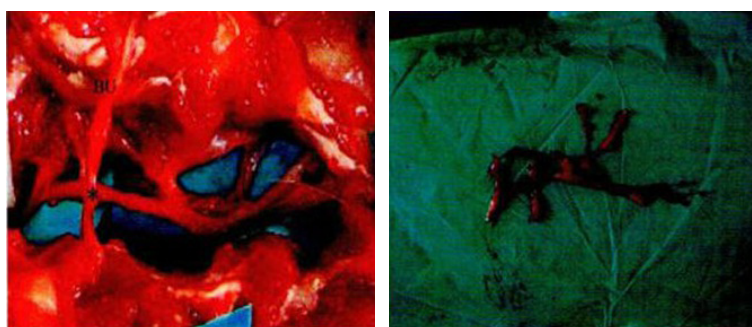
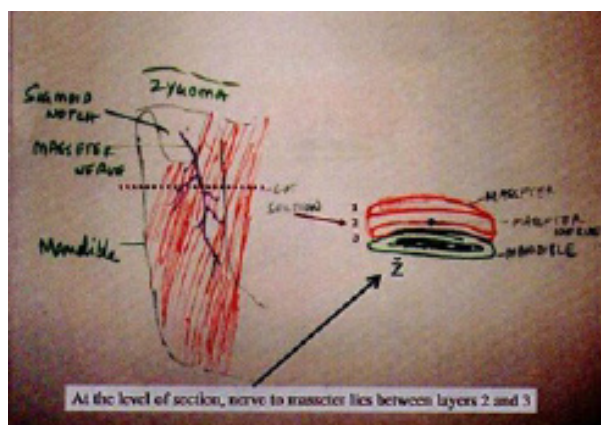
[Table/Fig-2]: Anteroposterior plane



[Table/Fig-3]: Vertical dimensions

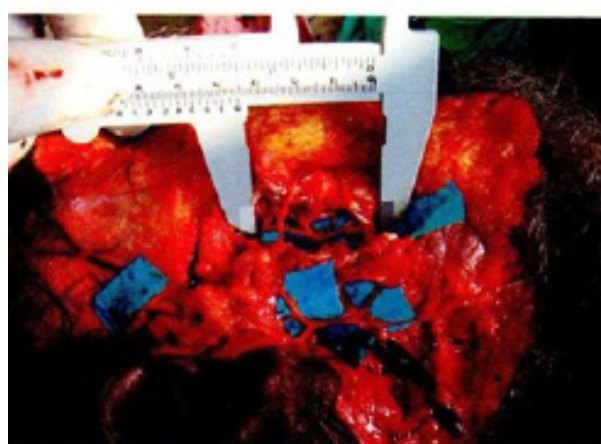
SIDE	Case 1	Case 2	Case 3	Case 4	Case 5	Case 6	Case 7	Case 8	Case 9	Case 10
Right	3.1	3.8	2.9	3.7	3.8	3.3	2.9	3.4	3.7	3.6
Left	3.2	3.8	3.1	3.7	3.8	3.3	Not done	3.4	3.5	3.6

[Table/Fig-4]: Length of masseteric nerve available for transfer

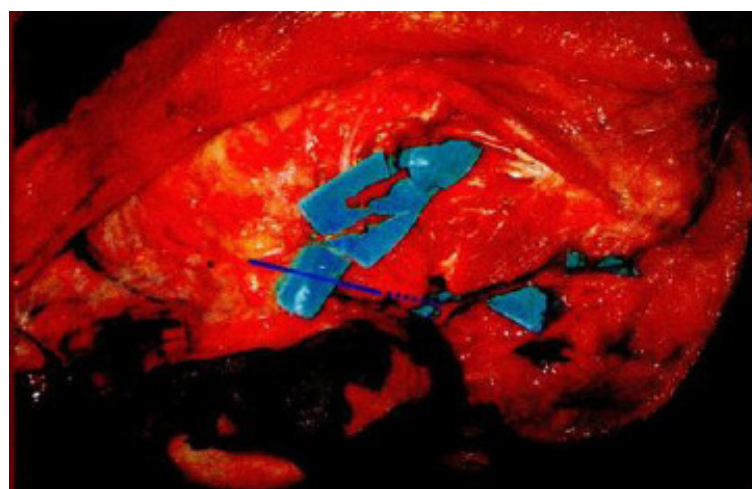


[Table/Fig-7]: Masseteric nerve complete dissection

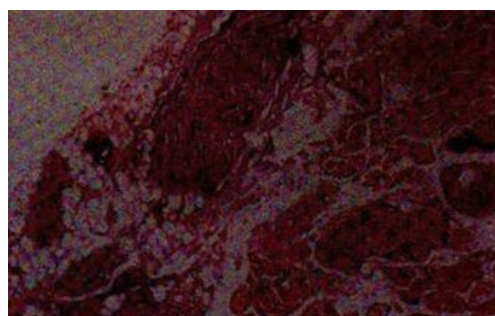
[Table/Fig-8]: Direct coaptation



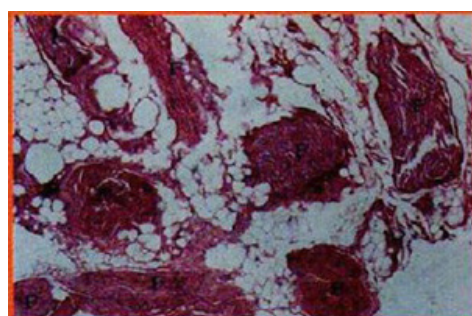
[Table/Fig-5,6]: Medio lateral plane and Length of masseteric nerve



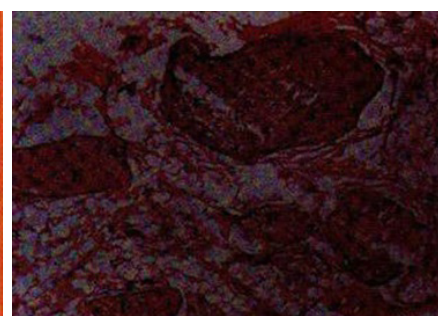
[Table/Fig-9]: Direct coaptation



[Table/Fig-10]: Histopathological examination of Masseteric nerve



[Table/Fig-11]: Histopathological examination of Buccal nerve



[Table/Fig-12]: Histopathological examination of Zygomatic branch of Facial nerve

Fascicular count of masseter nerve is double that of zygomatic nerve which results in more axonal input thus overcoming the problem of axonal drop out of the traditional cross facial nerve grafting procedure. An incidental finding in the study was that the buccal branch has 5-6 fascicles.

DISCUSSION

The nerve to masseter has been used very successfully for reinnervation of microvascular functioning muscle transfers for facial reanimation in established facial palsy but its use as a direct nerve transfer to the zygomatic branch of facial nerve to reinnervate orbicularis oculi has been scarce.

In the dissection of the 19 hemi-faces, masseteric nerve was found to be consistent in its location and branching. It was found to enter the muscle between the intermediate and deep layers of the masseter muscle as stated by Fournier. The best chance of

finding the nerve was to dissect in the upper-third of the muscle in the vertical plane and the middle of the muscle in anteroposterior plane.

Thorir Audolfsson et al., studied 15 cadavers regarding feasibility of neurotisation of masseter nerve to buccal branch of facial nerve for facial transplant and found nerve transfers are a technically feasible option that could theoretically be used in face transplantation either as a primary nerve reconstruction when there are no available healthy nerves, or as a secondary procedure for enhancement of functional outcomes [8].

Klebuc et al., studied 10 cases and found the masseter-to-facial nerve transfer is an effective method for reanimation of the midface and perioral region in a select group of facial paralysis patients. The technique is advocated for its limited donor-site morbidity, avoidance of interposition nerve grafts, and potential for cerebral adaptation, producing a strong, potentially effortless smile [9].

CJ Coombs et al., studied the axonal counts of the nerve to masseter and found on an average, 1542 ± 291.70 (SD) axons [10]. Historical data have also shown that the buccal branch of the facial nerve has 834 ± 285 (SD) whereas the distal end of a cross-facial nerve graft has 100 to 200 axons only. Though we did not perform an axonal count, we studied the fascicular structure and found that the masseter has 8-10 fascicles, the zygomatic branch has about 2-3 fascicles and buccal branch 5-8 fascicles. This confirms that the nerve to the masseter gives more fascicular axonal input for neurotisation of zygomatic or the buccal branch of facial nerve.

Escat (1925 cited by Brenner et al.,) who measured the distance between the sigmoid notch and entrance to the masseter, finding the average length to be 32 mm [11], sufficient to allow tension-free neurotisation. Brenner found that in 27 of 35 (75%) cases studied, the nerve consisted of two or more branches at the level of the mandibular notch and in 35 of 36 (97%) specimens, multiple branches innervated the masseter at the level of the muscle entrance; the study concluded that it was possible to retain some masseter function after the nerve transfer and even complete denervation did occur the temporals could take over the lost function.

In Brenner's study transfers was being done to the facial nerve trunk and the problem of synkinesia would remain. It concentrated on the possibility of selective neurotisation to avoid synkinesia and preserve maximal masseter function in the process. Masseter function can be preserved with intramuscular harvest of the nerve to masseter between the deep and middle planes of the masseter muscle [12]. In our study, the average length of the nerve available after giving off a branch to the muscle in the intramuscular course was 3.5cms. This was adequate for the tension free neurotisation to the zygomatic branch of facial nerve without an interposition nerve graft.

Thus the masseter nerve has the characteristics which make it a viable option for direct neurotisation of the zygomatic branch of facial nerve; using two different cranial nerves (the masseter nerve, and a cross facial nerve graft) for zygomatic and the buccal branch of facial nerve may overcome synkinesia.

CONCLUSION

The use of the motor nerve to masseter offers a simpler ipsilateral alternative for neurotisation of the facial nerve branches in patients who have an early facial nerve paralysis.

Transfer of the masseteric nerve to the zygomatic branch provides an abundant supply of axons, overcoming the problem of axonal drop-off of cross face nerve grafts, thus providing powerful reinnervation of the all important orbicularis muscle.

The advantages of this technique include ease of dissection, constant and reliable anatomy, powerful reinnervation of the facial muscles, and no donor site morbidity, especially when a few branches are left intact to innervate the masseter.

REFERENCES

- [1] Manktelow RT, Tomat LR, Zuker RM, et al. Smile reconstruction in adults with free muscle transfer innervated by the masseter motor nerve: effectiveness and cerebral adaptation. *PlastReconstrSurg.* 2006; 118:885e99
- [2] ManfredFrey, MD PietroGiovannoli, Chieh Han John, 'Dynamic reconstruction of eye closure by muscle transposition or functioning muscle transplantation in facial palsy' *PlastReconstrSurg.* 2004; 114:865
- [3] Haril I, Asato H, yoshimura k, sugawara Y, One stage transfer of helattisimusdorsori muscle for reanimation of a paralysed face: A new alternative. *Plast Reconstr Surg.* 1998;102:941
- [4] Ozsoy V, Hizay A, Demirel BM, Ozsoy O, BilmenS, Turham, et al. The hypoglossal-facial nerve repair as a method to improve recovery of motor function after facial nerve injury. *Ann Anat.* 2011;193:304-18.
- [5] Fournier HD, Denis F, Papon X, et al. An anatomic study of the motor distribution of the mandibular nerve for a masseteric-facial anastomosis to restore facial function. *Surgradiol Anat.* 1997;19:241-4
- [6] Hirsh LF, Murtagh F. Spinofacial anastomosis. *ActaNeurochir.* 1978;40:285e97
- [7] Terzis JK, Konofaos P. 'Nerve transfers in facial palsy': *Facial Plast Surg.* 2008; 24(2):177-93.
- [8] Thorir Audolfsson, Andrés Rodríguez-Lorenzo, Corrine Wong, et al. Nerve transfers for facial transplantation: A cadaveric study for motor and sensory restoration. *PlastReconstrSurg.* 2013; 131(6):1231-40.
- [9] Klebuc, Michael JA. Facial Reanimation Using the Masseter-to-Facial Nerve Transfer. *PlastReconstrSurg.* 2011; 127(5):1909-15.
- [10] Coombs cj et.al. masseteric facial nerve coaptation – an alternative for facial nerve reinneravation, *J PlastReconstr Aestheticsurg.* 2008; 5:46
- [11] Brenner E, Schoeller 'Masseteric nerve: A possible donor for facial nerve anastomosis?' *Clin Anat.* 1998; 11(6):396-400.
- [12] Bermudez LF, Nieto LE. Masseter-facial nerve anastomosis: Case report *J Reconstr Microsurg.* 2004;20:25-30.

PARTICULARS OF CONTRIBUTORS:

1. Consultant, Department of Plastic Surgery, Care Hospitals, Hyderabad, A.P., India.
2. Professor and HOD, Department of Plastic Surgery, Nizams Institute of Medical Sciences, Hyderabad, A.P., India.
3. Professor, Department of Plastic Surgery, Nizams Institute of Medical Sciences, Hyderabad, A.P., India.
4. Associate Professor, Department of Conservative Dentistry and Endodontics, Rungta College of Dental Sciences and Research, Bhillai, Chhattisgarh, India.
5. Senior Resident, Department of General Surgery, Prathima Institute of Medical Sciences, Karimnagar, A.P., India.
6. Associate Professor, Department of Oral and Maxillofacial Surgery, Army College of Dental Sciences, Secunderabad, A.P., India.
7. Reader, Department of Oral and Maxillofacial Surgery, Dental College and Hospital: Azamgarh, U.P., India.
8. Professor, Department of Conservative Dentistry and Endodontics, Maitri Dental College and Research Center, Durg, Chhattisgarh, India.

NAME, ADDRESS, E-MAIL ID OF THE CORRESPONDING AUTHOR:

Dr. Sridhar Moturi,
3-4-504, Fortune park Avenue Apts, Flat no. 203, Barkathpura, Hyderabad-50002, Andhra Pradesh, India.
Phone: +91 9346696296, E-mail: sridhar.moturi@gmail.com

FINANCIAL OR OTHER COMPETING INTERESTS: None.

Date of Submission: **Sept 21, 2013**

Date of Peer Review: **Dec 03, 2013**

Date of Acceptance: **Feb 15, 2014**

Date of Publishing: **Apr 15, 2014**