

# Traumatic Spigelian Hernia: A Rare Clinical Scenario

ARAVINDA P.S.<sup>1</sup>, SUDIPTA SAHA<sup>2</sup>, GYAN SAURABH<sup>3</sup>, MANOJ ANDLEY<sup>4</sup>, ASHOK KUMAR<sup>5</sup>

## ABSTRACT

Traumatic Spigelian hernia is a rare clinical entity with variable clinical presentation and requires a high index of suspicion for prompt diagnosis and the management. Delay in the diagnosis can lead to incarceration or strangulation of bowel loops and subsequent morbidity.

Here, we are reporting a case of traumatic Spigelian hernia followed by blunt trauma to the right lower abdomen. The herniated bowel loop was gangrenous and perforated. There was spillage of fecal matter into the adjoining parietal layer. Patient underwent exploratory laparotomy with resection of gangrenous bowel loop and ileostomy was performed. Post-operative course was uneventful.

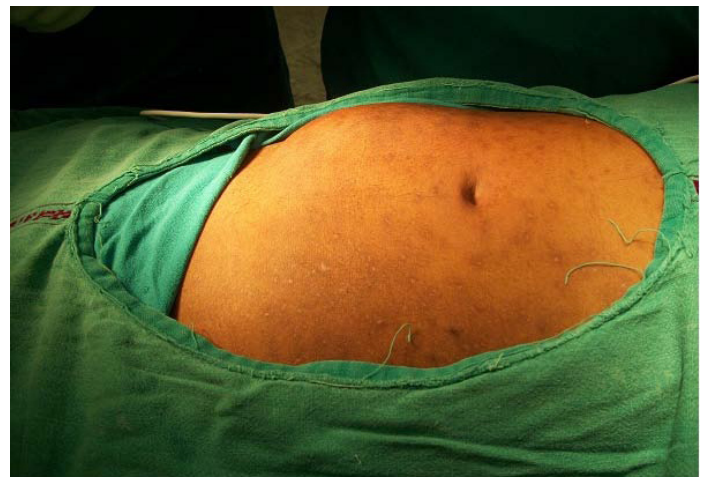**Keywords:** Traumatic, Spigelian hernia, Abdominal wall hernia

## INTRODUCTION

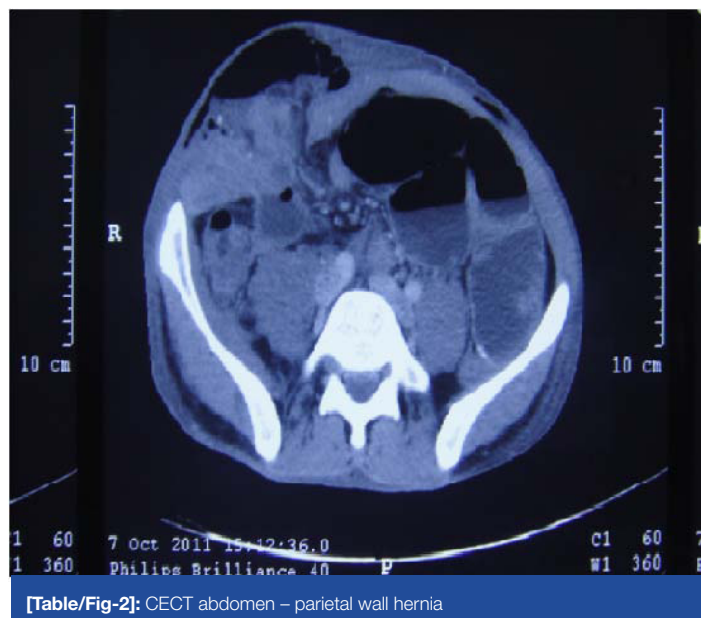
The criteria for traumatic abdominal wall hernia include immediate appearance of the hernia through the disrupted muscle and fascia after blunt abdominal trauma, and failure of the injury to penetrate the skin as defined by Damschen et al., [1] Spigelian hernia is a variety of interparietal hernia occurring at the level of arcuate line. It accounts for 0.1 to 2 percent of all abdominal wall hernias [2]. We are reporting a case of traumatic Spigelian hernia in a 38-year-old male patient who presented in the emergency department with appearance of a painful swelling in the right lower abdomen following fall from a tree three days back.

## CLINICAL CASE

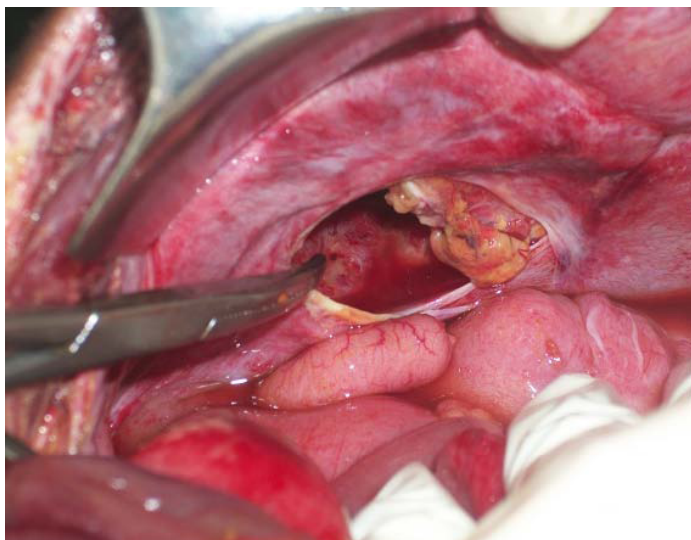
A 38-year-old male patient presented in the emergency department with complain of painful swelling in the right lower abdomen. Patient met injury to the right lower abdomen following fall from a tree three days back. He also complained of non-passage of stool and flatus for one day. On general examination, patient had tachycardia (pulse-110/min). On local examination, tender irreducible parietal swelling of size 10×10 cm [Table/Fig-1] was present in the right lower abdomen with no expansile cough impulse. There was edema and local rise of temperature in the overlying skin. X-ray abdomen was suggestive of multiple air fluid levels with dilated small bowel loops. Ultrasound abdomen revealed edematous bowel loops and heterogeneous fluid collection in the parietal layer in the right lower abdomen. CECT abdomen showed a 2.1 cm defect [Table/Fig-2] in the transverse abdominis muscle at the level of arcuate line, herniation of small bowel loops and surrounding mesentery and the presence of subcutaneous emphysema. On exploratory laparotomy, a 2×3 cm defect [Table/Fig-3] was noted in the parietal layer in the right lower abdomen with herniation of ileal loop. Herniated bowel loop was gangrenous and perforated [Table/Fig-4] and there was spillage of fecal matter into the adjoining necrosed parietal layer. Gangrenous bowel loop was resected and ileostomy was performed. Necrosed parietal layer was debrided. Post-operative course was uneventful and ileostomy was closed after 6 weeks.



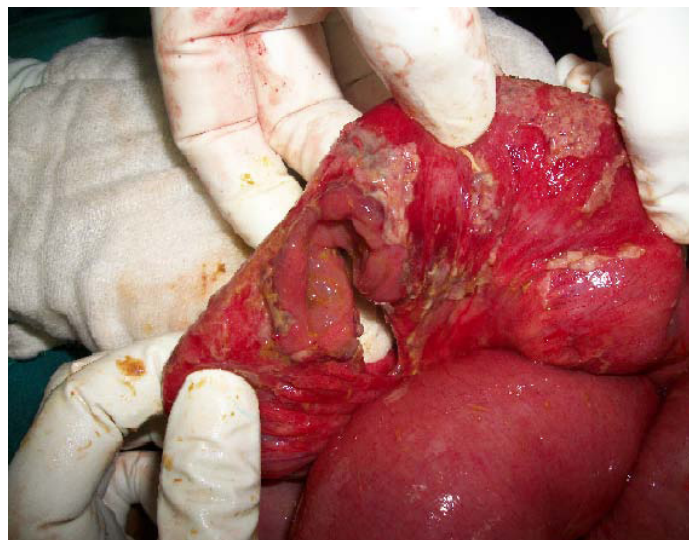[Table/Fig-1]: Parietal wall swelling



[Table/Fig-2]: CECT abdomen – parietal wall hernia



[Table/Fig-3]: Parietal wall defect



[Table/Fig-4]: Perforated bowel loop

## DISCUSSION

Traumatic abdominal wall hernia (TAWH) was first described by Selby [3]. The pathophysiology of TAWH involves the application of a blunt force to the abdomen over an area large enough to prevent penetration of the skin [4]. Three types of traumatic abdominal wall hernia were described (by Wood et al.) according to the mechanism and size of the defect. Type I are small defects caused by blunt trauma. Type II are larger defects occurred during motor vehicle crashes. In Type III, there are abdominal wall defects with bowel loop herniation following deceleration injuries, which are extremely rare [5]. CECT abdomen is the investigation of choice in evaluation of blunt trauma abdomen [1]. Diagnostic laparoscopy seems to be an excellent adjunct in the management of TAWHs. In the event of a negative diagnostic laparoscopy, one can repair the hernia by the local approach and avoid unnecessary general abdominal exploration [6].

Most authors have advocated immediate laparotomy with repair of the defect because of the high incidence of associated intra-abdominal injury i.e. upto 30 percent [7] and to avoid the complications such as incarceration or strangulation and subsequent morbidity. Local exploration through an incision overlying the defect may be an option for small defects caused by low velocity injury, but TAWHs following high-energy trauma should undergo exploratory laparotomy through a midline incision owing to a high prevalence of associated intra-abdominal injuries [8]. Primary mesh repair should be considered in cases with no hollow viscus injuries, relatively large defects, and the presence of tension for direct closure [9].

## CONCLUSIONS

Traumatic abdominal wall hernia should be suspected in a patient with tender, localised swellings of the abdominal wall following blunt trauma. Computed tomography of the abdomen is the investigation of choice to diagnose spigelian hernia and associated intra-abdominal injuries. Urgent surgical measures to prevent further bowel injury and associated complications are necessary.

## REFERENCES

- [1] Damschen DD, Landercasper J, Cogbill TH, Stolee RT: Acute traumatic abdominal hernia: Case reports. *J Trauma*. 1994 36:273-76.
- [2] Montes IS, Deysine M: Spigelian and other uncommon hernia repairs. *Surg Clin North Am*. 2003 83:1235.
- [3] Selby CD: Direct abdominal hernia of traumatic origin. *JAMA*. 1906 47:1485-86.
- [4] Ganchi PA, Orgill DP: Auto penetrating hernia: A novel form of traumatic abdominal wall hernia: case report and review of the literature. *J Trauma*. 1996 41:1064-6.
- [5] Hassan KA, Elsharawy MA, Moghazy K, AlQurain A. Handlebar hernia: A rare type of abdominal wall hernia. *Saudi J Gastroenterol*. 2008 14:33-35.
- [6] Goliath J, Mittal V, McDonough J: Traumatic handlebar hernia: a rare abdominal wall hernia. *J Paediatr Surg*. 2004 39:e20-e22.
- [7] Dreyfuss DC, Flancbaum L, Krasna IH, Tell B, Trooskin SZ: Acute trans-rectus traumatic hernia. *J Trauma*. 1986 26:1134-6.
- [8] Lane CT, Cohen AJ, Cinat ME. Management of traumatic abdominal wall hernia. *Am Surg*. 2003 69:73-76.
- [9] Drago SP, Nuzzo M, Grassi GB: Traumatic ventral hernia: report of a case, with special reference to surgical treatment. *Surg Today*. 1999 29:1111-14.

### PARTICULARS OF CONTRIBUTORS:

1. Resident, Department of Surgery, Lady Hardinge Medical College, New Delhi, India.
2. Assistant Professor, Department of Surgery, Lady Hardinge Medical College, New Delhi, India.
3. Assistant Professor, Department of Surgery, Lady Hardinge Medical College, New Delhi, India.
4. Professor, Department of Surgery, Lady Hardinge Medical College, New Delhi, India.
5. Professor, Department of Surgery, Lady Hardinge Medical College, New Delhi, India.

### NAME, ADDRESS, E-MAIL ID OF THE CORRESPONDING AUTHOR:

Dr. Aravinda P.S.,  
63, Defence Enclave, Vikas Marg, New Delhi-110092, India.  
Phone: +918860928708, E-mail: psarvind07@gmail.com

FINANCIAL OR OTHER COMPETING INTERESTS: None.

Date of Submission: **Oct 26, 2013**  
Date of Peer Review: **Dec 20, 2013**  
Date of Acceptance: **Jan 25, 2014**  
Date of Publishing: **May 15, 2014**