

Primary Abdominal Pregnancy in the Uterosacral Ligament with Haemoperitoneum: A Near Miss

SIRISHA RAO GUNDBATTULA¹, MANJULA POCHIRAJU²

ABSTRACT

Primary abdominal pregnancy has a higher mortality rate than other ectopic gestations. Delayed diagnosis can be associated with catastrophic haemorrhage. This report describes a spontaneous conception which occurred in the uterosacral ligament in a woman with no known risk factors for an ectopic pregnancy. Extrauterine pregnancy was diagnosed by ultrasound and laparoscopy was performed secondary to haemoperitoneum, which revealed a pregnancy implanted in the right uterosacral ligament. The rarity of this condition signifies the need for reporting all cases to facilitate future research and clinical management.

Keywords: Ectopic pregnancy, Acute abdomen, Primary peritoneal pregnancy, Haemoperitoneum, Laparoscopy

CASE REPORT

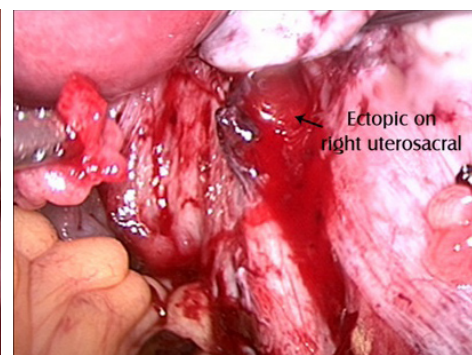
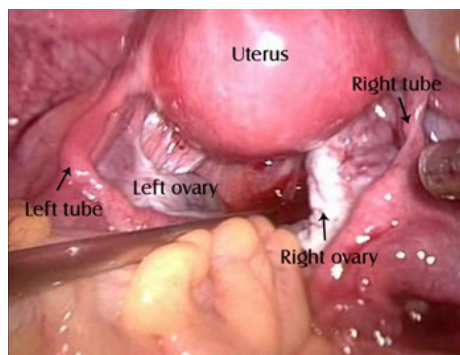
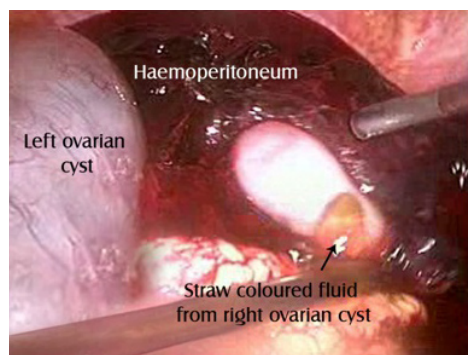
A 30-year-old lady, G₃P₁L₁A₁, presented with a one-day history of right-sided lower abdominal pain and giddiness, of one day's duration. There was no preceding amenorrhoea. Examination revealed mild pallor and normal vital signs. Cervical movements were tender. Ultrasonography revealed a normal uterus and bilateral anechoic ovarian cysts (30 and 50 mm in right and left ovary respectively). A 20 x 16 mm echogenic right adnexal mass with a 2 mm viable embryo was noted in the pouch of Douglas. There was free fluid in the pelvis and minimal fluid in Morrison's pouch. Investigations revealed haemoglobin level of 9.2 gm/dL and serum Beta human chorionic gonadotropin (hCG) level of 5699 mIU/mL. With a provisional diagnosis of a right tubal ectopic pregnancy, she was taken up for emergency surgery. Laparoscopy disclosed haemoperitoneum which amounted to ~1000ml. Both ovaries were enlarged and had simple cysts [Table/Fig-1]. Both fallopian tubes were found to be normal [Table/Fig-2]. The ectopic pregnancy was localized in the right uterosacral ligament, close to its uterine attachment. It measured 20 x 20 mm and there was active bleeding from this site [Table/Fig-3]. Hydrodissection was used and the products of conception were removed laparoscopically. Bipolar diathermy was applied to secure haemostasis. A single dose of parenteral methotrexate 50 mg/m² was administered postoperatively. Histopathologic examination of the tissue from the site of ectopic pregnancy showed chorionic villi. Serum Beta hCG level dropped to 81 mIU/mL, a week later.

DISCUSSION

An abdominal pregnancy is a form of ectopic pregnancy which is implanted within the peritoneal cavity, outside the fallopian tube and ovary and which is not located in the broad ligament. Its incidence is reported to be 10.9/100,000 pregnancies and 9.2/1000 ectopic pregnancies [1]. Pregnant women with advanced maternal age may be at an increased risk of extra-tubal gestations [2]. The mortality rate associated with early abdominal pregnancies can be as high as 30/1000 [3].

Abdominal pregnancies result from secondary implantation of aborted tubal pregnancies or intra-abdominal fertilization of sperms and ova. Our patient fulfilled the criteria for diagnosis of primary abdominal pregnancy put forth by Studdiford: pregnancy related exclusively to the peritoneal surface (early enough to eliminate the possibility of a secondary implantation after a primary tubal nidation), normal tubes and ovaries and no evidence of a uteroperitoneal fistula [4]. As the original site of implantation may be hard to determine, the original criteria were subsequently modified, to include only pregnancies which had completed less than 12 weeks of histologic gestation [5].

Risk factors for abdominal pregnancy include tubal damage pelvic inflammatory disease, endometriosis, intrauterine insemination, assisted reproductive techniques and use of intrauterine contraceptive devices [3,6,7]. Endometriotic spots represent



[Table/Fig-1]: Bilateral ovarian cysts with haemoperitoneum

[Table/Fig-2]: Normal uterus and tubes

[Table/Fig-3]: Ectopic pregnancy implanted in the right uterosacral ligament

a favourable site for implantation [8]. Poole et al., reviewed 225 cases of early abdominal pregnancies (which had completed less than 20 weeks gestation) from 1965 to 2009. One-fourth of them were located in the pouches surrounding the uterus (majority in the pouch of Douglas). Abdominal pregnancy was diagnosed at 9 weeks of gestation on an average, at a mean serum Beta hCG level of 15670 mIU/mL [3]. The most frequent complaint is abdominal pain [9] and other symptoms relate to the site of placental attachment. The trophoblast erodes into arterioles which lie underneath the peritoneum and can lead to massive intraperitoneal haemorrhage [8].

Characteristic	Lo & Lau [8]	Lo & Lau [8]	Shin et al., [11]	Dasari & Devi [12]	Cheung & Rosenthal [13]	Park & Shin [14]	Present Case
Age (years)	33	32	28	22	24	24	30
Obstetric formula	G ₁	G ₄ P ₂	G ₂ A ₁	G ₂ P ₁	NA	NA	G ₃ P ₁ A ₁
Risk factor	Endometriosis	None	None	Intrauterine device	None	None	None
Amenorrhoea (weeks)	6	7	8	NA	NA	5	None
Serum Beta hCG (mIU/mL)	NA	NA	NA	NA	1654	NA	5699
Treatment modality	Laparotomy	Laparoscopy	Laparotomy	Laparotomy	Laparoscopy	Laparoscopy	Laparoscopy

[Table/Fig-4]: Characteristics of women with uterosacral ligament implantation
NA – Not available

The uterosacral ligament is a very rare location for a primary abdominal pregnancy. The probable pathophysiology is the occurrence of fertilization in the rectouterine pouch, where sperms are known to accumulate and where the ovum lies due to dependent flow of peritoneal fluid [10]. [Table/Fig-4] depicts the characteristics of the reported cases of pregnancies which had occurred in the uterosacral ligament. Extra-tubal implantations were not suspected preoperatively.

Treatment modalities consist of surgery, parenteral/intraamniotic methotrexate, intracardiac potassium chloride, embolization and combinations of these [3,15]. Management depends on the gestational age, site of placental attachment, patient's condition and clinician's experience. The Beta hCG levels do not correlate with the success of medical management. Nearly 90% of cases of early abdominal pregnancies are treated by primary surgery, because most present with haemoperitoneum and almost half of those who are treated medically subsequently need to undergo operative procedures [3].

Select first trimester patients who are diagnosed early can be managed laparoscopically [6]. Operative laparoscopy should be limited to cases in which the conceptus has not become implanted in the intestinal interstices and is not near sites which are susceptible to complications [15]. The future fertility may not be affected, as the tubes and ovaries are not directly involved in pregnancy, nor are removed during the operative procedure nor are involved in postoperative adhesion formation [9].

Prior to presenting to our institute, our patient was admitted elsewhere with abdominal pain, was diagnosed to have bilateral ovarian cysts

and given symptomatic treatment. The classic clinical triad of abdominal pain, amenorrhoea and vaginal bleeding is found in only 50% of ectopic pregnancies and vigilance is key to making the right diagnosis. Extrauterine pregnancies should always be considered in the differential diagnosis of abdominal pain which occurs in women who are in the reproductive age group. The timely and appropriate use of transvaginal ultrasound and serum Beta hCG can facilitate early diagnosis and successful management by minimally invasive surgery. Had there been no evidence of intraperitoneal bleeding, we might have considered medical management and the diagnosis of a primary peritoneal pregnancy would have been missed altogether,

which leads to speculation about the true incidence of this condition. It was a near miss in more than one sense: both for the patient and the fraternity of gynaecologists.

REFERENCES

- [1] Atrash HK, Friedge A, Hogue CJ. Abdominal Pregnancy in the United States: Frequency and Maternal Mortality. *Obstet Gynecol.* 1987;69(3):333-7.
- [2] Pochiraju M, Surampudi K, Marakani LR, Dasari S, Gundabattula SR. A Case Control Study Comparing Risk Factors for Ectopic Gestation in Unusual and Tubal Gestations. *Int J Infert Fetal Med.* 2013;4(1):14-7.
- [3] Poole A, Haas D, Magann EF. Early Abdominal Ectopic Pregnancies: A Systematic Review of the Literature. *Gynecol Obstet Invest.* 2012;74:249-60.
- [4] Studdiford WE. Primary peritoneal pregnancy. *Am J Obstet Gynecol.* 1942;44:487-91.
- [5] Friedrich EG, Rankin CA. Primary pelvic peritoneal pregnancy. *Obstet Gynecol.* 1968;31:649-53.
- [6] Young RSH, Huang MC, Chen CP. Successful Laparoscopic Management of Primary Abdominal Peritoneal Pregnancy in the Cul-de-sac. *Taiwanese J Obstet Gynecol.* 2005;44(2):172-4.
- [7] Kar S. Primary abdominal pregnancy following intrauterine insemination. *J Hum Reprod Sci.* 2011;4(2):95-9.
- [8] Lo KW, Lau TK. Ectopic Pregnancy in Uterosacral Ligament. *J Obstet Gynaecol Res.* 1997;23(5):415-9.
- [9] Martin JN, McCaul JF. Emergent Management of Abdominal Pregnancy. *Clin Obstet Gynecol.* 1990;33:438-47.
- [10] Cavanagh D. Primary peritoneal pregnancy. *Am J Obstet Gynecol.* 1958;76:523-32.
- [11] Shin JS, Moon YJ, Kim SR, Kim KT, Moon H, Hwang YY. Primary Peritoneal Pregnancy Implanted on the Uterosacral Ligament: A Case Report. *J Korean Med Sci.* 2000;15:359-62.
- [12] Dasari P, Devi S. Primary Peritoneal Pregnancy: A Case Report. *J Obstet Gynaecol Res.* 2000;26:45-7.
- [13] Cheung VYT, Rosenthal DM. Abdominal pregnancy. *J Minim Invas Gynecol.* 2005;12(1):9.
- [14] Park IY, Shin JC. A case of abdominal pregnancy implanted on uterosacral ligament. *Ultrasound Obstet Gynecol.* 2007;30(P 29.04):561.
- [15] Cobellis L, Stradella L, Messalli EM. Contribution to the choice of therapy in abdominal pregnancy. *Panminerva Medica.* 2000;42(2):159-61.

PARTICULARS OF CONTRIBUTORS:

1. Consultant, Department of Obstetrics and Gynaecology, Fernandez Hospital, Hyderabad, India.
2. Consultant, Department of Obstetrics and Gynaecology, Fernandez Hospital, Hyderabad, India.

NAME, ADDRESS, E-MAIL ID OF THE CORRESPONDING AUTHOR:

Dr. Sirisha Rao Gundabattula,
4-1-1230, Bogulkunta, Hyderabad – 500001, India.
Phone: 09052595013, E-mail: drgsirisharao@gmail.com

FINANCIAL OR OTHER COMPETING INTERESTS: None.

Date of Submission: **Oct 15, 2013**
Date of Peer Review: **Nov 14, 2013**
Date of Acceptance: **Mar 03, 2014**
Date of Publishing: **May 15, 2014**