

# A Simplified Technique for Fabrication of Orbital Prosthesis

NEERAJ SHARMA<sup>1</sup>, G.K.THAKRAL<sup>2</sup>, ABHILASH MOHAPATRA<sup>3</sup>, JYOTSNA SETH<sup>4</sup>, PALLAVI VASHISHT<sup>5</sup>

## ABSTRACT

Eye is a vital organ not only for vision, but also an important component of facial expression, and over-all personality of a person. Loss of eye, apart from leading to impaired vision has a crippling effect on the psychology of the patient. Prosthodontic rehabilitation of such cases includes fabrication of prosthesis by acrylic resin, silicone and implants. However, not all patients are willing to use implants for maxillofacial rehabilitation. Therefore, a custom made orbital prosthesis serves as an affordable and satisfactory alternative.

**Keywords:** Custom made orbital prosthesis, Esthetics, Orbital defect

## A Brief History of Ocular Prosthesis

The fabrication of eyes is not limited to the modern age. They have been used for centuries, with the earliest known examples found in mummies dating back to the fourth dynasty in Egypt (1613-2494 BC). Ambrose Pare, a French dentist is considered to be the pioneer of modern artificial eyes. He used glass and porcelain to fabricate artificial eyes [1].

Naval dental school (1940) tested the use of acrylic resin in fabricating a custom ocular prosthesis. Unlike a glass eye, an acrylic eye was easy to fit and adjust, unbreakable, inert to ocular fluids, esthetically good, longer lasting and easier to fabricate. Today a vast majority of patients all around the world wear ocular prosthesis made of acrylic. Several techniques have been used in fabricating and fitting of artificial eyes. Modifying a stock tray for making an impression of the ocular defect (Taicher et al.) and the custom eye technique (Benson, 1977) are the most commonly used techniques. The fabrication of a custom acrylic resin eye provides better esthetics and gives precise results because an impression establishes the defect contours whereas, iris and the sclera are custom fabricated and painted [2].

## CASE REPORT

A 40-year-old male patient reported in the Department of Prosthodontics and Maxillo-facial Prostheses, Seema Dental College & Hospital, Rishikesh with missing right eye. The patient came with the chief complaint of unsatisfactory esthetics due to loss of an eye [Table/Fig-1]. The medical history revealed malignant melanoma of the right eye and its subsequent enucleation about 6 months back. The clinical examination revealed a completely

healed-up eye socket. Patient was given various treatment options including implant retained prosthesis. However, patient declined the latter option for the reasons of cost and surgery involved. It was decided to fabricate acrylic eye prostheses for the missing eye. The patient was explained the treatment and patient consent was taken for the proposed treatment plan.

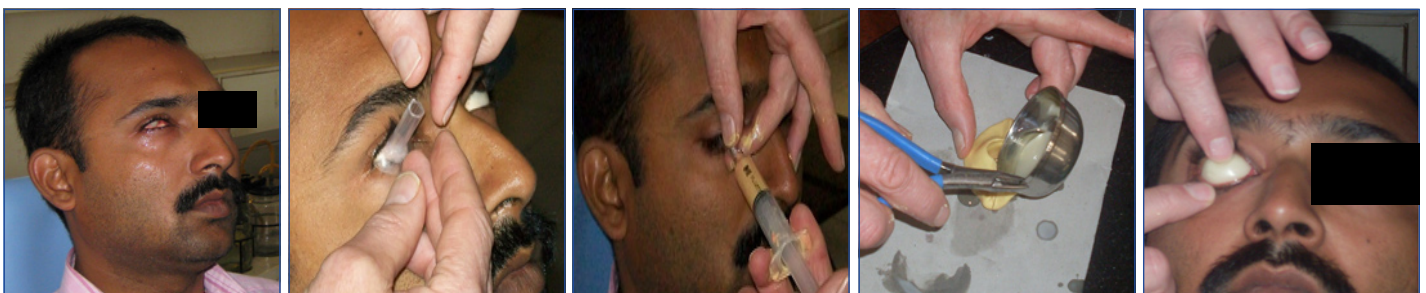
Other treatment option can be given to patient such as implant which can be divided into two main groups. Non integrated (non-porus) and integrated (porus).

## Procedure

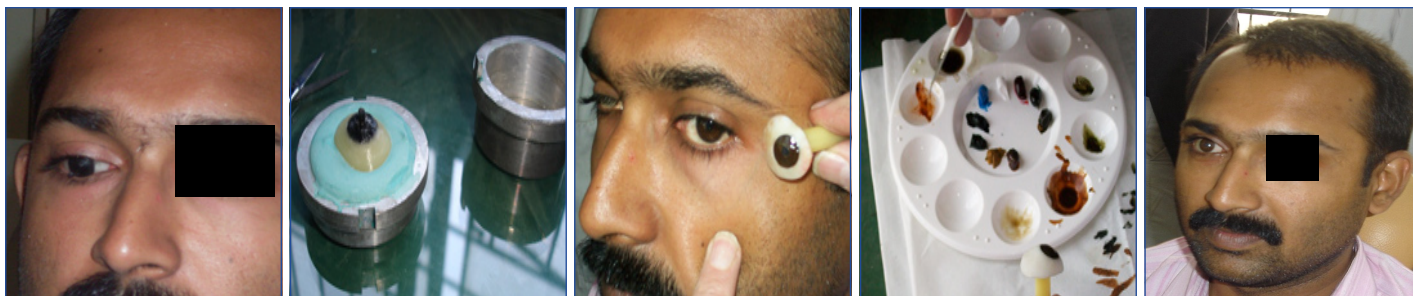
After evaluation and inspection of the ophthalmic socket and defect region, the diameter of the iris and pupil on the intact side was measured and recordings were noted.

A prefabricated (stock) eye tray was selected and adjusted so that it comfortably and loosely fits the socket [Table/Fig-2]. There are various impression techniques for making impression of ocular prosthesis, like Direct impression/external impression, impression with a stock ocular tray or modified stock ocular tray, impression with custom ocular tray, impression using a stock ocular prosthesis, ocular prosthesis modification and the wax sclera bank technique. In the present case direct impression technique using a modified stock tray was used [3].

The patient was seated in an upright position with head supported by the headrest. This position allowed the natural positioning of the palpebrae and surrounding tissues relative to the force of gravity. The eyebrow and eyelashes were lightly lubricated. Irreversible hydrochloride impression material was loaded in the syringe and



[Table/Fig-1]: Pre-operative photograph of the patient [Table/Fig-2]: A prefabricated (stock) eye tray [Table/Fig-3]: Impression made in the defect area [Table/Fig-4]: Ivory coloured molten wax was poured in this putty index [Table/Fig-5]: Wax pattern trial done



**[Table/Fig-6]:** Orientation was finalized taking a guide from the iris disk of left eye **[Table/Fig-7]:** Flasking was done using special mini flasks **[Table/Fig-8]:** Acrylized prosthesis without characterization **[Table/Fig-9]:** Characterization done **[Table/Fig-10]:** Patients appearance with custom made prosthesis

sufficient material was ejected to fill the concavity of the tray [Table/Fig-3]. The tray was positioned in the defect and sufficient material was injected to elevate the lid contours similar to the normal side. Once filled, the patient was instructed to move both the eyes up and down. After the impression had set, the assembly was removed and examined for defects and voids [4].

An index using elastomeric putty impression material was fabricated from the impression and ivory colored molten wax was poured in this putty index [Table/Fig-4].

After the wax had cooled, the wax pattern of sclera was recovered. The wax pattern was smoothened and polished, so as to make it ready for trial in the eye socket [Table/Fig-5]. In order to insert the wax pattern, the upper lid was lifted and the superior edge of the pattern was placed behind the lid and gently pushed upward. The inferior border of the pattern was seated in the inferior fornix by drawing the lower lid down and the lower lid was released. The eye contours on both sides were checked for esthetics and comfort.

The iris disk was placed on the wax pattern sclera in the eye socket and its orientation was finalized taking a guide from the iris disk of left eye [5] [Table/Fig-6]. The iris disk and wax pattern assembly was carefully removed from the eye and flasking was done using special mini flasks. De-waxing was done taking care that there was complete wax elimination from the mold space [Table/Fig-7].

Clear ocular acrylic resin was mixed and placed into the mold. The mold was packed with heat cured acrylic resin and kept for bench curing to enable complete polymerization and prevention of any excess un-reacted monomer. This enables the minimization of porosities and gives a good finish to the prosthesis. Long curing cycle of 4-6 hours was used so as to prevent the presence of any residual monomer in the prosthesis. It prevents any untoward irritation or sensitivity by the monomer in the final prosthesis and thereby avoids rejection of the prosthesis. The eye socket is extremely sensitive part of the body and the residual conjunctiva and its related structures may react to any surface roughness and irregularities [6]. The excess resin flash was removed after opening the trial pack and the location of the iris disk was verified to ensure that it had not moved during trial packing.

The resultant scleral blank was deflasked upon curing, trimmed and polished.

The position and gaze of the artificial eye was again verified in the patient. The sclera was removed from patient and was slightly roughened using sandpaper disks to prepare it for adding the simulated vasculature [6]. The thickness of resin plate should be up to 3mm [7].

Rayon-thread fibrils were placed onto the surface of the sclera using the monomer polymer syrup. The pattern and type of vessels (tortuous, straight or branched) like the opposite eye were reproduced [Table/Fig-8]. The colors found in the sclera are usually yellow and blue, or a combination of both. Greens and browns may also be present. The scleral painting begins with the application of a wash of yellow comparable to that found on the patient's natural eye [7] [Table/Fig-9]. Thereafter, blue was added, that is usually located inferior and superior to the iris.

Finally, any characteristic details present in the natural eye were also reproduced using appropriate stains. Once completed, a coat of monomer and polymer was applied to the sclera. A thin layer of clear acrylic resin was coated in order to give it a more natural and life-like appearance.

The prosthesis was cleaned with water followed by antibacterial solution before placing it in the socket [Table/Fig-10]. Fit of the artificial eye was evaluated and minor adjustments were made as necessary.

Follow-up ideally should be carried out after three days to eliminate immediate irritation or any pressure points.

The final outcome of the prosthesis was ascertained from the satisfying looks on the face of the patient and from the follow-up a week later. The patient was given instructions for wearing the prosthesis and also the home care protocol as under:

- Prosthesis should be handled with care and with clean hands.
- Removal of acrylic prosthesis during night is recommended to avoid any accidental displacement and injury to the underlying tissues.
- It should be soaked in an antibacterial solution to destroy the surface bacteria upon removal from the socket.
- Routine cleaning and polishing of prosthesis should be done every year to prevent deposition of protein and bacteria.

## DISCUSSION

The art of making artificial eyes has been practiced since ancient times. The first ocular prosthesis was made by Romans and Egyptian priests as early as fifth century BC. Artificial eyes were made of enamel, metal or painted clay and attached to cloth and worn outside the socket. In the 15<sup>th</sup> century, the first in-socket artificial eye was made using gold with colored enamel [8]. With the advent of some newer materials like heat-polymerized acrylic resin as used here, it is possible to fabricate prostheses with a life-like appearance. Rehabilitation of a patient with an ocular defect by a custom-made ocular prosthesis not only substantially improves the facial appearance; the fit of the prosthesis may also be enhanced by relining technique. An artificial eye usually fits snugly in the conjunctiva space [9]. The lack of movement of the fornix restricts its mobility and serves as an advantage. It prevents any dislodgement and/or displacement of the prosthesis in the socket. Non-integrated implants have direct attachment to the ocular prosthesis and they include the acrylic (PMMA) glass and silicone spheres [10].

Integrated implant supported technique involves surgical placement of the implant, followed by a fixed attachment of eye prosthesis onto it. Integrated implants are fabricated from a variety of materials including aluminium oxide and polyethylene. However, porous nature of integrated implants allows fibro-vascular growth in and around the implant, thereby causing a potential threat of infection due to lack of proper hygiene. Other modification of implant design includes conical orbital Implant (COI) and multipurpose conical orbital implants.

Out of these various treatment options, custom made ocular prosthesis is the most preferred option as it accurately fits into eye socket, better esthetics can be achieved and is cost effective. A precise iris positioning is an important aspect in achieving the satisfying facial esthetics [11].

McArthur [12] described methods for positioning the artificial eye in the orbital prosthesis using an ocular locator and fixed caliper. This determined the placement of the prosthetic eye in the medioletral and supero-inferior planes. Benson [13] suggested a method for fabricating a custom made acrylic resin ocular prosthesis in which he determined the size and position of iris by visual judgement.

### Advantages of Custom Ocular Prosthesis

- Retains the shape of socket.
- Prevents collapse of the lids.
- Prevents accumulation of fluid in the cavity.
- Maintains palpebral opening similar to natural eye [14].

### DISADVANTAGES

Making an impression of the orbital area with an accurate record of surface details can be a difficult procedure.

### LIMITATIONS

According to Beumer et al., intimate contact between the ocular prosthesis and the tissue bed is needed to distribute even pressure, therefore a prefabricated prosthesis should be avoided. Voids and discrepancies of fit in the prefabricated prosthesis may lead to easy displacement and dislodgement of the prosthesis.

### CONCLUSION

The goal of the maxillo-facial prosthetic treatment is to return the patient with a natural appearance and greater satisfaction. The disfigurement resulting from loss of an eye can cause significant

psychological as well as social consequences. However, with the advancement in ophthalmic surgery and ocular prosthesis, patient can be rehabilitated very effectively. The maxillo-facial Prosthodontist should provide prosthetic treatment to the best of his ability and should also consider psychological and financial aspects of the treatment. Help of other specialist should be taken during rehabilitation of the patient, if required.

### REFERENCES

- [1] Taylor TD. Clinical maxillofacial prosthetics, 3rd ed. Quintessence Publishing Co. Inc. Chicago. 2000; 233-76.
- [2] Beumer J, Curtis TA, Marunick MT, Maxillofacial rehabilitation, Prosthodontic and surgical considerations. St. Louis, 1996: The CV Mosby Co.
- [3] Ponnanna AA, et al. Art and science behind esthetic ocular prosthesis: A case report. *Int J Dent Case Reports*. 2012; 2(5): 103-09.
- [4] Shenoy KK, Nag PV. Ocular Impressions. An overview. *The Journal of Indian Prosthodontic Society*. 2007; 7: 5-7.
- [5] Satyabodh S.Guttal, et al: A Simple Method of Positioning the Iris Disk on a Custom-Made Ocular Prosthesis. *Journal of Prosthodontics*. 2008; 17:223-27.
- [6] Dahane TM, Bhandari AJ. Rehabilitation of a Patient with Orbital Defect: case report. *Journal of Indian Prosthodontic Society*. 4, 4, 9-11.
- [7] Cain JR. Custom Ocular Prosthesis. *J Prosthet Dent*. 1982; 48: 690-4.
- [8] Prashanti E, Reddy JM, Vinay Kumar, Mathew X, All about Ocular Prosthesis-A Review. *Indian Dentist Research and Review*. 2008; 63: 53-8.
- [9] Shome D, Honavar SG, Raizada K, Raizada D. Implant and prosthesis movement after enucleation; a randomoized controlled trail". *Ophthalmology*. 2010 111- (8):1638-44.
- [10] Chuah CT, Chee SP, Fong KS, Por YM, Choo CT, Luu C, et al. Integrated hydroxyapatite implant and integrated implant in enucleated asian patient. *Annals of the Academy of Medicine; Singapore*. 2004 33(4);477-83.
- [11] Jitendra J, gayathri S, Jethwani AK, Verma J. Funtional Impression technique for an ocular. *Indian Prosthodont Soc*.2012;12(1):55-8.
- [12] McArthur RD: Aids for positioning prosthetic eye in orbital prosthesis. *J Prosthet Dent*. 1977;37;320-6.
- [13] Benson P: The fitting and fabrication of a custom resin artificial eye *Journal of Prosthetic Dentistry*. 1977;38:532-9.
- [14] Debnath N, Gupta R, Meenakshi A,Ramkumar K, John j. A Simplified approach to fabricate a custome-made ocular prosthesis. *Nt J Prosthodont Restor Dent*. 2013;3(1);25-9.

#### PARTICULARS OF CONTRIBUTORS:

1. Senior Lecturer, Department of Prosthodontics, Seema Dental College Rishikesh, Uttarakhand, India.
2. Professor, Department of Prosthodontics, Seema Dental College Rishikesh, Uttarakhand, India.
3. Senior Lecturer, Department of Prosthodontics, Institute of Dental Sciences, Soa University Bhubaneswar, Odisha, India.
4. Senior Lecturer, Department of Prosthodontics, Seema Dental College Rishikesh, Uttarakhand, India.
5. Senior Lecturer, Department of Prosthodontics, Seema Dental College Rishikesh, Uttarakhand, India

#### NAME, ADDRESS, E-MAIL ID OF THE CORRESPONDING AUTHOR:

Dr. Neeraj Sharma,  
Seema Dental College, Virbhdra Road Rishikesh-249201, Uttarakhand, India.  
Phone: 9837887423, E-mail: drneerajmids@yahoo.in

Date of Submission: **Mar 13, 2014**  
Date of Peer Review: **Apr 07, 2014**  
Date of Acceptance: **Apr 22, 2014**  
Date of Publishing: **Jun 20, 2014**

FINANCIAL OR OTHER COMPETING INTERESTS: None.