

# A Lobulated Spleen with Multiple Fissures and Hila

SATHEESHA B. NAYAK<sup>1</sup>, PRAKASHCHANDRA SHETTY<sup>2</sup>, DEEPTHINATH R<sup>3</sup>, SRINIVASA RAO SIRASANAGANDLA<sup>4</sup>, SUREKHA D SHETTY<sup>5</sup>

## ABSTRACT

During our dissection classes, we observed a lobulated spleen with multiple hila and fissures. The spleen presented 4 hila and 5 deep fissures. The hila were seen on the visceral surface. The fissures extended into the substance of the spleen from superior border, inferior border and the visceral surface. Because of these fissures, the spleen appeared to be lobulated, having seven distinct lobes/lobules. Knowledge of this variation could be useful to the radiologists and surgeons.

**Keywords:** Lymphoid organ, Splenic Notch, Splenic Fissure, Variation

## CASE REPORT

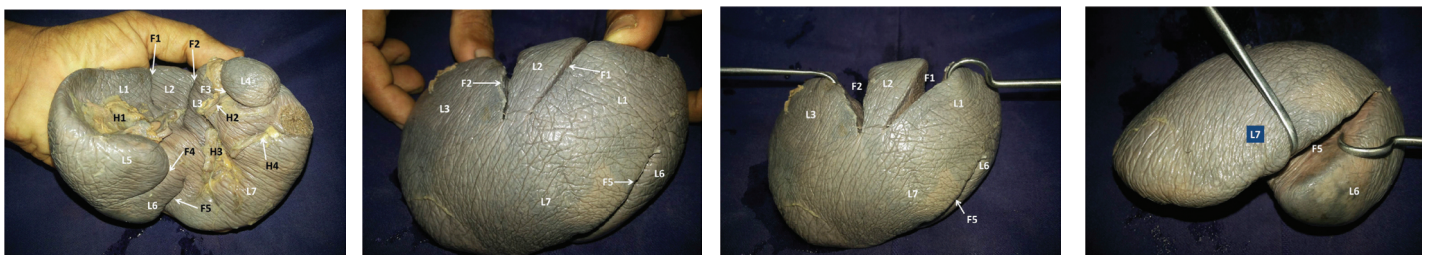
During routine dissection classes for medical undergraduate students, a lobulated spleen with multiple hila and fissures was noted. The spleen apparently looked healthy with a light purple/pinkish grey colour. It was 2.5cm thick, 8cm broad and 13cm long. The hilum of the spleen was divided into four parts and all the four parts allowed the passage of individual branches of the splenic vessels. The largest division of the hilum was situated just above the intermediate border near the posterior end of the spleen. The other three hila were situated closer to the anterior end of the spleen on the visceral surface [Table/Fig-1].

Upper border of the spleen presented three fissures; two of which were 3.5 cm deep and were directed downwards. These fissures were seen on both visceral and diaphragmatic surfaces of the spleen. The third fissure was directed forwards towards the anterior end and it was 1.5 cm deep. It was seen only on the visceral surface. The fourth fissure was directed backward from the visceral surface of the spleen. This fissure was 3cm deep and passed through the intermediate border. The fifth fissure was the deepest among all and measured 4.5cm in depth. It extended from inferior border of the spleen, obliquely towards its posterior end [Table/Fig-2,3]. This fissure was also seen on both diaphragmatic and visceral surfaces of the spleen. The visceral peritoneum of the spleen extended completely till the bottom of all the five fissures. Because of the presence of these five fissures, the spleen had a characteristic lobulated appearance with seven distinct lobes/lobules [Table/Fig-4].

## DISCUSSION

Spleen is a variable organ with respect to its size, shape, fissures and position. Some of its variations might result in diagnostic pitfalls

and be interpreted as pathological process. Spleen is the large encapsulated mass of vascular and lymphoid tissue, situated in the upper left quadrant of the abdominal cavity between the fundus of the stomach and the diaphragm. It is needed for generating immune reactions to blood-borne antigens and for purifying the blood from foreign substances and aged or damaged erythrocytes [1]. The shape of the spleen varies from a wedge to a tetrahedron. On an average, in the adults, the spleen is 12cm long, 7cm broad and 3-4cm wide. It has an average adult weight of 150gms [2]. Usually the superior border of the spleen presents splenic notches and its visceral surface has a hilum. The hilum allows the passage of splenic vessels. Spleen is known to show variations in its size, shape and position [3]. One of the most common congenital anomalies of the spleen is the presence of accessory spleens in various parts of the abdomen in addition to the main organ [4]. In rare cases the spleen presents abnormal fissures and hila [5] and the knowledge of the same is very useful for radiologists in interpretation of the radiological findings. We report here, a spleen with multiple fissures and hila and discuss its clinical significance. The spleen begins to develop in the dorsal mesogastrium during the fifth week of fetal life from a mass of mesenchymal cells. Growth of the dorsal mesogastrium and rotation of the stomach help in moving the spleen from the midline position to the left side of the abdominal cavity. Rotation of the dorsal mesogastrium results in the formation of a splenorenal ligament, between the spleen and the left kidney. The portion of dorsal mesentery between the spleen and the stomach forms the gastrosplenic ligament [6,7]. During the early stages of development, the spleen is represented by a few splenic nodules which eventually fuse to form the spleen. Some of these nodules may get separated from the rest and develop independently. This will result in the formation of accessory spleens. During the fusion, the nodules fuse with each other smoothly except at the upper border. This is the



**[Table/Fig-1]:** Photograph of the visceral surface of the spleen. (F1, F2, F3, F4 and F5 fissures; H1, H2, H3 and H4, Hila; L1, L2, L3, L4, L5, L6 and L7, lobes)

**[Table/Fig-2]:** Diaphragmatic surface of the spleen. Fissures F1, F2 and F5 can be seen extending on to the surface. L1, L2, L3, L6 and L7, lobes can also be seen

**[Table/Fig-3]:** The diaphragmatic surface of the spleen. Fissures F1, F2 and F3 can be seen. Note the extension of the peritoneum into the depth of the fissures. L1, L2, L3, L6 and L7, lobes can also be seen

**[Table/Fig-4]:** Inferior view of the spleen showing the deepest fissure (F5). Two of the lobes (L6 and L7) can also be seen

embryological reason for having notches on the superior border. The foetal spleen is lobulated but the lobulation disappears by birth. However, it may persist along the medial part of the spleen. Rarely, a splenic lobule lies partially posterior to the upper pole of the left kidney and displaces it anteriorly [8]. The notches on the superior border of the adult spleen are remnants of the grooves that originally separated the fetal lobules. These notches can be sharp and are occasionally as deep as 2–3cm. Occurrence of an abnormal deep fissure on the diaphragmatic surface of the spleen has been reported recently [9]. It is quite rare to have deep fissures extending to the diaphragmatic surface and happens only in 1% of cases [5]. Gandhi et al., [10] have reported the presence of six notches on the superior border of the spleen and one on the anterior pole. As discussed earlier, abnormal notches have been found on the superior border, anterior pole and inferior border but there is no report on deep notches on the intermediate border. Our case is unique in having a deep fissure cutting through the intermediate border of the spleen. Four among the five fissures were so deep as to divide the spleen incompletely into seven distinct lobes/lobules. To the best of our knowledge, this is the first report on such a lobulation of the spleen. Presence of abnormal fissures and lobes might lead to erroneous diagnosis. Since the spleen is closely related to the left kidney and suprarenal glands, abnormal fissures and lobes of spleen might confuse the radiologists in interpretation of radiological findings especially in the blunt trauma of the upper abdomen. Smidt [11] has reported the presence of a congenital fissure mimicking splenic hematoma. Abnormal lobulation as reported here might cause misinterpretations as a mass originating from the kidney by the radiologists [12,13].

There are reports on variant branching patterns of splenic artery and point of their entry into the spleen [14-16] but reports on presence of multiple hila are lacking. In traumatic laceration of the spleen, the surgeon needs to ligate the splenic artery and remove the spleen. Presence of many hila, each containing a branch of splenic artery may lead to sparing any one of the branches without a ligature. This might lead to postoperative bleeding. Knowledge of the presence of multiple hila is of utmost importance during spleen preserving

splenic lymph node dissection in radical total gastrectomy [17]. It is also useful in laparoscopic splenic vessel preserving distal pancreatectomy procedure [18].

## REFERENCES

- [1] Cesta MF. Normal structure, function, and histology of the spleen. *Toxicol Pathol.* 2006; 34(6):455-65.
- [2] Standring S. editor. *Gray's Anatomy: The Anatomical Basis of the Clinical Practice*, Edinburg, England: Elsevier Churchill Livingstone. 39<sup>th</sup> edition. 1995;1239-44.
- [3] Nayak, BS, Somayaji, SN, Soumya KV. A Study on the variations of size, shape and external features of the spleen in south Indian population. *Int J Morphol.* 2011; 29(3):675-77.
- [4] Gayer GR, Zissin S, Apter E, Atar O, Portnoy, Y, Itzchak. CT findings in congenital anomalies of the spleen. *British Journal of Radiology.* 2001; 74 (884): 767–72.
- [5] Das S, AbdLatiff A, Suhaimi FH, Ghazalli H, Othman F. Anomalous splenic notches: a cadaveric study with clinical importance. *Bratisl Lek Listy.* 2008; 109(11):513-16.
- [6] Larsen WJ (1997). Larsen WJ, editor. *Human embryology (2<sup>nd</sup> edn)*. New York: Churchill Livingstone :229–59.
- [7] Moore KL, Persaud TVN (1998) *The developing human, clinically oriented embryology (6th edn)*. Philadelphia, PA: WB Saunders Co, 271–302.
- [8] Lee JKT, Sagel SS, Stanley RJ (1989) *Computed body tomography with MRI correlation (2<sup>nd</sup> edn)*. New York: Raven Press 521–41.
- [9] Nayak SB, Kumar V, Kumar N, Jetti R. Unusual fissure on the diaphragmatic surface of the spleen – a case report. *Int J AnatVar (IJAV)*. 2012; 5: 96–98.
- [10] Gandhi KR, Chavan SK, Oommen SA. Spleen with multiple notches: A rare anatomical variant with its clinical significance. *Int J Stud Res.* 2013; 3:24-25.
- [11] Smidt KP. Splenic scintigraphy. A large congenital fissure mimicking splenic hematoma. *Radiology.* 1977; 122: 169.
- [12] Dodds WJ, Taylor AJ, Erickson SJ, Stewart ET, Lawson T. Radiologic imaging of splenic anomalies. *American Journal of Roentgenology.* 1990; 155 (4): 805–10.
- [13] Gayer G, Hertz, M.; Strauss S, Zissin R. Congenital anomalies of the spleen. *Semin. Ultrasound CT MR.* 2006; 27(5):358-69.
- [14] Daisy Sahni A, Indarjit B, Gupta CN, Gupta DM, Harjeet E. Branches of the splenic artery and splenic arterial segments. *Clin Anat.* 2003; 16(5): 371-77.
- [15] Padmalatha K, Ramesh BR, Prakash BS, Balachandra N, Mamatha Y. Accessory splenic artery from left gastric artery. *International Journal of Anatomical Variations.* 2010; 3:106-07.
- [16] Pandey SK, Bhattacharya S, Mishra RN, Shukla VK. Anatomical variations of the splenic artery and its clinical implications. *Clin Anat.* 2004; 17(6):497-502.
- [17] Jie Z, Li Z, Cao Y, Liu Y, Jiang M, Lin L, et al. Spleen-preserving splenic lymph node dissection in radical total gastrectomy. *Chin J Cancer Res.* 2013; 25(4):477-8. doi: 10.3978/j.issn.1000-9604.2013.08.16.
- [18] Suzuki K, Itano O, Oshima G, Osaku M, Asanuma F, Kitagawa Y. Modified Laparoscopic Splenic Vessel-Preserving Distal Pancreatectomy: Matador Assistance and Peel-Away Technique. *World J Surg.* 2013; 4. [Epub ahead of print].

### PARTICULARS OF CONTRIBUTORS:

1. Professor, Department of Anatomy, Melaka Manipal Medical College (Manipal Campus), Manipal University, Karnataka, India.
2. Associate Professor, Department of Anatomy, Melaka Manipal Medical College (Manipal Campus), Manipal University, Karnataka, India.
3. Professor, Department of Anatomy, Melaka Manipal Medical College (Manipal Campus), Manipal University, Karnataka, India.
4. Lecturer, Department of Anatomy, Melaka Manipal Medical College (Manipal Campus), Manipal University, Karnataka, India.
5. Lecturer, Department of Anatomy, Melaka Manipal Medical College (Manipal Campus), Manipal University, Karnataka, India.

### NAME, ADDRESS, E-MAIL ID OF THE CORRESPONDING AUTHOR:

Dr. Satheesha Nayak B,  
Professor, Department of Anatomy, Melaka Manipal Medical College (Manipal Campus)  
Manipal University, Madav Nagar, Manipal, Karnataka, India.  
Phone: +91 820 2922519, 9844009059, E-mail : : nayaksathish@gmail.com

FINANCIAL OR OTHER COMPETING INTERESTS: None.

Date of Submission: **Feb 19, 2014**  
Date of Peer Review: **May 20, 2014**  
Date of Acceptance: **May 28, 2014**  
Date of Publishing: **Sep 20, 2014**