

A Rare Case of Variant Morphology of Peroneus Tertius Muscle

SRINIVASA RAO SIRASANAGNADLA¹, KUMAR MR BHAT², SATHEESHA B NAYAK³, PRAKASHCHANDRA SHETTY⁴, RAJESH THANGARAJAN⁵

ABSTRACT

Peroneus tertius (PT) is frequently used as a free muscle flap to treat the soft tissue defects and osteomyelitis, in the lower limb as it is functionally insignificant while balancing the foot during walking. The morphology of the PT is highly variable. In the present case we report a rare case of unusual morphology of the PT in a formalin embalmed male cadaver. At the level of ankle, PT divided into three tendons; two of them were inserted to the base of the distal phalanx of the fifth toe and base of the fifth metatarsal bone respectively. The smaller third tendon was attached to the fascia covering the capsule of the ankle joint. Further, extensor digitorum longus (EDL) gave only three tendinous slips for the second, third and fourth toes.

Keywords: Extensor digitorum longus, Morphology, Muscle flap, Peroneus tertius

CASE REPORT

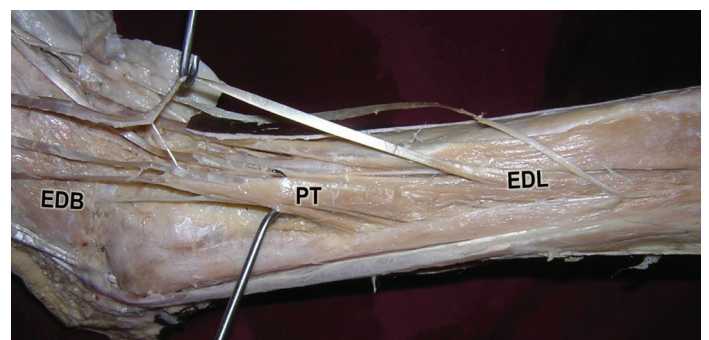
During regular dissections for medical undergraduates, we came across a rare anatomical variation in the anterior compartment of the leg. It was observed in an approximately 55-year-old formalin embalmed male cadaver of South Indian origin. The EDL continued as a tendon at the point of the junction between the upper two thirds and lower one third of the leg. At the dorsum of the foot, EDL tendon divided into three tendinous slips for the second, third and fourth toes. PT muscle divided into three tendons; first tendon was attached to the base of the distal phalanx of the fifth toe. The second tendon was inserted to the base of the fifth metatarsal bone. The third tendon was inserted to the thick fascia covering the capsule of the ankle joint. At the level of the ankle joint, a thick fibrous tendon connected the first tendon of the PT with the EDL tendon [Table/Fig-1&2]. Both PT and EDL were supplied by the deep peroneal nerve.

DISCUSSION

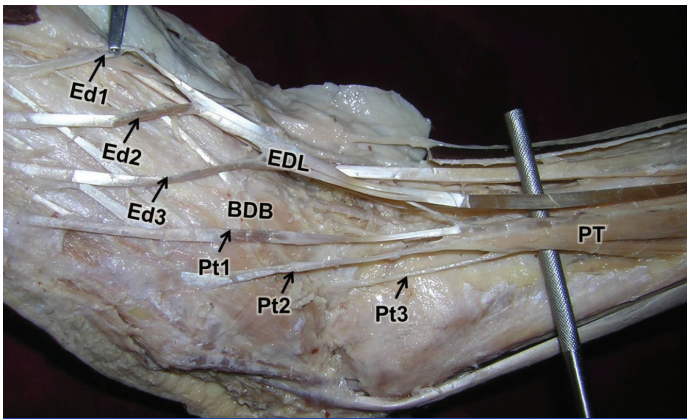
PT frequently shows variations in its development and attachments [1]. Though PT is closely related to the EDL, PT is considered as the migrated part of the extensor digitorum brevis (EDB) [2]. Origin, size of the muscle belly, and tendon thickness of the PT are highly variable [1]. Bergmann et al., [3] have described the several possible variations of the PT. It may present doubled tendon. It may give an additional slip to the fourth metatarsal bone or whole tendon may insert to the fourth metatarsal bone [3]. It may give a tendinous slip to extensor digitorum longus tendon to the little toe [3]. Sometimes, its additional slip may attach to the fascia covering the fourth interosseous muscle [3]. Rarely, the additional belly of the PT called peroneus tertius accessories may arise from the lower part of the anterior surface of fibula [3]. The tendon of such muscle belly is found to attach to styloid process of the fifth metatarsal bone [4]. In a study by Joshi et al., only in 45% cases PT was inserted to the base of fifth metatarsal bone [1]. In their study, in 11% of cases its insertion extended to the base and the shaft of fifth metatarsal bone; in 16% of cases, its insertion extended to the fourth interosseous space in addition to the base and shaft of the fifth metatarsal bone; in 17% of cases, it was attached to shaft of fourth metatarsal bone, fascia over fourth interosseous space and fifth metatarsophalangeal joint [1]. Rourke et al., [5] have observed the insertion of PT tendon to the shafts of both the fourth and fifth metatarsal bones. Mehta et al., [6] have reported an accessory muscle belly of the PT. The

tendon of this belly terminated by joining with the usual muscle and formed a common tendon. This common tendon divided into two slips; lateral slip was inserted into the base of fifth metatarsal bone and the medial slip joined the fourth tendinous slip of EDL [6]. In the present case, PT tendon presented a unique morphology. It gave two additional tendons, one of which was attached to the distal phalanx of the fifth toe and other tendon was inserted to the capsule of the ankle joint.

PT is functionally insignificant as its role is associated with other important muscles such as EDL and tibialis anterior. These muscles help in maintaining the mechanics of the foot during walking [7]. Clinically PT is used to reconstruct the soft tissue defects in the lower limb [2]. According to some reports, PT is used as a local muscle flap for the treatment of osteomyelitis, in the lower limb [8]. Claw foot deformity can be treated by altering the position of PT insertion [9]. PT tendon is also used to improve the ligamentous laxity of the ankle joint [10] and for the ruptured tibialis anterior tendon reconstruction [11]. In cases like present case, as PT was giving a tendon to the little toe, its usage in the above mentioned procedures may not be appropriate. It has been demonstrated that PT insertion may play a crucial role in initiation of torsional stresses which may lead to Jones fractures and stress fractures [12]. The additional tendon of PT inserting to the ankle joint capsule may affect the mechanics of the ankle and the knowledge about the same may be important during ankle joint surgeries.



[Table/Fig-1]: Dissection of the anterior compartment of the left leg (lateral view) showing the extensor digitorum longus (EDL) and peroneus tertius (PT) muscles. (EDB: extensor digitorum brevis)



[Table/Fig-2]: Closer view of the dissection of the dorsum of the left foot showing the peroneus tertius muscle (PT) tendons (Pt1, Pt2 and Pt3). Extensor digitorum longus (EDL) tendon dividing into three tendinous slips (Ed1, Ed2 and Ed3) is also seen

REFERENCES

- [1] Joshi, S, Athavale S. Morphology of peroneus tertius muscle. *Clinical Anatomy*. 2006;19(7):611-14.
- [2] Yildiz S, Yalcin B. A unique variation of the peroneus tertius muscle. *Surg Radiol Anat*. 2012;34(7):661-63.
- [3] Bergman RA, Afifi AK, Miyauchi M. A digital library of anatomy information. Illustrated Encyclopedia of Human Anatomic Variation: Opus I: Muscular System: Alphabetical Listing of Muscles: Peroneus tertius muscle. <http://www.anatomyatlases.org/AnatomicVariants/MuscularSystem/Text/P/22Peroneus.shtml>. Last accessed on 21/05/2014.
- [4] Mehta HJ, Janakiram S. Peroneus tertius accessories muscle. *J Anat Soc Ind*. 1976;25(1): 24-25.
- [5] Rourke K, Dafydd H, Parkin IG. Fibularis tertius: revisiting the anatomy. *Clin Anat*. 2007;20(8):946-49.
- [6] Mehta V, Gupta V, Nayyar A, Arora J, Loh H, Suri RK, et al. Accessory muscle belly of peroneus tertius in the leg—a rare anatomical variation with clinical relevance—utility in reconstructions. *Morphologie*. 2011;95(308):23-25.
- [7] Jungers WL, Meldrum DJ, Stern JT. The functional and evolutionary significance of the human peroneus tertius muscle. *J Hum Evol*. 1993;25:377-86.
- [8] Arnold PG, Yugueros P, Hanssen AD. Muscle Xaps in osteomyelitis of the lower extremity: a 20-year account. *Plast Reconstr Surg*. 1999;104(1):107-10.
- [9] Brody PJ, Grumbine N. Peroneus tertius reconstruction for flexible clawtoes associated with cavus deformity: a preliminary report. *J Foot Surg*. 1984;23(5):357-61.
- [10] Dockery GL, Toothaker J, Suppan RJ. A lateral ankle stabilization procedure utilizing the peroneus brevis and peroneus tertius tendons. *J Am Podiatry Assoc*. 1977;67(12):891-94.
- [11] Gaulrapp H, Heimkes B. Peroneus tertius tendon repair following old traumatic rupture of the anterior tibial tendon (casuistry). *Unfallchirurg*. 1997;100(12):979-83.
- [12] Vertullo CJ, Glisson RR, Nunley JA. Torsional strains in the proximal fifth metatarsal: implications for Jones and stress fracture management. *Foot Ankle Int*. 2004;25(9):650-56.

PARTICULARS OF CONTRIBUTORS:

1. Lecturer, Department of Anatomy, Melaka Manipal Medical College (Manipal Campus), Manipal University, Madhav Nagar, Manipal, Karnataka State, India.
2. Additional Professor, Department of Anatomy, Melaka Manipal Medical College (Manipal Campus), Manipal University, Madhav Nagar, Manipal, Karnataka State, India.
3. Professor and Head, Department of Anatomy, Melaka Manipal Medical College (Manipal Campus), Manipal University, Madhav Nagar, Manipal, Karnataka State, India.
4. Associate Professor, Department of Anatomy, Melaka Manipal Medical College (Manipal Campus), Manipal University, Madhav Nagar, Manipal, Karnataka State, India.
5. Lecturer, Department of Anatomy, Melaka Manipal Medical College (Manipal Campus), Manipal University, Madhav Nagar, Manipal, Karnataka State, India.

NAME, ADDRESS, E-MAIL ID OF THE CORRESPONDING AUTHOR:

Dr. Srinivasa Rao Sirasanagandla,
Lecturer, Department of Anatomy, Melaka Manipal Medical College (Manipal Campus),
Manipal University, Madhav Nagar, Manipal, Karnataka-576104, India.
Phone : 9886310652, E-mail: Seenaih.anat@gmail.com

Date of Submission: **Jan 28, 2014**
Date of Peer Review: **May 19, 2014**
Date of Acceptance: **May 25, 2014**
Date of Publishing: **Oct 20, 2014**

FINANCIAL OR OTHER COMPETING INTERESTS: None.