

# Ovarian Juvenile Granulosa Cell Tumour in Childhood: Uncommon Gynecological Malignancy

DHIRAJ B. NIKUMBH<sup>1</sup>, KISHOR H.SURYAWANSHI<sup>2</sup>, ANJALI M.CHITALE<sup>3</sup>, POONAM PAGARE<sup>4</sup>, AKSHAY SURANA<sup>5</sup>

**Keywords:** Granulosa cell tumor, Juvenile, Ovarian tumors

Granulosa cell tumours (GCT) are rare sex cord stromal tumour, encompassing only 2% of all the ovarian tumours [1]. Only 0.1% of all ovarian tumours and 4-5% of GCT occur in children. Juvenile GCT a subtype of ovarian sex cord stromal tumour has a favorable prognosis if diagnosed at an early stage. In view of uncommon gynecological malignancy and to preserve the fertility, histological examination of the resected specimen always warranted with expertise.

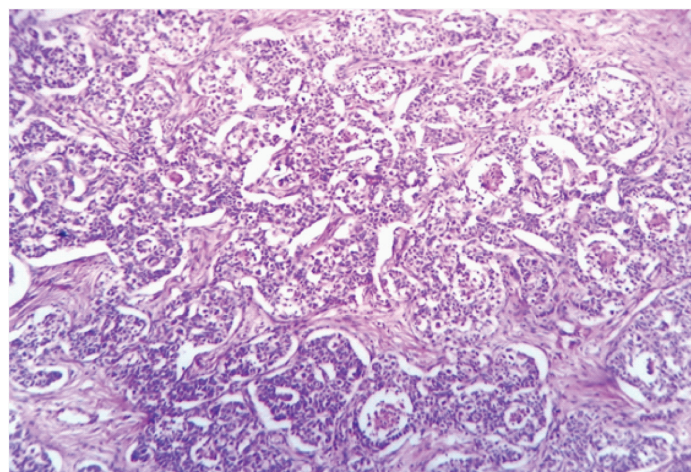
A 2-year-old girl presented to surgical department with chief complains of abdominal distension since one month and abdominal pain on left side since eight days. There was no history of associated nausea and vomiting or vaginal bleeding. Physical examination showed abdominal mass over the left side measuring 8x6 cms. Abdominal USG revealed 10x8 cm well defined solid lesion in umbilical and infraumbilical region. Right sided adnexa were unremarkable. In view of clinical diagnosis of ovarian tumour exploratory laprotomy was done and oophorectomy specimen was sent for histopathology. The specimen measuring 11x9x6cms with attached tiny fimbrial end of tube. External surface was well circumscribed, globular, and smooth with congested blood vessels. On cutting open- well encapsulated homogenous solid grey white tumour mass measuring 9x8x5cm noted replacing the entire ovarian tissue with focal tiny cystic areas. Sections studied shows tumour cells are arranged in sheets, nodules, macro and microfollicles, trabeculae and tubules [Table/Fig-1]. The individual tumour cells are small, round to oval with mild pleomorphic hyperchromic to vesicular nuclei with occasional prominent nucleoli having moderate eosinophilic to vacuolated cytoplasm [Table/Fig-2]. Occasional call exner bodies and tumour cells with grooved nuclei were noted. The tumour cells are separated by fibro-the comatous stroma of spindle cells. Occasional mitosis figures are noted. Immunohistochemically proved as JGCT in view of diffuse immunoreactivity for Calretinin and focally for Inhibin, CD 99 and immunonegative for Alpha fetoprotein

[Table/Fig-3]. Final histopathological diagnosis given as juvenile granulosa cell tumour of left ovary.

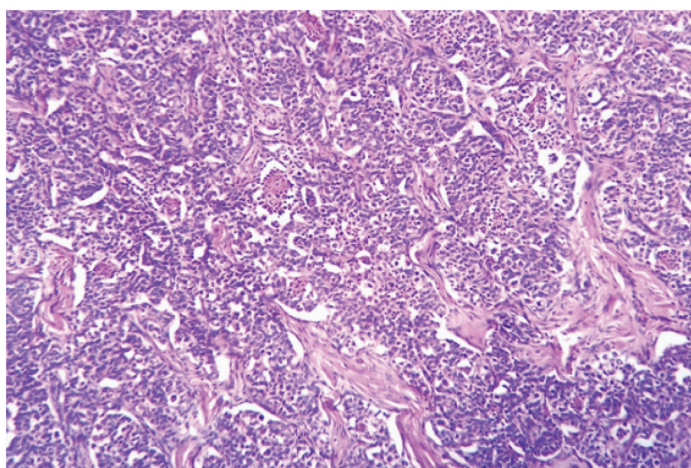
Most of the juvenile GCTs presented with clinical evidence of precocious pseudo puberty including breast development, pubic and axillary hairs, vaginal secretions, irregular uterine bleeding and other secondary sexual characteristics [2]. However, our case was free from such symptoms and her presentation was abdominal pain and distension.

GCT of ovary was first described in 1985 by Rokitansky. Juvenile GCT differs from the adult [3].

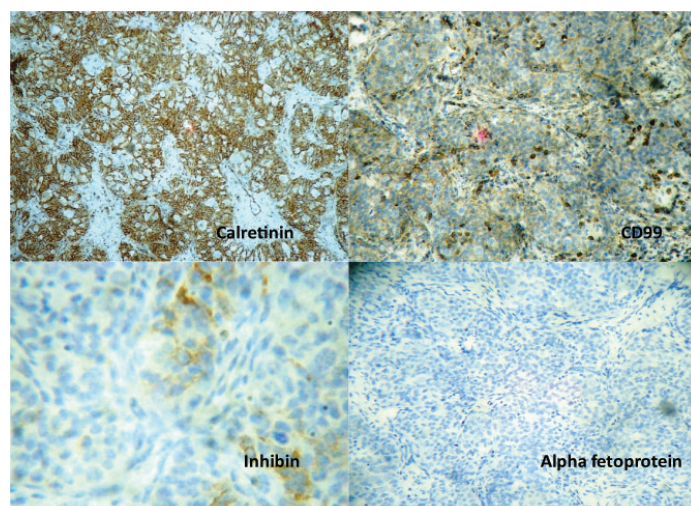
GCT that is seen in older females with respect to the clinical and pathological features as well as biological behaviour [4]. The positive immunohistochemical stain for inhibin, an ovarian glycoprotein is a key diagnostic feature along with calretinin, CD 99 and FOXL2 [5].



**[Table/Fig-2]:** Light microscopy showed well circumscribed tumour with tumour cells arranged in follicular and various patterns (H & E, x100)



**[Table/Fig-1]:** Light microscopy showed well circumscribed tumour with tumour cells arranged follicular and various patterns. (H & E stain)



**[Table/Fig-3]:** The tumour cells show diffuse immunoreactivity for Calretinin with focal positive for inhibin, CD 99 and negative for alpha fetoprotein

Granulosa cell tumour is a rare neoplasm of different behaviour. In addition to its rarity in childhood, the presented case is of particular interest for having abdominal pain and distension only without any secondary sexual characteristics. Histopathological diagnosis requires a great deal of expertise in view of age, treatment modalities and prognosis as this tumour differs from other ovarian tumours. IHC markers may be prognostically helpful in this rare condition.

## REFERENCES

- [1] Moid FY and Jones RV. "Granulosa cell tumour and mucinous cystadenoma arising in a mature cystic teratoma of the ovary: a unique case report and review of literature". *Annals of Diagnostic Pathology*. 2004; 8(2): 96-101.
- [2] Colombo N, Parma G, Zanagnolo V and Insinga A. Management of ovarian stromal cell tumours. *Journal of Clinical Oncology*. 2007;25(10): 2944-51.
- [3] Hashemipour M, Moddah MH, Nazem M, Mahzumi P and Salek M. Granulosa cell tumour in a six year old girl presented with precocious puberty. *Journal of Research in Medical Sciences*. 2010;15 (4): 240-42.
- [4] Maya Y, Chinda JY , Alhaji MA, Nggda HA. Childhood ovarian granulosa cell tumour: a case report and review of literature. *NigerJ Pead*. 2012;39(4) :199-201.
- [5] Young RH. Sex cord stromal tumour of ovary and testis: Their similarities and differences with consideration of selected problems. *Modern Pathology*. 2005;18: 81-98.

### PARTICULARS OF CONTRIBUTORS:

1. Associate Professor, Department of Pathology, JMF's ACPM Medical College and Hospital, Dhule, Maharashtra, India.
2. Professor, Department of Surgery, JMF's ACPM Medical College and Hospital, Dhule, Maharashtra, India.
3. Assistant Professor, Department of Pathology, JMF's Acpm Medical College and Hospital, Dhule, Maharashtra, India.
4. Assistant Professor, Department of Pathology, JMF's ACPM Medical College and Hospital, Dhule, Maharashtra, India.
5. Assistant Lecturer, Department of Pathology, JMF's ACPM Medical College and Hospital, Dhule, Maharashtra, India.

### NAME, ADDRESS, E-MAIL ID OF THE CORRESPONDING AUTHOR:

Dr. Dhiraj B. Nikumbh,  
Associate Professor, Department of Pathology, JMF's ACPM Medical College, Dhule, Maharashtra, India.  
E-mail : drdhirajnikumbh@rediffmail.com

FINANCIAL OR OTHER COMPETING INTERESTS: None.

Date of Submission: **Apr 03, 2014**  
Date of Peer Review: **Jul 03, 2014**  
Date of Acceptance: **Aug 14, 2014**  
Date of Publishing: **Oct 20, 2014**