

Intraocular Metallic Foreign Body: Role of Computed Tomography

SUTHAR POKHRAJ P.¹, PATEL JIGAR J.², MEHTA CHETAN³, PATEL NAROTTAM A.⁴

ABSTRACT

Orbital foreign bodies remain a serious diagnostic problem, despite development of diagnostic imaging techniques. Non-metallic orbital foreign body will not be detected in routine x-ray. Here we are presenting a case of 32-year-old male presented with acute pain in left eye immediately after he had been pounding a metal object with a metal chisel. Following this event patient develop blurring of vision in left eye with tearing. Patient's vision in left eye was found to be hand motion with conjunctiva mildly injected, left corneal central 1 mm Seidel-negative full-thickness laceration and dense traumatic cataract was seen on ocular examination. Dilated fundus examination of left eye was not possible due to traumatic cataract. Vitreous hemorrhage, vitreous detachment and a echogenic foreign body present in posterior segment in B-Scan sonography. Well-defined hyperdense foreign body producing streak artifacts with vitreous hemorrhage was seen in the posterior chamber of left eyeball in CT orbit. The patient was diagnosed with a corneal laceration, traumatic cataract, vitreous hemorrhage and a metallic intraocular foreign body. He was brought to the operating room urgently for corneal laceration repair, pars plana vitrectomy, lensectomy, and removal of the metallic intraocular foreign body done.

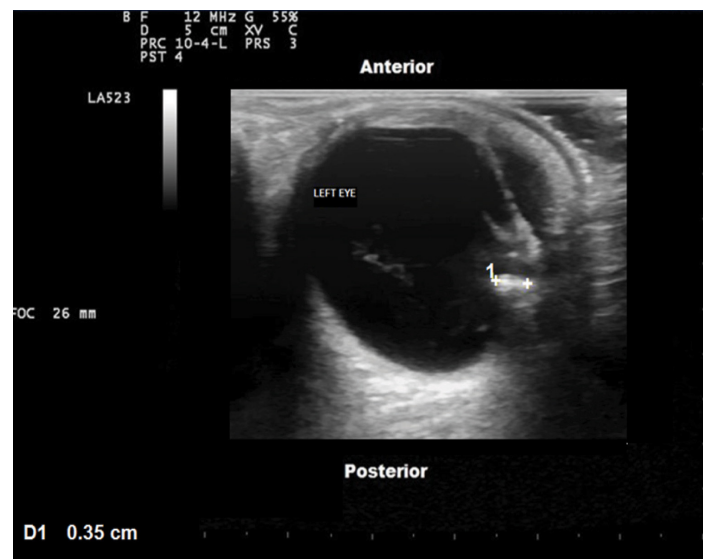
Keywords: CT orbit, Ophthalmology, Ocular foreign body, Ocular ultrasonography

CASE REPORT

A 32-year-old male patient was presented in emergency department of the Shree Shayaji General Hospital and Government Medical College, Baroda with complain of acute pain, tearing and blurring of the vision in left eye immediately after he had been pounding a metal object with a metal chisel. He was not wearing the safety glasses at the time of work and he felt that something strikes to his left eyeball. Patient did not have past history of trauma to eye or previous surgery. On ocular examination, patient's vision in left eye was found to be hand motion and in right eye vision is 6/6. Intraocular pressure in right eye was 17 mmHg and in left eye 16 mmHg. Left eye conjunctiva mildly injected, no sub-conjunctival hemorrhage, left corneal central 1 mm Seidel-negative full-thickness laceration. Anterior chamber formed 1+ cell, no hypopyon or hyphema. Dense traumatic cataract with disruption of anterior lens capsule was seen. No view of the anterior vitreous. Dilated fundus examination of left eye was not possible due to traumatic cataract. Right eye conjunctiva, pupil, anterior chamber, posterior chamber and fundus examination were normal. Provisional diagnosis of the traumatic cataract with corneal laceration was postulated.

On Ultrasonographic B-scan of left eyeball, moving internal echoes in posterior segment of left eyeball representing as vitreous hemorrhage with a dense cataract was seen. A thin echogenic membrane present in posterior segment of left eyeball which shows after movement with movement of eyeball suggestive of vitreous detachment. A 3.5 x 3.7 mm sized echogenic foreign body was present in posterior segment. No evidence of retinal detachment or choroidal hemorrhage. The posterior sclera wall was intact [Table/Fig-1].

On CT (Computed Tomographic) scan of orbit, imaging was performed using 3 mm slice thickness with contiguous plain axial and coronal scan of orbits was done. A 4.2 (T) x 4.4 (CC) x 3.6 (AP) mm sized Well-defined hyperdense foreign body producing streak artifacts was seen in the posterior chamber of left eyeball. Ill defined mildly hyperdense area was seen in the posterior chamber of left eyeball suggestive of vitreous hemorrhage. Lens of left eyeball was appeared small and distorted. Right eyeball, retro-bulbar area, extra-



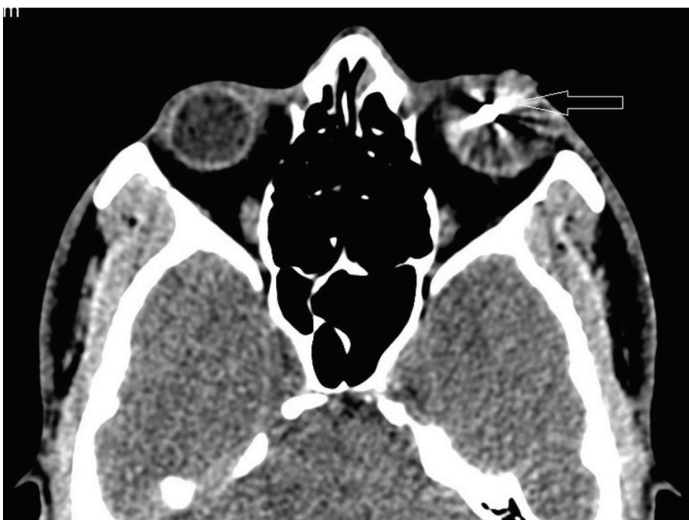
[Table/Fig-1]: Ultrasonographic image of the left eyeball with the high frequency linear probe shows a 3.5 mm sized echogenic metallic foreign body in the posterior segment of the eyeball with vitreous haemorrhage

ocular muscles and bony orbital wall were normal [Table/Fig-2-6].

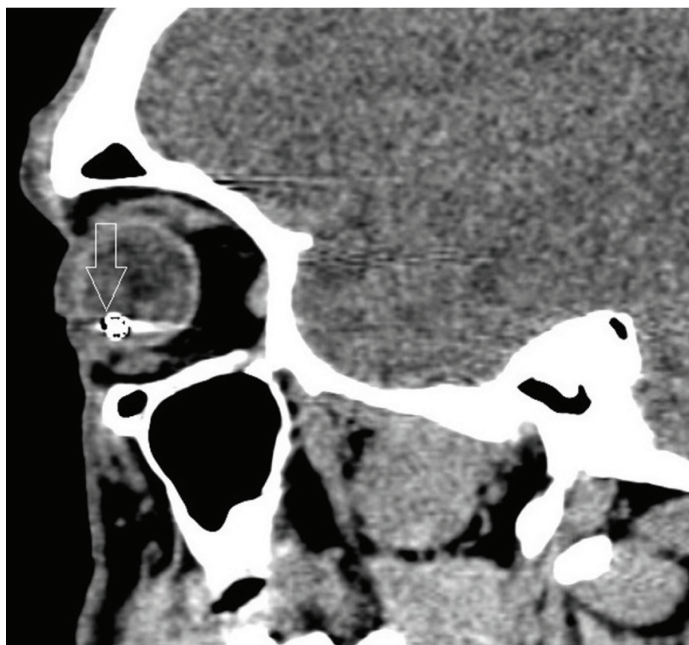
The patient was diagnosed with a corneal laceration, traumatic cataract, vitreous hemorrhage and a metallic intraocular foreign body. He was brought to the operating room urgently for corneal laceration repair, pars plana vitrectomy, lensectomy, and removal of the metallic intraocular foreign body done.

DISCUSSION

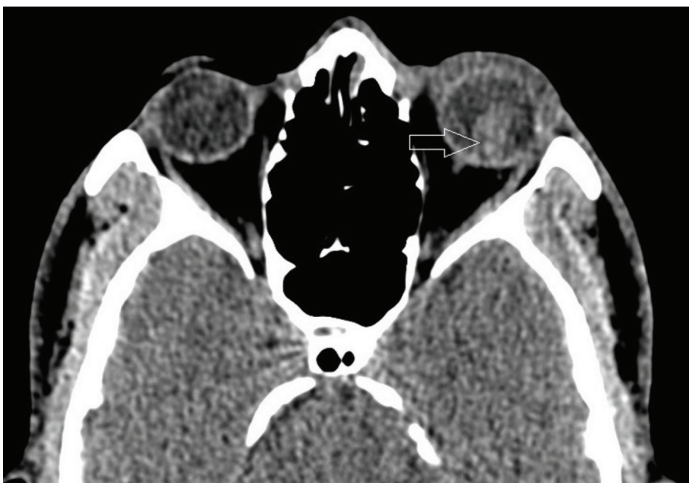Despite development of diagnostic imaging techniques, orbital foreign bodies remain a serious diagnostic problem. Ophthalmologic emergencies account for up to 3% incidence in emergency departments in the United States [1]. The most common cause of intraocular foreign bodies are accidents at work especially in metalworking, traffic accidents and chance shots from hunting rifles [2].



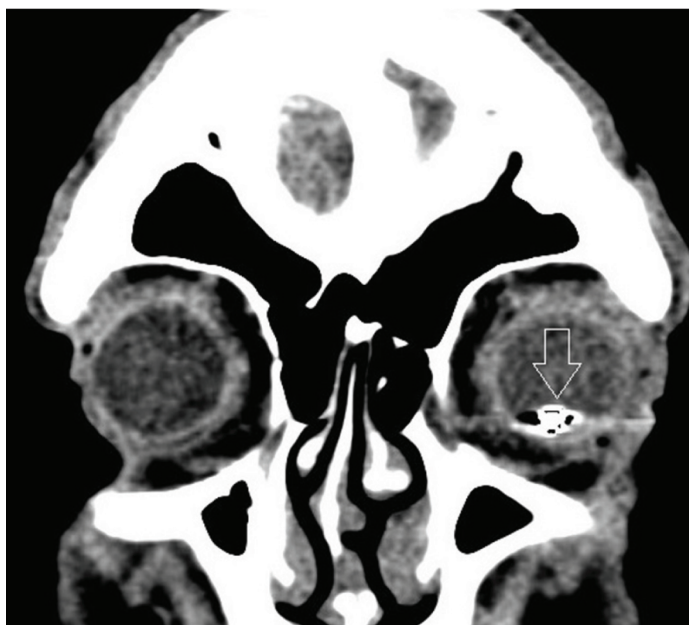[Table/Fig-2]: Axial CT orbit shows a Well-defined hyperdense foreign body producing streak artifacts in the posterior chamber of left eyeball (open white arrow). Right eyeball, retro-bulbar area, extra-ocular muscles and bony orbital wall were normal



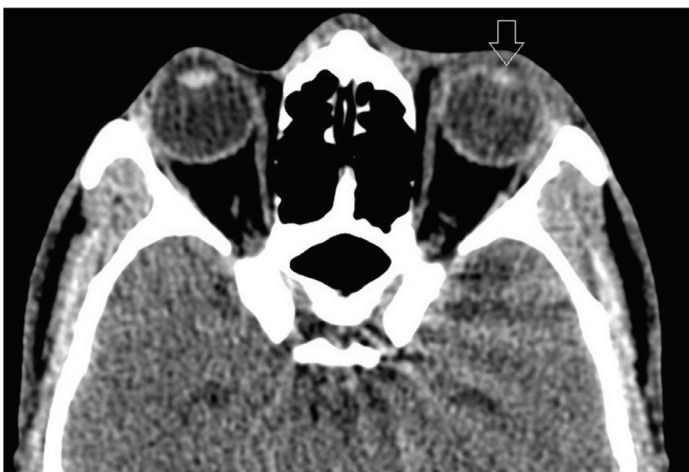[Table/Fig-5]: Sagittal CT orbit shows hyperdense foreign body producing streak artifacts in the posterior chamber of left eyeball (open white arrow)



[Table/Fig-3]: Axial CT orbit shows an ill defined mildly hyperdense area in the posterior chamber of left eyeball representing vitreous hemorrhage. (open white arrow)



[Table/Fig-6]: Coronal CT orbit shows foreign body producing streak artifacts in the posterior chamber of left eyeball (open white arrow)



[Table/Fig-4]: Axial CT orbit shows a distorted small lens of left eyeball (Open white arrow)

Ophthalmic examination, including visual acuity assessment, anterior chamber, posterior chamber and fundus examination must be performed following orbital trauma, and before and after surgical intervention [3]. Penetrating injury to the orbit requires a complex diagnostic process. Conventional X-ray helps in the visualization of radiopaque foreign bodies like metal filings or gunshot pellet [4].

Ultrasonography (USG) can be useful for detection of associated ocular injury like traumatic cataract, vitreous hemorrhage, vitreous detachment etc. But USG does not precisely determine foreign

body location, especially within the posterior part of the orbit [5]. As in our case localization of the posterior segment metallic foreign body by ultrasonography was possible.

With CT or MRI, accurate foreign body localization is possible. MRI is useful for detection of non-metallic foreign bodies [6]. CT is the most useful investigation; it precisely defines the location of the foreign body, its relationships. CT scan is also useful in detection of associated injury like vitreous haemorrhage, bony orbital wall injury or intracranial extension of foreign body [7]. In our case diagnosis of the intraocular metallic foreign body in posterior chamber of left eyeball with vitreous hemorrhage was possible on CT orbit.

However, CT scan is not useful in detection of the nonmetallic foreign body like wood. Dry wood is hypodense and resembles gas in CT scan, which is often found in orbital tissues after injuries [8] with coexistent sinus damage. Angiography is of essential importance when vessel damage is suspected.

Development of the complication will depend upon the entry wound and canal, sharpness of foreign body edge, retainment period, and

impact force. Chronic orbital inflammation, osteomyelitis, thrombotic vasculitis, and diffuse infections in the form of septicopyaemia will develop as complications [9]. The optic, oculomotor, and abducent nerves, the eyeball and retinal artery can be damaged. Thus, foreign body removal is always strongly recommended.

Literature reports recommend surgical removal of each and every foreign body of organic origin. Fulcher emphasized that, in case intraorbital complications should develop, inorganic substances should be removed [10].

The treatment of choice is removal of foreign body with the preservation of oculomotor muscles, eyeball, and the optic nerve functions [11]. Delayed surgical management will hinder identification and removal of the foreign body [12].

A multi-disciplinary surgical team consists of an ophthalmologist, maxillary surgeon and neurosurgeon is required. Inadequate orbital wound management and negligence to perform imaging studies like CT typically result in foreign body retainment.

CONCLUSION

Primary diagnosis of the intraocular foreign body is based on history and clinical examination. However, imaging study like USG, CT and MRI is required to confirmed the diagnosis as well as in difficulty in cases of posteriorly located foreign bodies which are not easily pick up on fundoscopic examination.

TEACHING POINTS

- CT scan of the orbit is useful investigation in detection of metallic foreign body as well as to know the associated complication with it.

- Ultrasonography is useful but some foreign body is missed on it. MRI is useful in diagnosis of non-metallic foreign body.
- Early diagnosis and prompt surgical intervention that allows for the maintenance of visual function.

REFERENCES

- [1] Babineau MR and LD Sanchez. Ophthalmologic procedures in the emergency department. *Emerg Med Clin Am.* 2008; 26.1:17-34.
- [2] Singh V, Kaur A, Agrawal S. An unusual intraorbital foreign body. *Indian J Ophthalmol.* 2004;52(1):64-65.
- [3] Yilmaz T, Erol FS, Yakar H, et al. Delayed trigeminocardiac reflex induced by an intraorbital foreign body. *Case report. Ophthalmologica.* 2006;220(1):65-68.
- [4] Verity DH, Rose GE, Uddin JM, et al. Epibulbar osseous choristoma: benign pathology simulating an intraorbital foreign body. *Orbit.* 2007;26(1):29-32.
- [5] Adesanya OO, Dawkins DM. Intraorbital wooden foreign body (IOFB): mimicking air on CT. *Emerg Radiol.* 2007;14(1):45-49.
- [6] Yamashita K, Noguchi T, Mihara F, et al. An intraorbital wooden foreign body: description of a case and a variety of CT appearances. *Emerg Radiol.* 2007;14(1):41-43.
- [7] Gekeler F, Cruz AA, De Paula SA, Dos Santos AC, Chahud F. Intraconal grease-gun injury: a therapeutic dilemma. *Ophthal Plast Reconstr Surg.* 2005;21(5):393-95.
- [8] Adesanya OO, Dawkins DM. Intraorbital wooden foreign body (IOFB): Mimicking air on CT. *Emerg Radiol.* 2007;14:45-49.
- [9] Bai HQ, L Yao, XX Meng, et al. Visual outcome following intraocular foreign bodies: a retrospective review of 5-year clinical experience. *European Journal of Ophthalmology.* 2011;21(1):98-103.
- [10] Fulcher TP, MC Nab AA, Sullivan TJ. Clinical features and management of introrbital foreign bodies. *Ophthalmology.* 2002;109(3):494-500.
- [11] Baykara M, Dogru M, Ozcetin H, et al. Primary repair and intraocular lens implantation after perforating eye injury. *J Cataract Refract Surg.* 2002;28:1832-35.
- [12] Hefner L, Tegetmeyer H, Sterker I, Wiedemann P. Diabolo-Verletzung mit Lokalisation des Fremdkorpers im Bereich der Orbitaspitze-ein Fallbericht. *Klein Monatsbl Augenheilkd.* 2005;222(11):923-27.

PARTICULARS OF CONTRIBUTORS:

1. Resident, Department of Radiology, S.S.G. Hospital, Medical College, Vadodara, Gujrat, India.
2. MBBS Student, Medical Institute & Research Center, Suamandeeep Vidhyapeeth University, Waghodia, Vadodara, Gujrat, India.
3. Associate Professor, Department of Radiology, S.S.G. Hospital, Medical College, Vadodara, Gujrat, India.
4. Professor, Department of Radiology, S.S.G. Hospital, Medical College, Vadodara, Gujrat, India.

NAME, ADDRESS, E-MAIL ID OF THE CORRESPONDING AUTHOR:

Dr. Pokhraj Prakashchandra Suthar,
5-Durga Nagar Society, Karodiya, Baroda, Gujarat, India.
Phone : +91-9662500537; +91-9825543039, E-mail: pokhraj_suthar@yahoo.co.in

FINANCIAL OR OTHER COMPETING INTERESTS: None.

Date of Submission: **May 12, 2014**
Date of Peer Review: **Aug 17, 2014**
Date of Acceptance: **Sep 04, 2014**
Date of Publishing: **Dec 05, 2014**