

# Access to Abutment Screw in Cement Retained Restorations: A Clinical Tip

MOHIT KHEUR<sup>1</sup>, HUSAIN HARIANAWALA<sup>2</sup>, NIDHI KANTHARIA<sup>3</sup>, TANIA SETHI<sup>4</sup>, SHANTANU JAMBHEKAR<sup>5</sup>

## ABSTRACT

Abutment screw loosening has been reported to be the most common prosthetic complications occurring in screw retained as well as cement retained implant restorations. Different methods to treat this issue have been reported in the literature so far; however these have their own short-comings. Retrieval of an implant restoration intact becomes a clinical challenge when the restoration is cement retained especially with an angulated abutment. This technique is aimed at accurately determining the position of the abutment screw in 3 dimensional relationships using a vacuum formed clear stent. This technique can be used as a viable protocol for management of screw loosening in cement retained implant restorations.

**Keywords:** Abutment screw loosening, Cement retained implant prosthesis, Implant prosthesis retrieval

## CASE REPORT

A 42-year-old male presented with missing 1<sup>st</sup> and 2<sup>nd</sup> molar in the mandibular right quadrant of the jaw. The patient wished to restore the edentulous span with a fixed prosthesis. On radiographic evaluation, adequate height and width of bone was observed and accordingly, two implants of appropriate sizes were placed. Cement retained implant supported restorations were planned as the definitive treatment for the patient.

This article describes the procedure for fabricating a simple customized guided stent for accurately locating the position of the access to the screws of the abutments. The entire procedure for fabricating the stent is explained below:

The abutment was screwed into the implant replica present in the cast and the porcelain fused to metal restoration was placed over the abutment such that the margins of the abutment and the crown were closely adapted [Table/Fig-1&2]. A vacuum formed clear stent (Sof-Tray Sheets, 0.08", Ultradent products, USA) was fabricated over the entire arch with the restoration in place. Care was taken to ensure close adaptation of the stent onto the cast [Table/Fig-3]. The fabricated stent was retrieved. The porcelain fused to metal restoration was removed from the cast and the stent was repositioned back onto the cast such that it seated snugly.

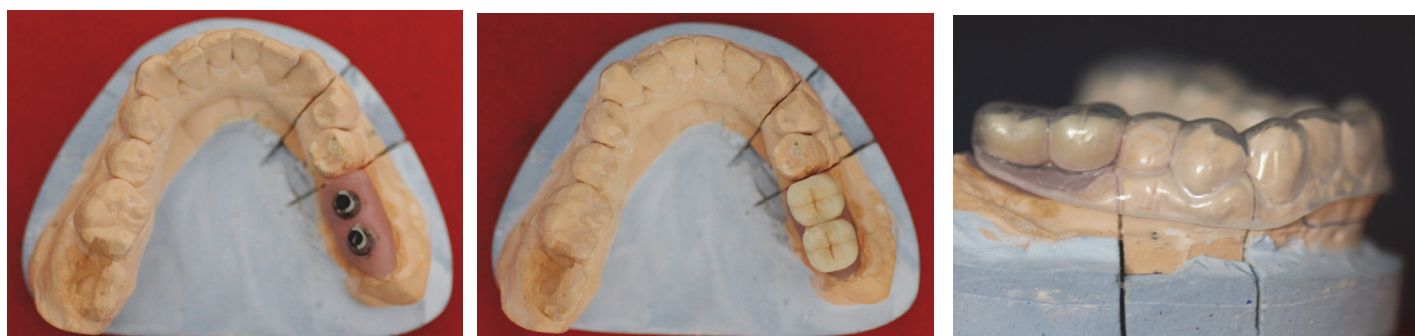The position of access hole of the abutment screw was marked accurately with a marker on the stent. Further, this position was drilled through the stent with the help of a round bur, connecting the access hole on the stent to that of the abutment. A surveyor can also be utilized to accurately mark the location of the access hole to the abutment screw in the bucco-lingual and mesio-distal dimension [Table/Fig-4].

A paralleling pin was positioned passing through the hole drilled in the stent, such that it was placed into the access hole of the abutment. A small plastic tube of a contrasting colour (dimensions 2mm diameter and 4mm length) was positioned over the clear stent such that it followed the direction of the long axis of the paralleling pin placed in the abutment. The alignment of the tube on the stent was easily verified as the stent was fabricated from clear vacuum formed stent material. The difference in the colour of the tube helped in visibly distinguishing and accurately judging the position of the access to the abutment screw. The tube was sealed to the stent with an adhesive cement (Variolink Veneer resin cement, Ivoclar Vivadent AG, Liechtenstein) in the determined angulation [Table/Fig-5].

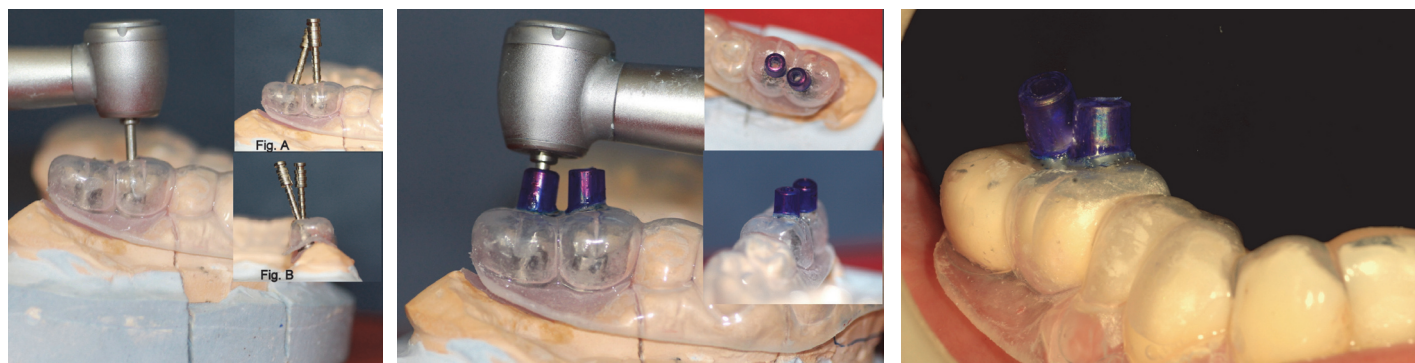
The clear vacuum formed guided stent helped locate the access to abutment screws in a 3-dimensional position precisely [Table/Fig-6].

## DISCUSSION

The advantage of screw retained versus cement retained prosthesis has been a topic of debate over a period of time. However, due to ease in fabrication, improved esthetics, occlusion, passivity, reduced cost of components and easier access in the posterior region, cement retained restorations have gained popularity. Long term clinical data has reported cement retained restorations to be more successful biologically and functionally than screw retained restorations [1]. Various complications with screw retained prosthesis have been reported in the literature which include: fracture of ceramic, compromised esthetics and interference in establishing occlusion due to access screw opening [1,2]. The most commonly encountered prosthetic complication of implant supported restorations is screw loosening [3,4].



[Table/Fig-1]: Working cast with abutments [Table/Fig-2]: The PFM crowns seated on the abutments [Table/Fig-3]: Clear vacuum formed sheet adapted onto the cast



**[Table/Fig-4]:** Orientation of the abutment access path after removal of crowns (Fig A- Buccal view, Fig B- Distal view) **[Table/Fig-5]:** Incorporation of the plastic guide tubes  
**[Table/Fig-6]:** Application of the stent in situ

The importance of retrievability becomes more critical in prosthetic management of the complications [5]. Failure to retrieve cement retained restorations intact requires cutting of the restoration to gain access to abutment screw, which may damage the abutment or destroy the restoration requiring a remake thereafter. Screw loosening in fixed implant prosthesis is attributed to three mechanisms-embedment relaxation, poor component fit and excessive loading of the screw joint. Other factors which may also contribute to screw loosening are iatrogenic errors, torsional relaxation and thermal changes [5].

Previous reports advocated the use of intraoral periapical radiographs and occlusal view photographs of the implant retained restorations for positioning of the access hole. But these do not provide the precise three dimensional position of the access hole to the abutment and are not very useful in cases with angulated abutments [6,7]. Tarlow [8] fabricated a clear stent with a hole for driving the drill into the access of the abutment screw. However, the technique did not help in accurately locating the access. Okamoto and Minagi [9] fabricated a device for removing the cemented superstructure from the implant; however, the technique complicated the fabrication procedure of the crown supported by that abutment. Techniques described in the literature to date for accurately locating the position of the access hole of the abutment under the superstructure are not cost effective and are time consuming measures [10,11].

The method described above of fabricating a guided stent for accessing the abutment hole has several advantages over the previously reported techniques. These include: ease of fabrication, location of 3-dimensional position of access hole, does not require modification of crown or fabrication of a device for the debonding of the crown, can be used in case of missing teeth adjacent to the implant and saves chair side time. Once trained, the in-office staff can fabricate the stent, thereby avoiding additional laboratory expenses.

## CONCLUSION

The technique described in this report provides an easy and cost effective in-office approach for the clinicians to gain predictable access to an abutment screw by attaching a plastic tube to the vacuum formed stent fabricated over the implant retained restoration. This technique takes the guesswork out of the two dimensional measures described earlier in the literature.

## REFERENCES

- [1] Hebel KS, Gajjar RC. Cement-retained versus screw-retained implant restorations: Achieving optimal occlusion and esthetics in implant dentistry. *J Prosthet Dent.* 1997;77:28-35.
- [2] Guichet DL. Load transfer in screw and cement retained implant fixed partial denture design (abstr). *J Prosthet Dent.* 1994;72:631.
- [3] Goodacre CJ, Bernal G, Rungcharassaeng K, Kan JY. Clinical complications with implants and implant prostheses. *J Prosthet Dent.* 2003;90:121-32.
- [4] Gervais MJ, Wilson PR. A rationale for retrievability of fixed, implant-supported prostheses: a complication-based analysis. *Int J Prosthodont.* 2007;20:13-24.
- [5] Nissan J, Narobai D, Gross O, Ghelfan O, Chaushu G. Long-term outcome of cemented versus screw-retained implant-supported partial restorations. *Int J Oral Maxillofac Implants.* 2011;26(5):1102-07.
- [6] Patil PG. A technique for repairing a loosening abutment screw for a cement-retained implant prosthesis. *J Prosthodont.* 2011;20:652-55.
- [7] Patil PG, Patil SP. Occlusal-view photograph of cement-retained implant prosthesis as a permanent guide for access-hole preparation. *J Prosthet Dent.* 2013;109(5):343-44.
- [8] Tarlow JL. A modified technique to locate the abutment screw access opening of a cemented implant-supported restoration. *J Prosthet Dent.* 2012;108:58-59.
- [9] Okamoto M, Minagi S. Technique for removing a cemented superstructure from an implant abutment. *J Prosthet Dent.* 2002;87:241-42.
- [10] Lautensack J, Weber V, Wolfart S. Template to determine the position and angulation of the abutment screw channel for implant supported, cement-retained restorations. *J Prosthet Dent.* 2012;107:134-36.
- [11] Wadhvani C, Chung KH. Simple device for locating the abutment screw position of a cement retained implant restoration. *J Prosthet Dent.* 2013;109:272-74.

### PARTICULARS OF CONTRIBUTORS:

1. Professor and PG Guide, Department of Prosthodontics, M A Rangoonwala College of Dental Sciences and Research Centre, Pune, India.
2. Post Graduate Student, Department of Prosthodontics, M A Rangoonwala College of Dental Sciences and Research Centre, Pune, India.
3. Post Graduate Student, Department of Prosthodontics, M A Rangoonwala College of Dental Sciences and Research Centre, Pune, India.
4. Post Graduate Student, Department of Prosthodontics, M A Rangoonwala College of Dental Sciences and Research Centre, Pune, India.
5. ITI Scholar, Department of Reconstructive Sciences (Division of Prosthodontics), University of Connecticut School of Dental Medicine, Farmington, CT, USA and Lecturer, Department of Prosthodontics, Terna Dental College, Nerul, Navi Mumbai, India.

### NAME, ADDRESS, E-MAIL ID OF THE CORRESPONDING AUTHOR:

Dr. Nidhi Kantharia,  
 Post Graduate Student, Department of Prosthodontics, M A Rangoonwala College of Dental Sciences and Research Centre,  
 Camp, Pune, India.  
 E-mail: nidhikantharia12@gmail.com

**FINANCIAL OR OTHER COMPETING INTERESTS:** None.

Date of Submission: **Sep 08, 2014**  
 Date of Peer Review: **Dec 10, 2014**  
 Date of Acceptance: **Jan 02, 2015**  
 Date of Publishing: **Feb 01, 2015**