

# Treatment Paradox in Musculo-Skeletal Tuberculosis in An Immunocompetent Adult Male; A Case Report from A Tertiary Care Hospital

PRIYANKA CHASKAR<sup>1</sup>, GEETIKA RANA<sup>2</sup>, ANURADHA<sup>3</sup>, NANDINI DUGGAL<sup>4</sup>, JYOTI ARORA<sup>5</sup>

## ABSTRACT

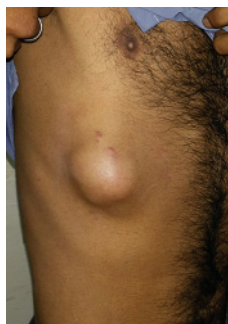Paradoxical reactions like immune reconstitution inflammatory syndrome (IRIS) as seen with patients on retroviral treatment in HIV infection, have also been identified in HIV sero-negative patients with extra pulmonary tuberculosis especially lymph-node tuberculosis. Musculo-skeletal tuberculosis presenting as a cold abscess of the anterior chest wall is a rare entity which poses diagnostic and therapeutic challenge. A 35-year-old immunocompetent male came with complains of painless lump on right side of his chest over 9<sup>th</sup> and 10<sup>th</sup> intercostal space which gradually increased and extended upto 11<sup>th</sup> rib area. Clinically, diagnosis of cold abscess was made and anti-tubercular therapy (ATT) was started. Despite of being on ATT for 3 weeks, patient developed pain and signs of inflammation. Fluid was aspirated and sent for biochemical and microbiological investigations. The aspirated fluid was positive for acid fast bacilli by ZN stain and grew *Mycobacterium tuberculosis* in culture, sensitive to first line ATT. Pyogenic and fungal culture was negative. This case presented as an anterior chest wall cold abscess which deteriorated on initiation of first line ATT, thus creating a suspicion of resistance to ATT which was cleared on ATT susceptibility testing. Hence, this case underlines the possibility of treatment paradoxes seen in immunocompetent musculo-skeletal tuberculosis.

**Keywords:** Anterior chest wall, Cold abscess, Paradox, Tuberculous

## CASE REPORT

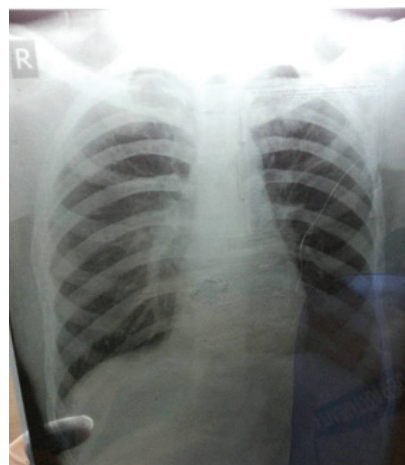
A 35-year-old immunocompetent male came to Out-Patient Department (OPD) of PGIMER & Dr. R.M.L. Hospital, New Delhi, with complaints of painless lump on right side of his chest over 9<sup>th</sup> and 10<sup>th</sup> intercostal space which gradually increased and extended to 11<sup>th</sup> rib area [Table/Fig-1]. Patient also complained of weight loss and loss of appetite over the period of two months. On examination the patient was conscious and oriented to time, place and person. He was febrile (100°F), had pulse rate of 110/min and blood pressure of 90/60 mm Hg. Local examination showed a swelling of 5×5 cm which was soft, movable and not adhered to underlying structures and non fluctuant. There was no history of fever, cough, expectoration or any past history of tuberculosis.

Routine hematological investigations revealed haemoglobin as 12 mg%, total leucocyte count (TLC) was 14,000/ cu mm [polymorphs 80%, lymphocytes 20%] and platelet count of 2.6 lac/cu mm. Erythrocyte sedimentation rate (ESR) was 45 mm in 1<sup>st</sup> hour. Fasting blood sugar was 81mg%. Serum electrolytes, thyroid function tests, liver function tests and kidney function tests were within reference range. Peripheral blood smear showed mild anisopoikilocytosis. Anti-HBsAg, anti-HCV, HIV1 and 2 antibodies were non-reactive.



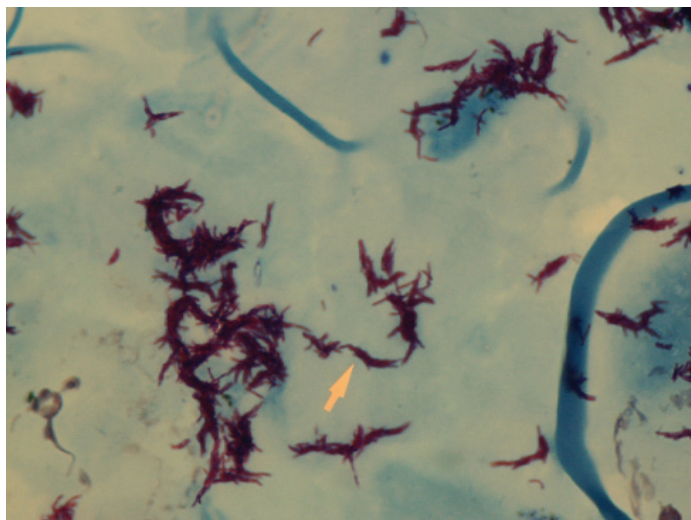
[Table/Fig-1]: Lump on right chest wall over 9<sup>th</sup> and 10<sup>th</sup> intercostal space

X-ray chest was within normal limits [Table/Fig-2]. Ultrasonogram showed well defined hypoechoic lesion with dense internal echoes in anterolateral aspect of thorax. There was minimal fresh fluid with dense echoes. Mantoux test was negative. Clinically, a diagnosis of musculoskeletal tuberculosis was made and the patient was started on ATT.



[Table/Fig-2]: x-ray chest PA view

After three weeks of initiation of ATT, the swelling gradually increased and became tender. Abscess fluid was aspirated and sent for acid fast staining and culture. The Ziehl Neelsen (ZN) stain demonstrated Acid fast bacilli morphologically resembling *Mycobacterium tuberculosis*. Culture on conventional LJ medium and liquid media grew *Mycobacterium tuberculosis* sensitive to first line of antitubercular drugs [Table/Fig-3]. Thus, the clinical diagnosis of cold abscess was confirmed and ATT was continued. NSAIDs were given for symptomatic relief of pain and swelling, which improved patient's condition after two months of ATT.



**[Table/Fig-3]:** Cording as seen in *Mycobacterium tuberculosis* in Liquid culture

## DISCUSSION

Chest wall tuberculosis constitutes 1% to 5% of all cases of musculoskeletal TB, and is most frequently found at the margins of the sternum and rib shafts along with costochondral junctions, costovertebral joints and the vertebrae [1,2]. However, in this case single solitary abscess was seen with no evidence of primary focus in the lungs or any mediastinal lymphadenopathy. This suggests that chest wall involvement was primary in nature.

There have been multiple case reports of primary chest wall tuberculosis responding well to anti-tuberculosis therapy while another study reported immunocompetent patients with extrapulmonary tuberculosis on ATT showing paradoxical reactions [3-6]. Paradoxical reactions are seen in up to 25% of patients with tuberculosis typically in the initial phase of therapy. It is characterized by clinical deterioration or radiological worsening of pre-existing tuberculosis, or the development of new lesions. Mostly, cases of IRIS with Tuberculosis have been associated with patients on antiretroviral treatment in HIV infection [7-9].

Chest wall tuberculosis may occur either by hematogenous or lymphatic dissemination. Hematogenous spread may be associated with activation of a dormant tuberculous focus while lymphatic spread involves direct extension from a lymphadenitis [2]. In the present case, it is hypothesized that the patient developed chest abscess due to dissemination of dormant tuberculous bacilli. Our patient was Mantoux negative which correlates with the activation of suppressor T cells and regulation of TGF-Beta which down-regulates the action of cytotoxic T cells causing Mantoux test to be negative and dissemination of the tubercular bacilli.

Even after three weeks of initiation of ATT, the swelling did not subside but gradually increased and became tender. In this case, it appears that with the advent of treatment, there was activation of the immune system and release of pro-inflammatory cytokines. This response was considered as paradoxical response to ATT and

NSAIDs were started to provide symptomatic relief to the patient. There was suspicion of MDR-TB initially which was ruled out by anti-tubercular susceptibility testing. Thus saving the patient from being labeled as MDR-TB and also being given 2<sup>nd</sup> line drugs.

Management of paradoxical reactions requires essential knowledge. For mild reactions symptomatic treatment is sufficient as seen in our case where patient responded well to NSAIDs. However, severe cases may require the administration of immunomodulators or surgery. Unnecessary testing and treatments should not be attempted in a patient presenting with paradoxical reactions after ATT [9]. Rather this reaction itself should be considered a response to specifically targeted treatment, which leads to release of microbial products after mycobacterial cell disruption. Clinicians need to be aware of the occurrence of paradoxical reactions to ATT and should counsel every patient before initiating ATT [6]. There is insufficient data on IRIS-Tuberculosis in immunocompetent patients. Hence, this rare entity needs to be highlighted to avoid misdiagnosis and mistreatment. Prompt recognition and treatment of such reactions should be done to reduce the associated morbidity and restore patient confidence in treatment.

## CONCLUSION

The case here highlights the need for the physician to consider the possibility of paradoxical reaction in diagnosed cases when patient's condition deteriorates while on treatment. These reactions are easily treatable, thus preventing over-treatment of patients and further creating drug resistant strains.

## REFERENCES

- [1] Singh A, Chatterjee P. Tuberculous osteomyelitis of the scapula masquerading as metastasis. *J Radiol Case Reports* [Internet]. 2009 Jan 4 [cited 2014 Jun 25];3(1). Available from: <http://www.radiologycases.com/index.php/radiologycases/article/view/103>
- [2] Gaude GS, Reyas AK. Tuberculosis of the chest wall without pulmonary involvement. *Lung India Off Organ Indian Chest Soc.* 2008;25(3):135.
- [3] Sharma S, Mahajan RK, Myneedu VP, Sharma BB and Duggal N, "Primary Tubercular Chest Wall Abscess in a Young Immunocompetent Male," *Case Reports in Pulmonology.* vol. 2014, Article ID 357456, 4 pages, 2014. doi:10.1155/2014/357456
- [4] Breen RA, Smith CJ, Bettinson H, Dart S, Bannister B, Johnson MA, et al. Paradoxical reactions during tuberculosis treatment in patients with and without HIV co-infection. *Thorax.* 2004;59:704-07.
- [5] Kuzucu A, Soysal O, Gunen H. The role of surgery in chest wall tuberculosis. *Interact Cardiovasc Thorac Surg.* 2004;3:99-103.
- [6] Chaskar P, Rongpharpi SR, Duggal S, Kalita H, Gur R, Kumar A. Immunologic basis of tuberculosis: disease and the treatment paradox. *Rev Med Microbiol.* 2014;1.
- [7] Sharma SK, Dhooria S, Barwad P, Kadiravan T, Ranjan S, Miglani S, et al. A study of TB-associated immune reconstitution inflammatory syndrome using the consensus case-definition. 2010 [cited 2014 Jun 25]; Available from: <http://imsear.hellis.org/handle/123456789/135522>.
- [8] Meintjes G, Lawn SD, Scano F, Maartens G, French MA, Wordia W, et al. Tuberculosis-associated immune reconstitution inflammatory syndrome: case definitions for use in resource-limited settings. *Lancet Infect Dis.* 2008;8(8):516-23.
- [9] Lawn SD, Bekker LG, Miller RF. Immune reconstitution disease associated with mycobacterial infections in HIV-infected individuals receiving antiretrovirals. *Lancet Infect Dis.* 2005;5:361-73.

### PARTICULARS OF CONTRIBUTORS:

1. Senior Resident, Department of Microbiology, P.G.I.M.E.R & Dr. R.M.L. Hospital, New Delhi, India.
2. Post-Graduate, Department of Microbiology, P.G.I.M.E.R & Dr. R.M.L. Hospital, New Delhi, India.
3. Assistant Professor, Department of Microbiology, P.G.I.M.E.R & Dr. R.M.L. Hospital, New Delhi, India.
4. Consultant and Professor, Department of Microbiology, P.G.I.M.E.R & Dr. R.M.L. Hospital, New Delhi, India.
5. Microbiologist, Department of Microbiology, National Institute of Tuberculosis and Respiratory Diseases, New Delhi, India.

### NAME, ADDRESS, E-MAIL ID OF THE CORRESPONDING AUTHOR:

Dr. Priyanka Chaskar,  
Senior Resident, Department of Microbiology, P.G.I.M.E.R & DR R.M.L. Hospital, New Delhi, India.  
E-mail: [priyanka.chaskar@gmail.com](mailto:priyanka.chaskar@gmail.com)

FINANCIAL OR OTHER COMPETING INTERESTS: None.

Date of Submission: **Aug 24, 2014**  
Date of Peer Review: **Dec 18, 2014**  
Date of Acceptance: **Jan 27, 2015**  
Date of Publishing: **Apr 01, 2015**