

Endobronchial Foreign Body (FB): A Rare Cause of Empyema

ASMITA MEHTA¹, AMIT GUPTA², AZIZ KS³, RAJESH VENKITAKRISHNAN⁴

Keywords: Cough, Left side pleural empyema

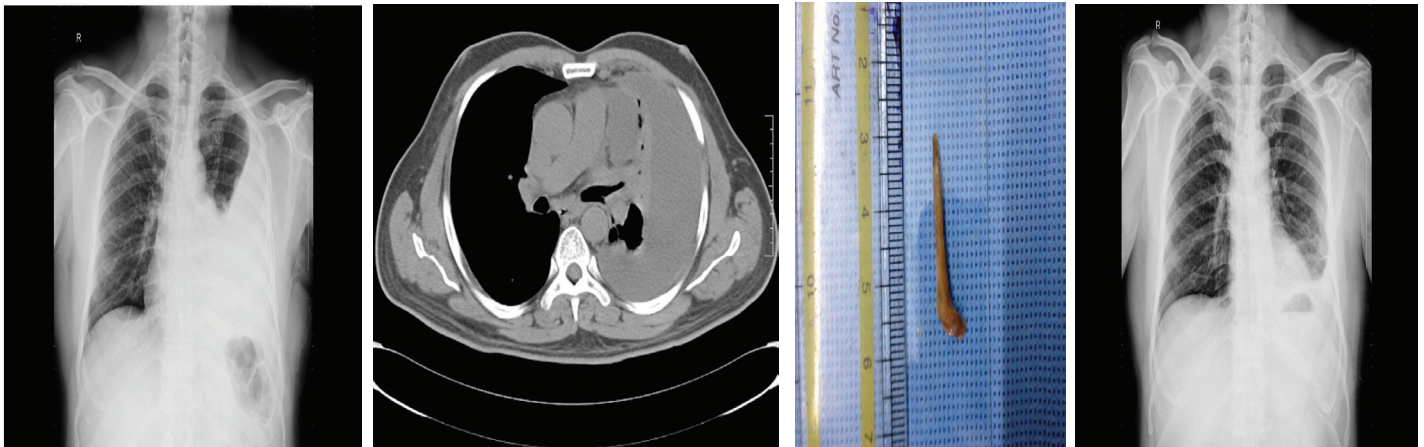
Endobronchial foreign body presenting as pleural effusion is rare. We here by present a case of a 53 years old man who presented with history of left sided empyema. He was found to have endobronchial foreign body. We want to high light that even though uncommon, endobronchial foreign body should be considered in one of the differential diagnosis of empyema.

A 53-year-old gentleman, non smoker- non alcoholic, working as a supervisor in Construction Company, presented with cough, muco-purulent expectoration and on and off low grade fever for last one year. His cough had worsened over the last six months. At the time of presentation, he had purulent foul smelling sputum and high grade fever. He also complained of left sided pleuritic chest pain and breathing difficulty for the last one month. He denied any history of allergy, atopy, hemoptysis, loss of weight or loss of appetite. He received multiple courses of antibiotics in recent past with marginal symptomatic benefit. He did not have any co-morbidity other than diabetes mellitus. His vitals were: blood pressure: 130/80 mm of hg, pulse rate of 88/min, respiratory rate of 20/min, and oxygen saturation on breathing room air 98%. Respiratory system examination was consistent with left moderate pleural effusion. No abnormality was detected in any other system. Tuberculin test (10 T.U.) was negative. His blood investigations were as follows: Hb 13.3 gm/dl, white blood cell counts 12.7×10^3 / ml with 69.6 % neutrophils. His CRP (C-reactive protein) level was elevated (124.06mg/L). His liver function test, renal function test and serum electrolytes were normal. Chest radiograph showed left sided loculated pleural effusion [Table/Fig-1]. CT chest showed left sided moderate pleural effusion with underlying collapsed left lung [Table/Fig-2]. There was mild narrowing of left lower lobe bronchus. Diagnostic pleural fluid (PF) aspiration was done, the results were as follows: (PF) protein 5.9gm/dl, PF lactate dehydro genase 925.9, PF glucose 111.7gm/dl, PF adenosine demainase 20.6 U/l.

Medical thoracoscopy was done. It showed multiple fibrous adhesions involving pleural surfaces and subtle granularity.

Approximately 800 ml of thin pus was aspirated and intercostal chest drain (ICD) was inserted. As his symptoms were persistent fiberoptic bronchoscopy (FOB) was performed prior to removing the ICD. To our surprise, FOB showed a sharp mucoid impacted foreignbody (FB) protruding from left lower lobe basal segments. It was retrieved with bronchoscopy biopsy forceps. Post removal of FB the visualized mucosa looked inflamed. The FB was a bone 3 x 0.5 x 0.5 cm in size [Table/Fig-3] ICD drain was removed the next day of bronchoscopy and patient was discharged on oral antibiotics and inhaled bronchodilators. He has been on regular follow up there after without any re-accumulation of fluid [Table/Fig-4].

Unsuspected aspirated FB is an uncommon cause of unresolved pneumonia or empyema in adult patient. FOB can be the investigation of choice in majority of such patients. A high degree of suspicion is mandatory to avoid the delay in procedure to decrease in the rate of procedure-related complications. Unresolved pneumonia, localised bronchiectasis or localised hyperlucency/air trapping are helpful clinical clues [1]. Chronic lung infections are common cause for bronchiectasis but in present case it led to development of empyema. It is well known that long standing FB aspiration may cause bronchiectasis, necrotising pneumonia or pleural effusion [2]. Empyema following aspiration of a FB is rare scenario. In one study, done over a period of 15 y, it was found that among 1038 patients with bronchiectasis, only eight were found to be due to a long retained FB [1]. It has been observed that removal of FB is sufficient to revert the lung changes to normal and usually it does not warrant any surgical intervention [1,2]. In the present case, the FB was aspirated and found in the left lower lobe bronchus. The aspirated FB commonly ends up on the right side, but few previous studies had shown that FB aspiration into the left main bronchus was also not uncommon [3]. In one published series 28 out of 60 (47%) FB were on left side and in another approximately 80 out of 200 (40%) were found in the left endobronchial tree [3].



[Table/Fig-1]: Chest radiograph showing left sided loculated pleural effusion **[Table/Fig-2]:** CT chest with contrast showing narrowing of left lower lobe bronchus with underlying collapse consolidation and left pleural effusion **[Table/Fig-3]:** Retrieved foreign body- a bone **[Table/Fig-4]:** Follow up x-ray showing clearance of pleural effusion

FB aspiration should be considered as one of the differential of chronic intractable cough and / or unresolved pneumonia. A long-term unrecognised FB aspiration can present with recurrent pneumonia and secondary empyema. There are few reports of foreign body causing empyema and to the best of our knowledge none from India.

REFERENCES

- [1] Zissin R, Shapiro-Feinberg M, Rozenman J, et al. CT findings of the chest in adults with aspirated foreign bodies. *Eur Radiol.* 2001;11:606–11.
- [2] Kane GC, Sloane PJ, McComb B, Chinn B, Gottfried JE. 'Missed' inhaled foreign body in the adult. *Respir Med.* 1994;88:551–54.
- [3] Dong YC, Zhou GW, Bai C, Huang HD, Sun QY, Huang Y, et al. Removal of tracheobronchial foreign bodies in adults using a flexible bronchoscope: experience with 200 cases in China. *Intern Med.* 2012;51:2515–19.

PARTICULARS OF CONTRIBUTORS:

1. Associate Professor, Pulmonary Medicine, Amrita Institute of Medical Sciences, Ponekkara, Kochi, Kerala, India.
2. Senior Resident, Department of Pulmonary Medicine, Amrita Institute of Medical Sciences, Kochi, Kerala, India.
3. Senior Resident, Department of Pulmonary Medicine, Amrita Institute of Medical Sciences, Kochi, Kerala, India.
4. Professor and Head, Department of Pulmonary Medicine, Amrita Institute of Medical Sciences, Kochi, Kerala, India.

NAME, ADDRESS, E-MAIL ID OF THE CORRESPONDING AUTHOR:

Dr. Asmita Mehta,
Clinical Associate Professor, Pulmonary Medicine, Amrita Institute of Medical Sciences,
Ponekkara, Kochi, Kerala-682041, India.
E-mail: asmitamehta@aims.amrita.edu

Date of Submission: **Jan 04, 2015**

Date of Peer Review: **Mar 07, 2015**

Date of Acceptance: **Mar 10, 2015**

Date of Publishing: **Apr 01, 2015**

FINANCIAL OR OTHER COMPETING INTERESTS: None.