

Diagnostic Accuracy on Magnetic Resonance Imaging for the Diagnosis of Osteoarthritis of the Temporomandibular Joint

SHINYA YURA¹, SAORI HARADA², KAZUHIKO KOBAYASHI³

ABSTRACT

Objectives: Osteoarthritis, which is also called degenerative arthritis or degenerative joint disease, is primarily a disease that results from the breakdown and loss of cartilage in joints. The purpose of this study was to investigate the diagnostic accuracy of magnetic resonance images for the diagnosis of osteoarthritis of the temporomandibular joint.

Materials and Methods: Fifty patients (50 joints) with closed locking of the temporomandibular joint were examined with magnetic resonance imaging and then underwent arthroscopic surgery. The agreement of osteoarthritis between magnetic resonance images and arthroscopic findings was studied using

the κ coefficient.

Results: The incidence of osteoarthritis on magnetic resonance images (38%) was significantly lower than that in arthroscopic findings (78%). There was no significant agreement between these two findings ($p=.108$). The κ coefficient was 0.154.

Conclusion: The diagnostic accuracy of magnetic resonance images for osteoarthritis of the temporomandibular joint was low; early osteoarthritis could not be diagnosed from magnetic resonance images. Clinicians should understand that the diagnostic accuracy of osteoarthritis without arthroscopy is not always high.

Keywords: Arthroscopy, Concordance rate, κ Coefficient,

INTRODUCTION

Osteoarthritis (OA), which is also called degenerative arthritis or degenerative joint disease, is primarily a disease that results from the breakdown and loss of cartilage in joints (e.g., knees, hips, wrists). Cartilage, a connective tissue that covers the surfaces of articular joints, is essential for proper joint function because it allows the ends of bones to slide over one another smoothly. OA results from both mechanical and biological events that interfere with the maintenance of healthy cartilage. Eventually, cartilage may be lost, causing the bones in the joint to rub together, and bony spurs may form [1]. Clinicians diagnose OA based on a history of joint symptoms, physical examination, and imaging findings. Radiographic changes may include joint-space narrowing, changes in the bones, and the presence of bony spurs. To better identify the patients at risk and responders to certain treatments, it is of use to define and most importantly classify patients with early osteoarthritis. [2]. Morphological analysis can be semi-quantitative or quantitative Compositional analysis such as delayed gadolinium-enhanced magnetic resonance imaging (MRI) of cartilage and T2 mapping allows quantitative evaluation of tissue ultrastructure and can detect pre-morphological changes of cartilage and other tissues. Contrast-enhanced MRI can accurately assess the true extent of synovial inflammation. Most MRI-based studies so far have focused on knee OA [3,4].

OA occurs also in the temporomandibular joint (TMJ). In the TMJ, T1-weighted MRI is useful for diagnosis of disc position, disc shape, and bone changes [5]. The diagnostic accuracy on fat-saturated T2-weighted MRI for the diagnosis of changes in synovial fluid [6], adhesions in the joint space [7] and perforation of the disc [8] has been reported. MRI can accurately assess most pathologic conditions of TMJ disorders. However, MRI is unsuitable for the detection of cartilage changes because the thickness of TMJ cartilage is thin. Therefore, although OA is a degenerative disease of the cartilage overlying bone, clinicians diagnose OA based on image findings that cannot detect cartilage changes; image findings that demonstrate bone changes suggest OA. In spite of this fact,

the diagnostic accuracy on MRI for the diagnosis of OA of the TMJ has not been evaluated. Arthroscopy is the gold standard for the diagnosis of cartilage changes and the purpose of this study was to investigate the diagnostic accuracy of MRI for the diagnosis of OA using the κ coefficient.

MATERIALS AND METHODS

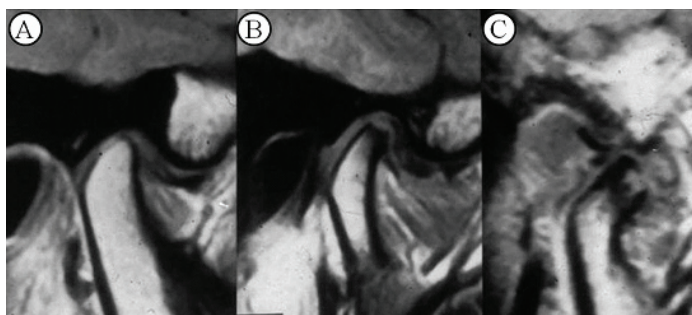
1. Patients

Fifty joints from 50 patients (5 males and 45 females) with closed locking of the TMJ were examined by MRI at Tonami General Hospital, Tonami, Japan from 2004 to 2008. Patient ages ranged from 12 to 71 years, with a median age of 44 years. Locking duration ranged from 3 to 48 months. Maximum mouth opening ranged from 15 to 35mm. Visual analog scale values for joint pain at maximum mouth opening ranged from 25 to 80%. To improve joint pain and trismus, the patients underwent arthroscopic surgery.

2. Evaluation of magnetic resonance images

An MRI scan was obtained using a 1.5-T imager (Signa, General Electric, Hino, Japan) with a dual 3-inch surface coil. In the closed mouth position, T1-weighted images were obtained in both the sagittal and coronal planes (TR 3000 ms/TE 85 ms). The transaction plane was scanned to find the long axis of the condyle, the sagittal plane was calculated to be perpendicular to this long axis with 3-mm section thickness, and the coronal plane was parallel to the long axis with 3-mm section thickness [6-8].

A specialist of MRI diagnoses who was not given any information about the patients evaluated the magnetic resonance images for the presence of bone changes in the glenoid fossa, eminence, and condyle. Types of bone changes [Table/Fig-1] were classified as normal (normal cortical bone without erosion), mild (localized erosions), or severe (extensive erosions with severe absorption and presence of osteophytes) [5]. Normal was classified as a negative finding of bone changes; mild and severe bone changes were positive findings.



[Table/Fig-1]: Types of bone changes on MRI.
 A: Normal (normal cortical bone without erosion)
 B: Mild (localized erosions)
 C: Severe (extensive erosions with severe absorption)

3. Arthroscopic examination

Arthroscopy was performed by the same specialist and assistant within 2 weeks after the MRI, according to the technique of Yura et al., [5,9]. A 1.2-mm diameter ultra-thin arthroscope (DRK-21, Shinko Optical Co., Ltd., Tokyo, Japan) was used in the surgery. Saline solution was injected to widen the upper joint space and then an 18-gauge needle and a trocar for the arthroscope were inserted into the anterior and posterior recesses of the space, respectively. In the upper joint compartment, the structures, including the posterior attachment of the disc, the disc itself, the fibrocartilage of the glenoid fossa and eminence, and the synovium, were examined. Cartilage changes were classified as normal (smooth surface of articular fibrocartilage), mild (localized superficial fibrillation in the articular cartilage), or severe (extensive deep fibrillation and exposure of subchondral bone) [5].

4. Data collection and statistical analysis

The presence and degree of bone changes or cartilage changes were investigated by magnetic resonance images or arthroscopic findings. To clarify the agreement between MRI and arthroscopy, the κ value was calculated for concordance of these two findings. A κ coefficient of 0.21-0.40 was fair agreement, 0.41-0.60 moderate agreement, 0.61-0.80 substantial agreement, and 0.81-1.00 almost perfect agreement.

RESULTS

1. Presence and degree of bone and cartilage changes

The presence and degree of bone and cartilage changes are shown in [Table/Fig-2]. The incidence of OA by magnetic resonance images (38%) was significantly lower (Chi square p value was <.001) than that of arthroscopic findings (78%).

Examination	Degree	Number of joints (%)
Bone changes	Normal	31 (62)
	Mild	9 (18)
	Severe	10 (20)
Cartilage changes	Normal	11 (22)
	Mild	18 (36)
	Severe	21 (42)

[Table/Fig-2]: Presence and degree of bone and cartilage changes

2. Agreement between MRI and arthroscopy

The agreement between MRI (bone changes) and arthroscopy (cartilage changes) is shown in [Table/Fig-3]. The concordance rate of observation frequency between these two findings was 52%. The κ coefficient was 0.154 ($p=0.108$). Twenty two joints had false negative results and two joints had false positive results. The agreement between MRI (bone changes) and arthroscopy (mild cartilage changes) is shown in [Table/Fig-4]. The concordance rate of observation frequency between these two findings was 44.8%. The κ coefficient was 0.033 ($p=0.397$).

	Changes	Arthroscopy (Cartilage changes)		Total
		Positive	Negative	
MRI	Positive	9	22	31
(Bone changes)	Negative	2	17	19
	Total	11	39	50

[Table/Fig-3]: Contingency table of the observation frequency: Agreement between magnetic resonance imaging (MRI) and arthroscopy. Concordance rate of observation frequency=52%, κ coefficient=0.154, 95% confidence interval [-0.078, 0.386], $p=0.108$

	Changes	Arthroscopy (Cartilage changes)		Total
		Positive	Negative	
MRI	Positive	9	14	23
(Bone changes)	Negative	2	4	6
	Total	11	18	29

[Table/Fig-4]: Contingency table of the observation frequency: Agreement between magnetic resonance imaging (MRI) and arthroscopy (mild cartilage changes). Concordance rate of observation frequency=44.8%, κ coefficient= 0.033, 95% confidence interval [-0.284, 0.350], $p=0.397$

	Changes	Arthroscopy (Cartilage changes)		Total
		Positive	Negative	
MRI	Positive	9	9	18
(Bone changes)	Negative	2	12	14
	Total	11	21	32

[Table/Fig-5]: Contingency table of the observation frequency: Agreement between magnetic resonance imaging (MRI) and arthroscopy (severe cartilage changes). Concordance rate of observation frequency=65.6%, κ coefficient= 0.339, 95% confidence interval [0.022, 0.655], $p=0.023$

The agreement between MRI (bone changes) and arthroscopy (severe cartilage changes) is shown in [Table/Fig-5]. The concordance rate of observation frequency between these two findings was 65.6%. The κ coefficient was 0.339 (95% confidence interval: 0.022-0.655, $p=0.023$), which was considered to be fair agreement.

DISCUSSION

In this study, the incidence of OA determined by MRI (38%) was significantly lower than that determined by arthroscopy (78%). The diagnostic accuracy of MRI for OA was low ($\kappa=0.108$); many cartilage changes were not apparent by MRI. 22 joints had false negative results. The diagnostic accuracy of MRI for severe cartilage changes was fair ($\kappa=0.339$), but was lower for mild cartilage changes ($\kappa=0.033$). In advanced OA with cartilage loss apparent on arthroscopy, subchondral bone may be lost, causing the bones in the joint to rub together, and erosion of the cortical bones may form, which is apparent on MRI. In patients with severe cartilage changes, therefore, agreement between MRI and arthroscopy may be fair. Holmlund et al., evaluated the radiographic criteria of OA by a comparison of arthroscopic and tomographic findings [10]. As a result, agreement was found between arthroscopy and tomography regarding the diagnosis of OA in advanced cases. However, the diagnostic accuracy regarding slight changes was lower. Our results using MRI agree with this investigation. These results were taken as a matter of course because it is difficult to distinguish the presence of thin cartilage changes of the TMJ on MRI and tomography. The remarkable fibrillation (more than 2 mm) may be observed on these imaging findings, but it will be an uncommonly specific change with the TMJ.

The definite imaging findings, such as sclerosis, erosion, pseudocysts, and osteophytes, are credible signs in the diagnosis of OA on imaging findings [10]. However, the images could not demonstrate mild cartilage changes as abnormal findings. Therefore, no image findings of OA could be specifically associated with the arthroscopic features of OA. Clinicians should understand that the

diagnostic accuracy of OA without arthroscopy is not always high.

To identify the patients at risk and to perform certain treatments, it is of use to define and classify patients with early OA of the TMJ. However, clinicians must diagnose OA based on imaging findings that cannot detect early OA. Sun et al., reported that the early OA could occur in the bone-cartilage interface, even though the surface articular zone was intact [11]. Therefore, we suggest that the clinical definition of OA should be wider.

CONCLUSION

The diagnostic accuracy of magnetic resonance images for osteoarthritis of the temporomandibular joint was low; early osteoarthritis could not be diagnosed from magnetic resonance images. Clinicians should understand that the diagnostic accuracy of osteoarthritis without arthroscopy is not always high.

DECLARATION

There is no conflict of interest. This is the continuation of the previous studies [6-8] and was presented in 2nd Meeting of IADR Asia Pacific Region, Bangkok.

REFERENCES

- [1] Sniezek JE, Brady TJ, Marks J. Osteoarthritis. Encyclopedia of Public Health. 2002. [Encyclopedia.com. 7 Apr. 2015] [http://www.encyclopedia.com]

- [2] Luyten FP, Denti M, Filardo G, Kon E, Engebretsen L. Definition and classification of early osteoarthritis of the knee. *Knee Surg Sports Traumatol Arthrosc.* 2012;20:401-06. [PMID: 22068268] [doi: 10.1007/s00167-011-1743-2.]
- [3] Hayashi D, Roemer FW, Guermazi A. Osteoarthritis year 2011 in review: imaging in 'OA--a radiologists' perspective. *Osteoarthritis Cartilage.* 2012;20:207-14. [PMID: 22266236]
- [4] Hayashi D, Guermazi A, Roemer FW. MRI of osteoarthritis: the challenges of definition and quantification. *Semin Musculoskelet Radiol.* 2012;16:419-30. [PMID: 23212877] [doi: 10.1055/s-0032-1329895.]
- [5] Yura S, Totsuka Y. Relationship between effectiveness of arthrocentesis under sufficient pressure and conditions of the temporomandibular joint. *J Oral Maxillofac Surg.* 2005;63:225-28. [PMID: 15690292]
- [6] Yura S, Nobata K, Shima T. Hyperintensity signal in the joint space of the temporomandibular joint on fat-saturated T2-weighted magnetic resonance imaging. *Br J Oral Maxillofac Surg.* 2010;48(8):621-23. [PMID: 19942328]
- [7] Yura S, Nobata K, Shima T. Diagnostic accuracy on fat-saturated T2-weighted magnetic resonance imaging for diagnosis of intra-articular adhesions of the temporomandibular joint. *DMFR.* 2012; 41(3):230-33. [PMID: 21723011]
- [8] Yura S, Nobata K, Shima T. Diagnostic accuracy on fat-saturated T2-weighted magnetic resonance imaging for diagnosis of the articular disc perforation of the temporomandibular joint. *Br J Oral Maxillofac Surg.* 2012;50:745-48. [PMID: 21723011]
- [9] Yura S, Totsuka Y, Yoshikawa T, Inoue N. Can arthrocentesis release intra-capsular adhesion? Arthroscopic findings before and after irrigation under sufficient hydraulic pressure. *J Oral Maxillofac Surg.* 2003;61:1253-56. [PMID: 14613079]
- [10] Holmlund A, Hellsing G. Arthroscopy of the temporomandibular joint. A comparative study of arthroscopic and tomographic findings. *Int J Oral Maxillofac Surg.* 1988;17:128-33. [PMID: 3133423]
- [11] Sun L, Ma X, Zou Z. Radiographic findings in osteoarthritis of the temporomandibular joint in relation to its pathologic changes. *Zhonghua Kou Qiang Yi Wue Za Zhi.* 1996;31:326-29. [PMID: 9592283]

PARTICULARS OF CONTRIBUTORS:

1. DMD, Department of Oral and Maxillofacial Surgery, Tonami General Hospital, Japan.
2. DMD, Department of Oral and Maxillofacial Surgery, Tonami General Hospital, Japan.
3. DMD, Department of Oral and Maxillofacial Surgery, Tonami General Hospital, Japan.

NAME, ADDRESS, E-MAIL ID OF THE CORRESPONDING AUTHOR:

Dr. Shinya Yura,
1-61, Shintomi-cho, Tonami-city, Toyama-ken, 939-1395, Japan.
E-mail: yura@p1.coralnet.or.jp

Date of Submission: **Nov 26, 2014**
Date of Peer Review: **Mar 31, 2015**
Date of Acceptance: **Apr 17, 2015**
Date of Publishing: **Jul 01, 2015**

FINANCIAL OR OTHER COMPETING INTERESTS: None.