

Severely Resorbed Edentulous Ridges: A Preventive Prosthodontic Approach – A Case Report

SHALINI KARNAM¹, SWAPNA BASIMI², HARAGOPAL SURAPANENI³, SREERAMULU BASAPOGU⁴, RAMLAL GANTALA⁵

ABSTRACT

As a dentist our main aim should be prevention which not only includes prevention of caries and or periodontal disease but also prevention of residual alveolar bone loss after teeth are extracted. Today with greater stress on preventive measures, the dental profession has expanded this preventive concept into Prosthodontics. Preventive Prosthodontics emphasizes the importance of any procedure that can delay or eliminate the future Prosthodontic problem and stop further progression of oral disease and prevent the loss of remaining tissues. The Residual Ridge Resorption (RRR) is an inevitable consequence of tooth loss and denture wearing. Severe RRR gradually results in increased interarch distance, significant horizontal discrepancy between edentulous ridges, occurrence of flabby displaceable tissues in the denture bearing area and other sequelae. Prosthetic rehabilitation in these patients can be challenging. The conventional complete denture fabrication in such cases may further compound the poor denture bearing ability of the tissues and lead to decreased retention, stability and support which may result in psychological problems and social isolation. This case report emphasizes the importance of preventive concepts in every step of complete denture fabrication to offer a long serviceable prosthesis without any significant complications and compromise.

Keywords: Flabby tissue, Hollow denture, Quadrant transposition teeth arrangement, Residual Ridge Resorption, Thermoplastic sheet

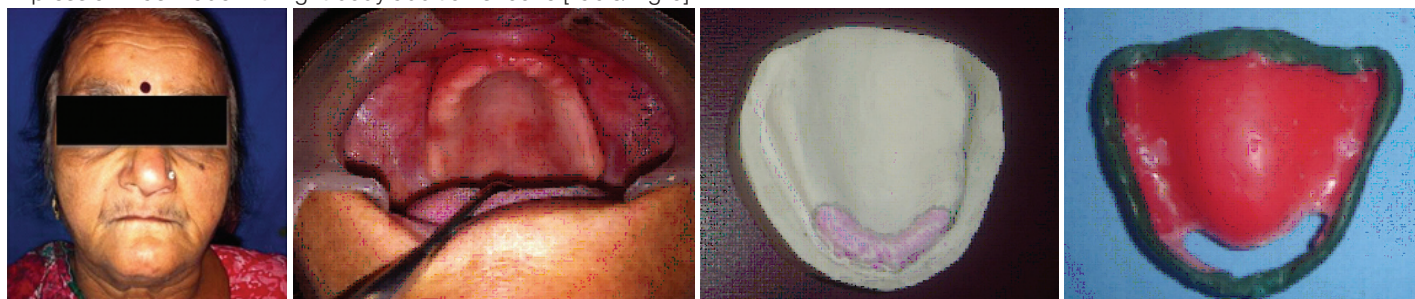
CASE REPORT

A 60-year-old female patient reported with a chief complaint of loose upper and lower complete dentures and desired a new set of dentures. Past dental history revealed that the patient was edentulous and wearing dentures past 7 years [Table/Fig-1]. Intraoral examination revealed severely resorbed edentulous ridges with inflamed flabby tissue in the maxillary anterior region [Table/Fig-2] and also increased interridge distance. The existing dentures were loose and ill-fitting causing lot of discomfort and psychological problems. Patient was advised to discontinue the old dentures and to report after 10 days. Then, the tissues were free from inflammation. Various available treatment options were explained to the patient. These include: Surgical removal of fibrous tissue prior to conventional prosthesis, Implant retained prosthesis and Conventional prosthesis without surgical intervention.

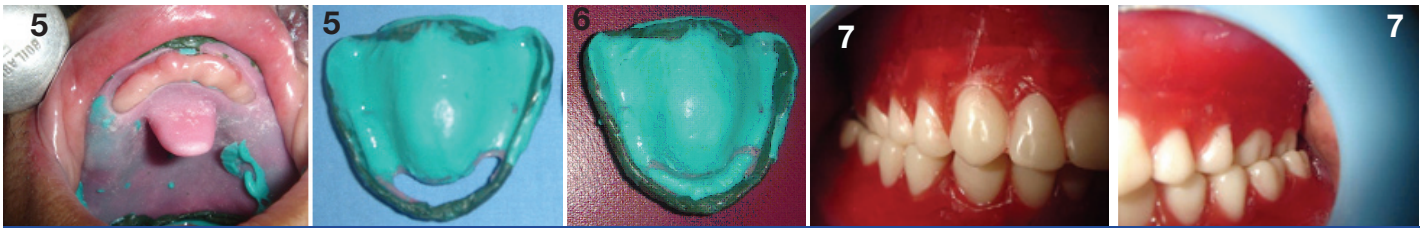
Patient opted for conventional prosthesis without surgery due to reluctance for surgical procedures and financial constraints. Keeping the various challenges associated with the case, treatment plan were modified to follow the principles of Preventive Prosthodontics at every stage of denture fabrication to suit the patient's need. Primary impressions of upper and lower arches were made and cast poured. Area of flabby tissue was marked over the primary cast [Table/Fig-3]. Autopolymerising acrylic resin special trays were fabricated by cutting window in the marked flabby area. Border molding was carried out with low fusing greenstick compound [Table/Fig-4]. Final impression was made with light body addition silicone [Table/Fig-5].

Tray adhesive was applied on the borders of the tray window and is positioned back in the mouth. Light body silicone material was syringed on the flabby ridge through the window and was allowed to set, then removed as a single impression [Table/Fig-6]. Master cast was fabricated and duplicated for the purpose of fabrication of a control denture in a conventional procedure. Over the master cast 2mm thick modeling wax was adapted and processed to produce a heat cure acrylic resin denture base. Wax occlusal rim was fabricated on the denture base. Jaw relations were recorded and the casts were mounted on the articulator. Anterior teeth were arranged according to aesthetic requirements of the patient. Posterior teeth arrangement was altered according to criss-cross ridge relation [Table/Fig-7]. This alteration of teeth arrangement is planned for better stability of dentures as the forces are directed toward the ridge, thus further severity of ridge relation discrepancy may be minimized. Trial dentures were checked in the patient. The land area of the master cast was indexed using a conical bur; the trial denture was sealed to the master cast, duplicated with alginate and cast poured. A template of duplicated cast was made by adapting 0.5mm thermoplastic sheet using vacuum heat pressed machine [Table/Fig-8].

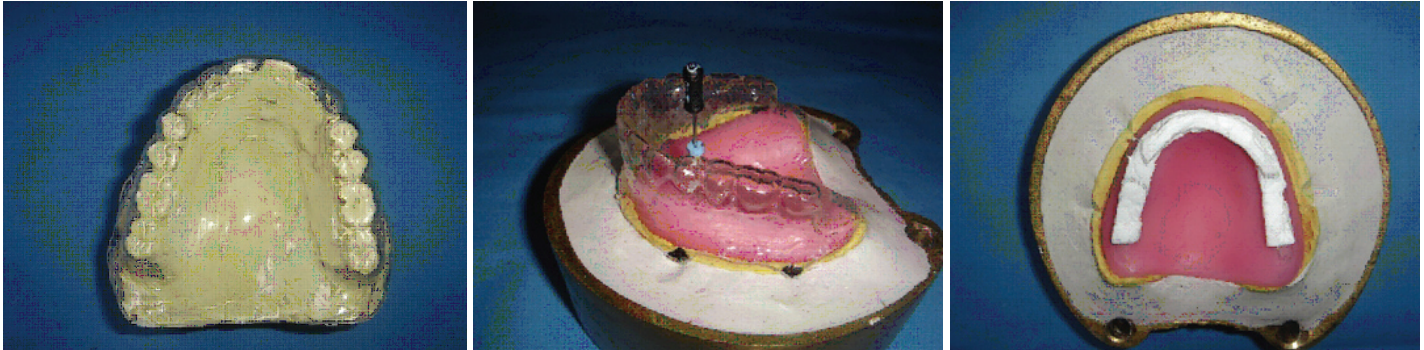
The trial denture was then processed in the standard manner upto wax elimination stage. After dewaxing, heat cure acrylic resin denture base was resealed over the maxillary master cast. A minimum of 2mm to 3mm of space for heat cure acrylic resin material should be provided at the neck of the artificial teeth [Table/Fig-9]. A piece



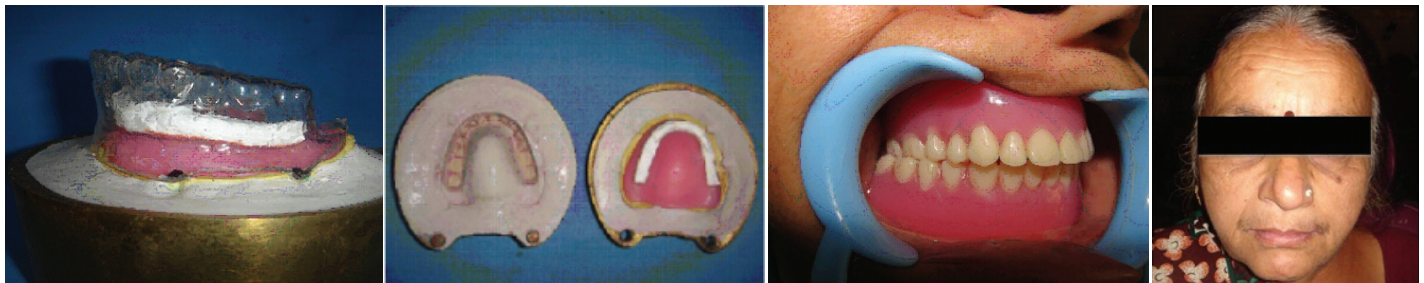
[Table/Fig-1]: Preoperative [Table/Fig-2]: Flabby maxillary anterior ridge. [Table/Fig-3]: Demarcating flabby tissue on primary cast [Table/Fig-4]: Border molded special tray with window in Flabby area



[Table/Fig-5]: Wash Impression with Addition Silicone except in the flabby area **[Table/Fig-6]:** Completed Final impression with syringed addition Silicone in Flabby area
[Table/Fig-7]: Quadrant Transposition of Posterior teeth in Trial denture



[Table/Fig-8]: Clear Template on duplicated trail denture **[Table/Fig-9]:** Endodontic File with rubber stopper to measure available space for the spacer
[Table/Fig-10]: Thermocol fixed on the denture base



[Table/Fig-11]: Verification of spacer dimension using clear template **[Table/Fig-12]:** Flasks ready for final packing **[Table/Fig-13]:** Final dentures inserted in the patient showing criss cross teeth arrangement **[Table/Fig-14]:** Postoperative photograph

of thermocol having a height of 8-9mm in the anterior region and 5-6mm in the posterior region was shaped according to the arch form and fixed over the acrylic denture base with cyanoacrylate [Table/Fig-10]. The spacer dimensions were checked by reseating clear template over the thermocol on the denture base [Table/Fig-11]. After verification, heat polymerizing resin was mixed, packed and processed in usual manner [Table/Fig-12]. Mandibular complete denture is fabricated in conventional procedure. Maxillary control denture 46 gm and light weight denture 32 gm were weighed to demonstrate a significant reduction in the weight. Maxillary light weight and mandibular conventional dentures were inserted and occlusal correction made [Table/Fig-13]. Post insertion instructions and maintenance visits were explained [Table/Fig-14].

DISCUSSION

'It is more important to preserve what already exists than to replace what is missing' as stated by MM Devan has never been challenged or disapproved [1]. According to WHO 1980 the loss of natural teeth and associated alveolar bone is impairment as it is loss of an anatomic body part [2]. In Prosthetic Dentistry the Preventive Prosthodontics play very vital role as it highlights the importance of any procedure that can delay or eliminate future prosthodontic problems [3]. Residual Ridge Resorption (RRR) is a term used for the diminishing quantity and quality of the residual ridge after teeth are removed (GPT-8). RRR is a complex biophysical process and a common occurrence following extraction of teeth. The duration of edentulousness is one of the most important factors contributing to the severity of bone loss. 'Flabby' ridge is a superficial area of mobile hyperplastic soft tissue affecting the edentulous alveolar ridges in long term denture wearers. The flabby ridge may provide poor retention for a denture, but it is better than no ridge. A multitude of

impression techniques have been suggested in the past to record a flabby denture-bearing area including impression plaster and zinc oxide eugenol using silicone material controlled lateral pressure technique, using impression compound combined mucostatic and definitive pressure technique impression using impression wax and poly vinyl silicone impression material Zafrulla Khan's window tech liquid supported denture [4-8].

In severely resorbed ridges with increased interridge distance, the weight of a maxillary denture is often a dislodging factor. Hence, an attempt to reduce the weight of denture is required for better retention. In the past the hollow maxillary complete denture was fabricated using the two flask technique described by Fattore et al., [9]. A clear acrylic template and an endodontic file with rubber stopper were used to visualize the space between the spacer and template [10,11]. Lost salt technique [12] was another method followed in the past. Dough of Dental Plaster-Pumice and Sugar syrup was used as a spacer to fabricate a hollow maxillary complete denture [13]. In all of these techniques salt or silicone putty or plaster pumice sugar dough were used as a spacer, vent holes were made in final denture to remove it and latter sealed with self cure acrylic resin. The junction of heat cure and self cure material is always prone for fluid leakage into the hollow space of denture that eventually increases the weight of denture and invites microbial colonization. Using thermocol as a spacer that can be left in the denture will not compromise denture strength and can avoid potential leakage at the junction of self cure and heat cure acrylic resins as in previous techniques [14,15]. The edentulous maxillary arch undergoes centripetal resorption, and the edentulous mandible undergoes centrifugal resorption resulting in a smaller maxilla than mandible. This causes problems with placing the denture teeth in a position to allow the denture-bearing area to be in line with the occlusal support [16].

CONCLUSION

A special impression technique was followed to record the flabby edentulous ridge in an undisplaced state and rest of the tissues under pressure so that the flabby tissue compression and rebounding are avoided. Teeth were arranged according to resorption pattern of the edentulous jaws, in a criss-cross way to reduce the leverage forces. The heavy maxillary complete denture was avoided by using thermocol as a spacer, which was left in the denture without compromising the strength. This technique is simple to execute following the principles of Preventive Prosthodontics at every step of fabrication. Regular recall visits were maintained and the patient was very comfortable, happy and confident with new dentures.

REFERENCES

- [1] Saba N, Bharathi SS, Gupta P. Overdenture: Preventive Prosthodontics. *Journal of Dental Sciences and Oral Rehabilitation*. 2014;5(1):48-51.
- [2] International Classification of Impairments, Disabilities and Handicaps. WHO 1980.
- [3] Singh R, Singh J, Gambhir RS, Bhinder KS. Preventive aspect of prosthodontics: An overview. *European Journal of Prosthodontics*. 2015;3:10-15.
- [4] Sonawane S, Gangadhar SA, Bhandari J. "Grab the Flab" window impression technique: A case report. *IOSR-Journal of Dental and Medical Sciences*. 2013;11(4):39-42.
- [5] Singh DK, Dable R, Tandon P, Jain A. Prosthodontics rehabilitation of a maxillary fibrous ridge – a case report. *TMU J Dent*. 2014;1(4):164-67.
- [6] Filler WH. Modified impression technique for hyperplastic alveolar ridge. *J Prosthet Dent*. 1971;25(6):609-12.
- [7] Khan Z, Jaggars JH, Shay JS. Impressions of unsupported movable tissues. *J Am Dent Assoc*. 1981;103(4):590-92.
- [8] Walter JD. Composite impression procedures. *J Prosthet Dent*. 1973;30(4):385-90.
- [9] Fattore LD, Fine L, Edmonds DC. The hollow denture: an alternative treatment for atrophic maxillae. *J Prosthet Dent*. 1988;59:514-16.
- [10] O'Sullivan M, Hansen N, Cronin RJ, Cagna DR. The hollow maxillary complete denture A modified technique. *J Prosthet Dent*. 2004;91:591-94.
- [11] Nanda S, Gupta A, Nanda T. Light weight maxillary complete denture: improving retention in resorbed ridges – A Case Report. *Indian Journal of Dental Sciences*. 2013;2(6):75-77.
- [12] Aggarwal H, Jurel SK, Singh RD, Chand P, Kumar P. Lost salt technique for severely resorbed alveolar ridges: An innovative approach. *Contemp Clin Dent*. 2012;3(3):352-55.
- [13] Chaturvedi S, Verma AK, Ali M, Vadhvani P. Hollow Maxillary Denture: A Simplified Approach. *People's Journal of Scientific Research*. 2012;5(2):47-50.
- [14] Shetty V, Gali S, Ravindran S. Light weight maxillary complete denture: A case report using a simplified technique with thermocol. *Journal of Interdisciplinary Dentistry*. 2011;1(1):45-48.
- [15] Kaira LS, Singh R, Jain M, Mishra R. Light weight hollow maxillary complete denture: A case series. *Journal of Orofacial Sciences*. 2012;4(2):143-47.
- [16] DeVan MM. The Nature of the partial denture foundation: Suggestions for its preservation. *J Prosth Dentistry*. 1952;2(2):210-18.

PARTICULARS OF CONTRIBUTORS:

1. Assitant Professor, Department of Prosthodontics, Crown and Bridge, Government Dental College, Hyderabad, Telangana, India.
2. Assitant Professor, Department of Prosthodontics, Crown and Bridge, Government Dental College, Hyderabad, Telangana, India.
3. Assitant Professor, Department of Prosthodontics, Crown and Bridge, Government Dental College, Hyderabad, Telangana, India.
4. Associate Professor, Department of Prosthodontics, Crown and Bridge, Government Dental College, Hyderabad, Telangana, India.
5. Associate Professor, Department of Oral Medicine and Radiology, SVS Institute of Dental Sciences, Mahabubnagar, Telangana, India.

NAME, ADDRESS, E-MAIL ID OF THE CORRESPONDING AUTHOR:

Dr. Ramlal Gantala,
SVS Institute of Dental Sciences, Appanapally, Mahabubnagar - 509001, Telangana, India.
E-mail: dr_ramlal@yahoo.com

Date of Submission: **Jun 30, 2015**
Date of Peer Review: **Aug 12, 2015**
Date of Acceptance: **Sep 05, 2015**
Date of Publishing: **Oct 01, 2015**

FINANCIAL OR OTHER COMPETING INTERESTS: None.