

# Giant Cell Tumour of Soft Tissue in Neck: An Uncommon Tumour in an Uncommon Location

ABHISHEK BANDYOPADHYAY<sup>1</sup>, BINNY KHANDAKAR<sup>2</sup>, SRIPURNA MEDDA<sup>3</sup>, SOUMIT DEY<sup>4</sup>, PRABIR CHANDRA PAUL<sup>5</sup>

## ABSTRACT

Giant cell tumour of soft tissue is an extremely rare tumour. It is thought to be the soft tissue counterpart of giant cell tumours of the bone due to its histological and immunohistochemical resemblances. Almost 80% of these tumours occur in upper and lower extremities; neck is a very rare location. Here we describe a case of primary soft tissue giant cell tumour in right submandibular region. A 35-year-old male patient presented with a swelling in right submandibular area. FNAC suggested a benign soft tissue neoplasm, comprising of spindle cells and multinucleated giant cells. Histopathology of resected specimen showed spindle cell tumour with intricately mixed giant cells, consistent with a primary giant cell tumour of soft tissue. Giant cells were CD 68 positive. Giant cell tumour of soft tissue is benign tumour, though very rarely can show features of malignancy. We present this case for its rarity and morphological overlap with other soft tissue neoplasms containing giant cells.

**Keywords:** CD68, GCT-ST, Head-Neck, Spindle Cells

## CASE REPORT

A 35-year-old male presented to the surgery outpatient department with a superficial, non-tender swelling (~4.5 × 2 cm) for three months in the right submandibular region [Table/Fig-1a]. There was no obvious bony involvement as it was evident clinically that the swelling was freely mobile and not attached to the adjacent mandible. Clinically, a minor salivary gland tumour or lymph nodal mass or a primary soft tissue tumour were considered. Imaging showed a subcutaneous primary soft tissue mass without any bony involvement. The patient was advised a Fine Needle Aspiration Cytology (FNAC) and was sent to the Department of Pathology, Nil Ratan Sircar Medical College and Hospital. The aspirate was blood mixed particulate; slides were stained with Giemsa and Haematoxylin-Eosin stain. FNAC smears were fairly cellular, showing singly lying and loosely cohesive clusters of bland looking spindle cells, along with numerous multinucleated giant cells containing 15-20 nuclei on average, which morphologically resembled osteoclastic giant cells. Cytological atypia, nuclear pleomorphism or mitotic activity were virtually absent in the smears [Table/Fig-1b]. A cytological diagnosis of a giant cell tumour of the soft tissue was given.

The patient was subsequently scheduled for an excision biopsy and the excised specimen was sent for histological diagnosis. Peroperative findings revealed a subcutaneously located circumscribed mass, non-proximity to salivary gland, and no bony involvement. A complete excision of the tumour was done.

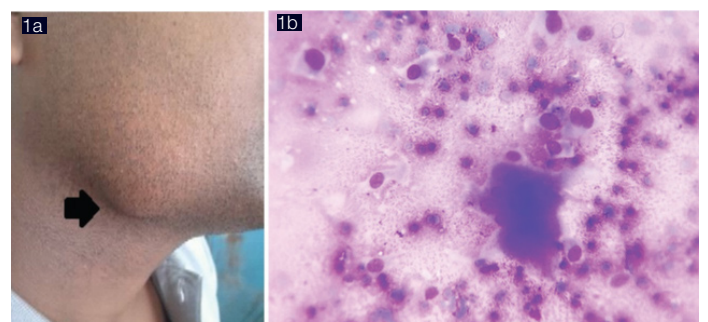
## Gross and Microscopy

The specimen sent comprised of a greyish white soft tissue mass, sent in multiple fragments, measuring together ~3.5X3X1.8 cm in size. The salivary gland was not included in the specimen. The entire specimen sent was processed, embedded in multiple blocks and examined. On microscopy, (Haematoxylin & Eosin stain) the tumour was composed of spindle to oval cells arranged in short fascicles, nodules admixed intricately with numerous, multinucleated giant cells in some areas. The individual spindle cells had vesicular nuclei, inconspicuous nucleoli without any pleomorphism. The giant cells appeared to have similar nuclear features as that of the spindle cells. There was no cytological atypia, cellular pleomorphism or mitotic activity [Table/Fig-2a-c]. No lymph node or salivary gland was identified in any of the sections. Thus, a provisional histological diagnosis of a giant cell tumour of soft tissue

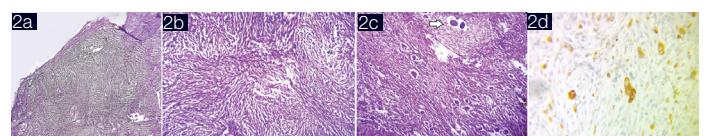
was offered. Further Immunohistochemistry for CD68 and smooth muscle actin (SMA) were done. The multinucleated giant cells displayed strong cytoplasmic CD68 positivity [Table/Fig-2d]; an occasional spindle cells were immune-positive for Smooth muscle actin (SMA). Thus, a final diagnosis of soft tissue giant cell tumour with low malignant potential was established. The patient's recovery was uneventful after surgery. The patient is without recurrence after 2 year postoperatively

## DISCUSSION

Primary giant cell tumours of soft tissue (GCT-ST) are uncommon entity. It was first described by Salm and Sissons in the year 1972, followed by Guccion and Enginger a few years later [1]. They noted some malignant giant cell tumours of soft parts with less atypia and mitotic activity. In 1999, a term "soft tissue giant cell tumours of low malignant potential" was proposed for a group of lesions that



**[Table/Fig-1a,b]:** a) Photograph of the patient showing swelling in the right submandibular region (black arrow) b) Photomicrograph of FNAC smear: Fairly cellular smear showing singly lying and loosely cohesive clusters of bland looking spindle cells and multinucleated giant cells, resembling osteoclastic giant cells, without any cytological atypia, nuclear pleomorphism or mitotic activity. [Giemsa Stain, 400X]



**[Table/Fig-2a-d]:** Photomicrograph of tumor showing spindle to oval tumor cells arranged in vague nodular arrangement (a) Haematoxylin & Eosin stain, 40x, short fascicles, (b) Haematoxylin & Eosin stain, 100x) admixed intricately with numerous, multinucleated giant cells in some areas, (c) Haematoxylin & Eosin stain, 100x, Immunohistochemistry CD68 showing multinucleated giant cells strong cytoplasmic CD68 positivity (d)

represents the benign end of the spectrum of malignant giant cell tumour of soft parts [2]. Though it is a distinct entity, GCT-ST has a similar histological and immunohistochemical profile as giant cell tumour (GCT) of bone, and represent as the soft tissue counter part of GCT bone.

It usually involves upper and lower extremities (>80%), seldom involves trunk and neck [3]. To the best of our knowledge, so far only 13 cases have been described in Indian literature and this is the first one from neck region [Table/Fig-3] [4-10]. These tumours have biologic heterogeneity; primarily behaves as a benign lesion, but

Author	Year	Number of Case	Location
Majhari et al., [4]	2000	1	Paravertebral region
Chand et al., [5]	2006	7	4 from palm and finger 1 each from foot, thigh, anterior abdominal wall
Mardi K et al., [6]	2007	1	Finger
Asotra et al., [7]	2009	1	Thigh
Bhat et al., [8]	2013	1	Ala of nose
Saldanha P et al., [9]	2014	1	Thigh
Paul S et al., [10]	2015	1	Thigh

**[Table/Fig-3]:** Giant Cell Tumour of Soft Reported from India

some reports have stated local recurrence and distant metastasis [3,5,8,11]. Malignant GCTs of soft tissue have been designated as malignant fibrous histiocytomas (giant cell type), there is inadequate data regarding benign GCTs of soft tissue as it is rarely described in literature.

The morphology of GCT-ST closely resembles that of a giant cell tumour of the bone. The histogenesis of these tumours is unclear. Apart from size and location, low and high grade forms were distinguished on microscopic appearance; cytological atypia, pleomorphism, and mitotic figures in the mononuclear cells were considered [11]. GCT-ST occurs in patients of all age groups (mostly in adults, mean 43 years) with no gender predilection [3]. Approximately 80% of all giant cell tumours of soft tissue are located in the extremities. Other tumour locations include abdominal wall, face, neck, and retroperitoneum. Our patient was a young adult male aged 35 years having a soft tissue mass in right submandibular area. As we encountered a rare tumour in an uncommon location, common neoplastic and non-neoplastic lesions affecting that site were considered initially. The list of differentials included soft tissue tumours rich in giant cells, especially giant cell tumour of tendon sheath, nodular fasciitis, benign fibrous histiocytoma, plexiform fibrohistiocytic tumours [7,11]. GCT tendon sheath arise within the tendon sheath is mostly an encapsulated lesion with a typical nodular architecture, lacking the characteristic spindly stromal cells. Nodular fasciitis with osteoclast like giant cells shows fibroblasts arranged in sheets and irregular fascicles. Giant cells are typically located near areas of myxoid degeneration and haemorrhage. In these tumours, Smooth muscle actin (SMA) is expressed only in the spindle cells,

not in the mononuclear and multinucleated histiocytes. Benign fibrous histiocytoma (BFH) another close differential is frequently seen in head and neck area involving dermis. Microscopically, it is composed of spindle cells, histiocytes and haemosiderin laden macrophages and osteoclast like giant cells. The lack of whorling, predominance of mononuclear histiocytic cells showing vesicular, indented nuclei expressing smooth muscle actin, goes against the diagnosis of BFH. Plexiform fibrohistiocytic tumours, located in deeper dermis and subcutis, occur exclusively in children. They are composed of histiocytes and giant cells intermingled with fibroblastic cells; these histiocytes and multinucleated giant cells express CD68, but smooth muscle actin, thus differentiating it from GCT-ST [12]. Giant cell malignant fibrous histiocytoma, as discussed earlier, is believed to be the malignant end of the same disease process; In the present case, we ruled out the possibility of Giant cell malignant fibrous histiocytoma based on the bland morphology of tumour and absence of nuclear atypia, pleomorphism, mitotic activity and necrosis.

## CONCLUSION

Giant cell tumour of soft tissue is a very rare tumour occurring as a primary soft tissue neoplasm. Here we have described a case of GCT-ST involving the head and neck area, which is a very unusual site for the tumour. Combination of cytopathology, histopathology and immunostains for SMA and CD68 confirmed the diagnosis and ruled out other neoplastic and non-neoplastic differentials. Complete excision of the GCT-ST is largely curable. The tumour has mostly a benign clinical course, though local recurrences have been sometimes reported. The present case has been managed with excision and he has been kept in follow up; so far he has remained asymptomatic and doing well, without any recurrence.

## REFERENCES

- [1] Salm R, Sissons HA. Giant-cell tumours of soft tissues. *J Pathol.* 1972;107(1):27-39.
- [2] Folpe AL, Morris RJ, Weiss SW. Soft tissue giant cell tumour of low malignant potential: a proposal for the reclassification of malignant giant cell tumour of soft parts. *Mod Pathol.* 1999;12(9):894-902.
- [3] Oliveira A, Dei Tos AP, Fletcher CDM, Nascimento AG. Primary giant cell tumour of soft tissues: a study of 22 cases. *Am J Surg Pathol.* 2000;24(2):248-56.
- [4] Mazhari NJ, Dhal A, Mandel AK. Giant cell tumour of soft tissue: A case report. *Indian J Pathol Microbiol.* 2000;43:155-56.
- [5] Chand K, Bhardwaj RK, Rappai TJ. Study of 7 cases of giant cell tumour of soft tissue. *MJAFI.* 2006;62:138-40.
- [6] Mardi K, Sharma J. Primary Giant cell tumours of soft parts: Report of a case with fine needle aspiration cytology and histology findings. *J Cytol.* 2007;24:58.
- [7] Asotra S, Sharma S. Giant cell tumour of soft tissue: Cytological diagnosis of a case. *J Cytol.* 2009;26(1):33-35.
- [8] Bhat AV, CV. Soft tissue giant cell tumour of low malignant potential: a rare tumour at a rare site. *J Clin Diagn Res.* 2013;7(12):2960-61.
- [9] Saldanha P, Nazir H. Giant Cell Tumour of Soft Tissue – A Rare Neoplasm. *J Clin Biomed Sci.* 2014;4(3):326-29.
- [10] Paul S, Prabhu A. The rare giant cell tumour of soft tissue – An Indian perspective: A case report with review of the available Indian literature. *International Journal of Biomedical and Advance Research.* 2015;6(07):549-50.
- [11] O'Connell Jx, Wehrli BM, Nielsen GP, Rosenberg AE. Giant cell tumours of soft tissue: A clinicopathologic study of 18 benign and malignant tumours. *Am J Surg Pathol.* 2000;24:386-95.
- [12] Weiss SW, Goldblum JR, editors. *Enzinger and Weiss's Soft tissue tumours.* 5<sup>th</sup> edition. China: Mosby Elsevier; 2008.

### PARTICULARS OF CONTRIBUTORS:

1. Junior Resident III, Department of Pathology, N:L Ratan Sircar, Medical College & Hospital, Kolkata, India.
2. Demonstrator, Department of Pathology, N:L Ratan Sircar, Medical College & Hospital, Kolkata, India.
3. Demonstrator, Department of Pathology, N:L Ratan Sircar, Medical College & Hospital, Kolkata, India.
4. Demonstrator, Department of Pathology, N:L Ratan Sircar, Medical College & Hospital, Kolkata, India.
5. Professor, Department of Pathology, Malda Medical College, Hospital, Malda, India.

### NAME, ADDRESS, E-MAIL ID OF THE CORRESPONDING AUTHOR:

Dr. Binny Khandakar,  
Flat No 6, 18 Deedar Bux Lane, Kolkata-700016, West Bengal, India.  
E-mail: binikhandakar@gmail.com

FINANCIAL OR OTHER COMPETING INTERESTS: None.

Date of Submission: **Jun 26, 2015**  
Date of Peer Review: **Sep 03, 2015**  
Date of Acceptance: **Oct 07, 2015**  
Date of Publishing: **Dec 01, 2015**