

# Collapsing Glomerulopathy: A Single Centre Clinicopathologic Study of Seven Years

KAMAL V. KANODIA<sup>1</sup>, ARUNA V. VANIKAR<sup>2</sup>, RASHMI D. PATEL<sup>3</sup>, KAMLESH S. SUTHAR<sup>4</sup>, LOVELESH K. NIGAM<sup>5</sup>, HIMANSHU V. PATEL<sup>6</sup>, VIVEK KUTE<sup>7</sup>, HARGOVIND L. TRIVEDI<sup>8</sup>

## ABSTRACT

**Introduction:** Collapsing Glomerulopathy (CG) is recognized as distinct pattern of proliferative parenchymal injury with poor response to empirical therapy.

**Aim:** A single center retrospective study was carried out to find out clinicopathological features of idiopathic CG.

**Materials and Methods:** A total of 3335 native renal biopsies were analyzed retrospectively which were performed from 2008 to 2014 with emphasis on clinicopathological correlation and histopathological presentation.

**Results:** Idiopathic CG constituted 0.75% incidence (25 out of 3335 biopsies) of all biopsies, adults constituting major study part with 88%. The duration of the symptoms at the time of biopsy was 34.12±26.09 days and 35±22.91 days respectively

in adults and children. Hypertension was noted in 9(40.9%) and oliguria in 8(36.4%) in adults. Urinalysis revealed microscopic haematuria 12(54.5%) in adults. Nephrotic range proteinuria was reported in 10 (45.5%) adult patients. Glomerular collapse with hyperplasia/ hypertrophy of podocytes was seen in 4.54±3.11 glomeruli. Tubular microcystic dilation was seen in 16(64%) patients. Tubular atrophy involving mild ( $t_1$ ) in 15(60%), moderate ( $t_2$ ) in 4(16%) and severe ( $t_3$ ) in 6(24%) patients. Interstitial fibrosis was mild ( $i_1$ ) in 17(68%), moderate ( $i_2$ ) in 2(8%) and severe ( $i_3$ ) in 6(24%) patients.

**Conclusion:** Idiopathic CG is a morphological pattern of grave podocyte injury with poor prognosis. However, there are chances of remission/ recovery if the tubular atrophy and interstitial fibrosis are of grades  $\leq t_1$ ,  $i_1$

**Keywords:** End stage renal disease, Idiopathic collapsing glomerulopathy, Proteinuria, Podocyte

## INTRODUCTION

Collapsing Glomerulopathy (CG) was first described by Weiss et al., as distinct entity with progressive renal failure and pathological changes characterized by segmental or global capillary collapse and visceral epithelial cell hypertrophy and hyperplasia with hyaline droplets and extensive tubular interstitial inflammation [1]. Clinically CG is more common in black race, in severe nephrotic syndrome, with poor response to empirical therapy and rapidly progresses to End Stage Renal Disease (ESRD) [2,3]. CG was known to be associated with Human Immunodeficiency Virus (HIV) infection. However, later on it was also observed in HIV negative patients and hence the term "idiopathic CG" came in to vogue for which the credit goes to Detwiler et al., who were the first to report CG in HIV negative patients [4]. Most of the studies of CG are published from western countries and few from India and Pakistan [2,3,5-8]. We carried out this single center retrospective study to evaluate clinicopathological features and prognosis of idiopathic CG in our set-up. CG is also known to recur or denovo in renal allograft. Our experience of stem cell therapy in renal transplant patients who were subjected to intrathymic stem cell infusion has showed absence of recurrence of FSGS including CG [9]. Perhaps such a study of stem cell therapy for management of CG will throw more light on future of this entity. Similarly role of plasmapheresis and Rituximab in CG can be explored.

## MATERIALS AND METHODS

A total of 3335 renal biopsies were retrospectively analyzed which were performed in our center from January 2008 to December 2014. Inadequate biopsies were excluded from study. All biopsies were performed by Nephrologist under ultrasound guidance using 18 gauge renal biopsy needle. Two cores of renal tissue were taken, one for light microscopy and one for immunofluorescence (IF) studies. Electron microscopy was not performed due to its non-availability. For light microscopy, 3  $\mu$ m thick paraffin sections

were stained for haematoxylin and eosin (H and E), Periodic Acid Schiff (PAS), Jones'smethaneamine silver (JMS) and Gomori's trichrome (GT) stains. IF sections were stained using anti-human IgG, IgA, IgM, C3, C1q and fibrinogen antisera (MP Biomedical, France). Tests for antinuclear antibody (ANA), anti-double-stranded deoxyribonucleic acid (dsDNA), anti-neutrophil cytoplasmic antibodies {by Enzyme-linked immunosorbent assays (ELISA)}, complement components ( $C_3$  and  $C_4$ ) were recorded. ELISA for HIV and hepatitis B and C viruses' was also carried out.

Demographic evaluation included age, gender, disease duration, hypertension, serum creatinine (mg/dL), 24 hours urinary protein (grams/24 hours) and urinalysis. Hypertension was defined as blood pressure >140/90 mmHg and/or ongoing anti-hypertensive medication. NS was defined as edema, nephrotic range proteinuria (>40 mg/m<sup>2</sup>/h on timed sample, spot albumin to creatinine ratio >2 mg/dl) and hypoalbuminaemia (<2.5 g/dL). Complete remission was defined as urine protein:creatinine ratio (uPCR) of 200 mg/g (o20 mg/mmol) or o1+ of protein on urine dipstick for 3 consecutive days. Partial remission was defined as proteinuria reduction of 50% or greater from the presenting value and absolute uPCR between 200 and 2000 mg/g (20–200 mg/mmol).

CG was diagnosed morphologically by demonstration of at least one glomerulus with segmental or global capillary collapse with hyperplasia and hypertrophy of visceral epithelial cells and severe tubular interstitial injury. Total number of glomeruli with percentage of globally/segmentally collapsed capillary tufts was reported. Associated involvement of tubulointerstitial compartment in the form of active interstitial inflammation/fibrosis, tubular atrophy and microcystic dilatation were reported as percentage of cortical area involved. Tubular atrophy was graded as  $t_1$ ,  $t_2$  and  $t_3$  for  $\leq 25\%$ ,  $\leq 50\%$  and  $> 50\%$  of tubules involved. Similarly interstitial fibrosis was graded as  $i_1$ ,  $i_2$  and  $i_3$  for  $\leq 25\%$ ,  $\leq 50\%$  and  $> 50\%$  of interstitium involved.

## STATISTICAL ANALYSIS

Correlation of histological findings with clinical and biochemical parameters was carried out. Analysis was performed using IBM SPSS 20. Continuous data were expressed as mean  $\pm$  SD and non-continuous data were expressed in percentage and numerical values.

## RESULTS

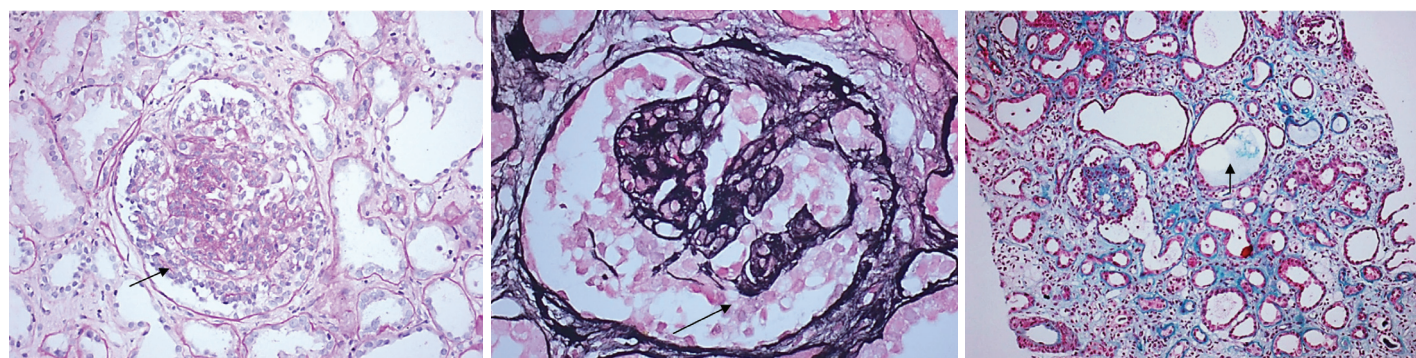
A total of 3335 native renal biopsies performed in seven years were evaluated. Twenty five (0.75%) biopsies qualified for idiopathic CG, out of which 22(88%) belonged to adults and 3(12%) belonged to children ( $\leq 16$  years). Sixteen (64%) out of 25 biopsies belonged to females.

The mean age was  $36.25 \pm 21.25$  years in adults and  $7.33 \pm 3.51$  years in children. The duration of the symptoms at the time of biopsy was  $34.12 \pm 26.09$  days in adults and  $35 \pm 22.91$  days in children. Hypertension was noted in 9(40.9%) and oliguria in 8(36.4%) adult patients and 1 out of 3 children had oliguria. No hypertension was observed in children. Urinalysis revealed microscopic haematuria in 12(54.5%) adults only. Nephrotic range proteinuria was found in adults only with incidence of 45.5%. The mean 24 hours urinary protein excretion was  $7.72 \pm 5.66$  grams in adults and  $2.25 \pm 0.46$  grams in children [Table/Fig-1].

	Adult:22	Children:3
Age (years)	$36.25 \pm 21.25$	$7.33 \pm 3.51$
Male:Female	7:15	2:01
Duration (days)	$34.12 \pm 26.09$	$35 \pm 22.91$
Hypertension	9(40.9%)	0
Haematuria	12(54.5%)	0
Oliguria	8(36.4)	1(33.3)
Serum creatinine (mg/dl)	$3.93 \pm 3.06$	$2.46 \pm 1.3$
24Hours protein (gm/day)	$7.72 \pm 5.66$	$2.25 \pm 0.46$
Nephrotic syndrome	10(45.5)	0

[Table/Fig-1]: Demographics with clinical features

The renal biopsies were adequate with mean number of glomeruli being  $13.92 \pm 5.46$  and mean  $4.54 \pm 3.11$  glomeruli revealed global/segmental capillary collapse [Table/Fig-2a&b]. There was associated global sclerosis in  $7.6 \pm 3.72$  (30%) glomeruli and segmental sclerosis in  $5 \pm 3.01$  (20%) glomeruli. Tubular microcystic dilatation was seen in 16(64%) biopsies [Table/Fig-2c]. Tubular atrophy was graded as  $t_1$  in 15(60%),  $t_2$  in 4(16%) and  $t_3$  in 6(24%) biopsies. Interstitial fibrosis was noted as  $i_1$  in 17(68%),  $i_2$  in 2(8%) and  $i_3$  in 6(24%) biopsies. Interstitial mononuclear cellular infiltration was seen in all cases [Table/Fig-3]. Immunofluorescence (IF) studies showed non-specific mesangial deposits of IgM $\pm$  C3 in All biopsies.



[Table/Fig-2]: (a) Glomerular collapse with hyperplasia/ hypertrophy of podocytes (P). (b) Glomerular collapse with hyperplasia/ hypertrophy of podocytes. (P) (Jones's silver methenamine, x 400). (c) Microcystic dilatation of tubules (T) (Gomori's trichrome (GMT) x 100).

Number of total Glomeruli	$13.92 \pm 5.46$
Number of Collapsed glomeruli	$4.54 \pm 3.11$
Globally Sclerosed glomeruli	$7.6 \pm 3.72$
Segmentally sclerosed glomeruli	$5 \pm 3.01$
<b>Interstitial Fibrosis</b>	
Severe $>50\%$ - $i_3$	6(24%)
Moderate 26-50% - $i_2$	2(8%)
Mild $\leq 25\%$ - $i_1$	17(68%)
<b>Tubular Atrophy</b>	
Severe $>50\%$ - $t_3$	6(24%)
Moderate 26-50% - $t_2$	4(16%)
Mild $\leq 25\%$ - $t_1$	15(60%)
Microcystic dilatation of tubules	16(64%)

[Table/Fig-3]: Histopathological findings of renal biopsies

Ten (40%) patients were lost for follow-up. In remaining 15 (60%) patients with mean follow-up of  $19.7 \pm 14.6$  months, all are on steroids and 7 out of 15 also received calcineurin inhibitors (cyclosporine three patients and Tacrolimus four patients) in addition. Nine (60%) patients have progressed to end stage renal disease and are on maintenance haemodialysis. Histology revealed chronic changes of tubular atrophy and interstitial fibrosis of grade  $t_3 i_3$  in 4,  $t_2 i_2$  in 2 and  $t_2 i_1$  in 3 biopsies. Five (33.3%) patients with chronic changes of grade  $t_1 i_1$  have maintained stable renal function with mean SCr of  $2.6 \pm 2.05$  mg/dL. Proteinuria declined in five patients with complete remission in two and partial remission in three patients.

## DISCUSSION

CG is now a well-recognized distinct morphological pattern of proliferative parenchymal injury which is a harbinger of poor response to empirical therapy [10]. CG was reported to be associated with human immunodeficiency virus associated nephropathy (HIVAN) [11]. Detwiler et al., had reported CG in HIV negative patients [4]. A recently proposed taxonomy for podocytopathies classifies CG apart from FSGS and recognizes three major categories of CG; idiopathic, genetic and secondary or reactive [12]. Black race and COQ2 mutation with mitochondrial dysfunction suggest genetic susceptibility [10]. In addition to HIV infection, parvovirus B19 infection and treatment with Pamidronate are also known to cause CG.

In our study the incidence of CG was 0.75% which was similar to findings of other studies [4,6,8,13,14]. Female predominance was found in our studies similar to report by Laurinavicius [13]. However Ahuja et al., have reported male predominance [6]. The mean duration of biopsy in our study was  $35 \pm 22.91$  days which was comparatively lower than other studies [6,13,15]. Other clinical features like hypertension and oliguria were also comparable with findings of Ahuja et al., [6]. We have observed

microscopic haematuria in 12 (54.5%) adults. However, Ahuja et al., have reported haematuria in all their cases [6].

We tried to compare adult CG with childhood onset CG. However since the number of children affected by CG was small (three) in comparison to adults with CG, the comparative evaluation was abandoned.

On histology evaluation, our study revealed about 18% glomeruli showed partial or global collapsed glomerular tufts. Microcytic dilatation was comparably more in our study than study of Ahuja et al., [6].

Remission was observed in 6 patients who presented with serum creatinine < 2mg/dl and chronic changes of tubular atrophy/interstitial fibrosis of grade  $t_1, i_1$ , whereas with more intense injury and higher serum creatinine, there was limited recovery. Similar observation was also reported by other authors [3, 13, 16]. However, ESRD was not correlated with age and gender.

The pathogenesis of CG involves visceral cell injury leading to cell cycle dysregulation and proliferative phenotype. Loss of maturity markers like podocalyxin, synaptopodin and loss of WT1 along with re-expression of early podocyte marker (PAX2 and cytokeratin) along with proliferation marker KI-67, indicates dysregulation of phenotype.

## LIMITATION

We could not compare adult CG with CG in children due to unequal data and small sample size of pediatric biopsies. However interesting observation of CG in children emerges that CG was encountered in this age group inspite of absence of haematuria and hypertension. We could not correlate the histology with extent of hypertension and serum creatinine. Perhaps studies correlating renal damage in terms of CG with interstitial fibrosis, tubular atrophy and clinical extent of hypertension and serum creatinine may prove useful. The present study has main focus on histology findings, future studies including clinical management will be helpful.

## CONCLUSION

Idiopathic CG is a morphological pattern of grave podocyte injury with poor prognosis. However there are chances of remission/recovery if the tubular atrophy and interstitial fibrosis are of grades  $\leq t_1, i_1$ .

## ACKNOWLEDGMENTS

We acknowledge Miss Yogita for supporting us in computer work.

## REFERENCES

- [1] Weiss MA, Daquiaoag E, Margolin EG, Pollak VE. Nephrotic syndrome, progressive irreversible renal failure, and glomerular "collapse": a new clinicopathologic entity? *Am J Kidney Dis.* 1986;7:20-28.
- [2] Alqaqumi M1, Soos TJ, Barisoni L, Nelson PJ. Collapsing glomerulopathy. *J Am Soc Nephrol.* 2006;17(10):2854-63.
- [3] Schwimmer JA, Markowitz GS, Valeri A, Appel GB. Collapsing glomerulopathy. *Semin Nephrol.* 2003;23(2):209-18.
- [4] Detwiler RK, Falk RJ, Hogan SL, Jennette JC. Collapsing glomerulopathy: a clinically and pathologically distinct variant of focal segmental glomerulosclerosis. *Kidney Int.* 1994;45:1416-24.
- [5] Stokes MB, Valeri AM, Markowitz GS, D'Agati VD. Cellular focal segmental glomerulosclerosis: Clinical and pathologic features. *Kidney Int.* 2006;70(10):1783-92.
- [6] Ahuja A, Gupta R, Sharma A, Bagga A, Bhowmik DM, Agarwal SK, et al. Idiopathic collapsing glomerulopathy: A clinicopathologic analysis of 30 cases. *Indian J Nephrol.* 2014;24(4):239-42.
- [7] Nada R, Kharbanda JK, Bharti A, Minz RW, Sakhuja V, Joshi K. Primary focal segmental glomerulosclerosis in adults: is the Indian cohort different? *Nephrol Dial Transplant.* 2009;24(12):3701-07.
- [8] Mubarak M, Kazi JI. Collapsing FSGS: A clinicopathologic study of 10 cases from Pakistan. *Clin Exp Nephrol.* 2010;14:222-27.
- [9] Vanikar AV, Trivedi HL, Shah PR, et al. Single-center experience on renal transplantation in primary focal and segmental glomerulosclerosis using haematopoietic stem cell transplantation in thymus, bone marrow, portal and peripheral circulation. *Saudi J Kidney Dis Transpl.* 2013;24(1):15-21.
- [10] Alqaqumi M, Barisoni L. Current Views on Collapsing Glomerulopathy. *J Am Soc Nephrol.* 2008;19(7):1276-81.
- [11] D'Agati V, Appel GB. Renal pathology of human immunodeficiency virus infection. *Semin Nephrol.* 1998;18(4):406-21.
- [12] Barisoni L, Schnaper HW, Kopp JB. A proposed taxonomy for the podocytopathies: a reassessment of the primary nephrotic diseases. *Clin J Am Soc Nephrol.* 2007;2(3):529-42.
- [13] Laurinavicius A, Hurwitz S, Rennke HG. Collapsing glomerulopathy in HIV and non-HIV patients: a clinicopathological and follow-up study. *Kidney Int.* 1999;56(6):2203-13.
- [14] Gulati A, Sharma A, Hari P, Dinda AK, Bagga A. Idiopathic collapsing glomerulopathy in children. *Clin Exp Nephrol.* 2008;12:348-53.
- [15] Valeri A, Barisoni L, Appel GB, Seigle R, D'Agati V. Idiopathic collapsing focal segmental glomerulosclerosis: A clinicopathologic study. *Kidney Int.* 1996;50:1734-46.
- [16] Moudgil A, Nast CC, Bagga A, et al. Association of parvovirus B19 infection with idiopathic collapsing glomerulopathy. *Kidney Int.* 2001;59:2126-33.

### PARTICULARS OF CONTRIBUTORS:

1. Professor, Department of Pathology, Lab Medicine, Transfusion Services and Immunohematology, G.R. Doshi and K.M. Mehta Institute of Kidney Diseases & Research Centre and Dr. H.L. Trivedi Institute of Transplantation Sciences, Civil Hospital Campus, Asarwa, Ahmedabad, India.
2. Professor and Head, Department of Pathology, Laboratory Medicine, Transfusion Services and Immunohematology, G.R. Doshi and K.M. Mehta Institute of Kidney Diseases & Research Centre and Dr. H.L. Trivedi Institute of Transplantation Sciences, Civil Hospital Campus, Asarwa, Ahmedabad, India.
3. Professor, Department of Pathology, Laboratory Medicine, Transfusion Services and Immunohematology, G.R. Doshi and K.M. Mehta Institute of Kidney Diseases & Research Centre and Dr. H.L. Trivedi Institute of Transplantation Sciences, Civil Hospital Campus, Asarwa, Ahmedabad, India.
4. Associate Professor, Department of Pathology, Laboratory Medicine, Transfusion Services and Immunohematology, G.R. Doshi and K.M. Mehta Institute of Kidney Diseases & Research Centre and Dr. H.L. Trivedi Institute of Transplantation Sciences, Civil Hospital Campus, Asarwa, Ahmedabad, India.
5. Associate Professor, Department of Pathology, Laboratory Medicine, Transfusion Services and Immunohematology, G.R. Doshi and K.M. Mehta Institute of Kidney Diseases & Research Centre and Dr. H.L. Trivedi Institute of Transplantation Sciences, Civil Hospital Campus, Asarwa, Ahmedabad, India.
6. Professor, Department of Nephrology and Transplantation, G.R. Doshi and K.M. Mehta Institute of Kidney Diseases & Research Centre and Dr. H.L. Trivedi Institute of Transplantation Sciences, Civil Hospital Campus, Asarwa, Ahmedabad, India.
7. Associate Professor, Department of Nephrology and Transplantation, G.R. Doshi and K.M. Mehta Institute of Kidney Diseases & Research Centre and Dr. H.L. Trivedi Institute of Transplantation Sciences, Civil Hospital Campus, Asarwa, Ahmedabad, India.
8. Professor, Department of Nephrology and Transplantation Medicine and Director, G.R. Doshi and K.M. Mehta Institute of Kidney Diseases & Research Centre and Dr. H.L. Trivedi Institute of Transplantation Sciences, Civil Hospital Campus, Asarwa, Ahmedabad, India.

### NAME, ADDRESS, E-MAIL ID OF THE CORRESPONDING AUTHOR:

Dr. Kamal V. Kanodia,  
Professor, Department of Pathology, Lab Medicine, Transfusion Services and Immunohematology,  
G.R. Doshi and K.M. Mehta Institute of Kidney Diseases & Research, Centre and Dr. H.L.  
Trivedi Institute of Transplantation Sciences, Civil Hospital Campus, Asarwa, Ahmedabad, India.  
E-mail: kamalkanodia@yahoo.com

Date of Submission: **Oct 13, 2015**  
Date of Peer Review: **Jan 26, 2016**  
Date of Acceptance: **Feb 29, 2016**  
Date of Publishing: **Apr 01, 2016**

FINANCIAL OR OTHER COMPETING INTERESTS: None.