

# A Case of Recto-Vesico-Cutaneous Fistula Following Perineal Injury by Wild Boar

PRAVIN D. BHINGARE<sup>1</sup>, UMESH RAVIKANT SHELKE<sup>2</sup>, YOGESH A. BANG<sup>3</sup>

## ABSTRACT

It is very uncommon for a boar to become aggressive in nature against human unless they are cornered. A wild boar attacked a 24-year-old male from behind in perineal region. At presentation, he had continuous dribbling of urine and fecal matter from perineal wound. On CT-scan, a well defined tract delineated by contrast was seen between postero-lateral aspect of bladder and anterior wall of rectum, and there was contrast extravasation through perineal wound. After resuscitation, fistula was repaired through abdominal approach, and perineal wound was debrided. Emergency physician should be aware of such cases as increasing deforestation and shifting of humans to sub-urban area, have resulted in increased incidences of wild boar attack. Prompt stabilization of patient, treatment of infection with proper antibiotics, prevention of tetanus and rabies infection and emergency surgical interventions are necessary to reduce morbidity and mortality from such trauma.

**Keywords:** Exploratory laparotomy, Diversion colostomy, Perineal wound

## CASE REPORT

Attacks by wild boar are very few reported in literature. We report a rare case of perineal injury caused by a wild boar attack resulting in a recto-vesico-cutaneous fistula.

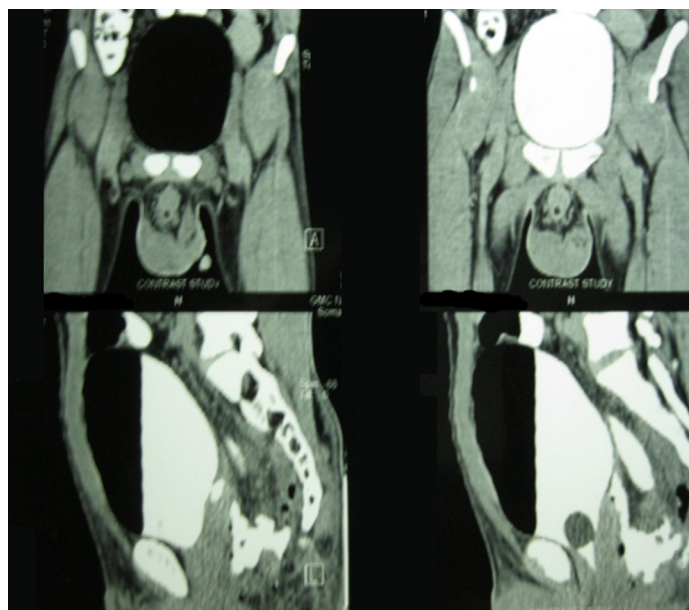
A wild boar attacked a 24-year-old male, residing in a village of Gadchiroli district, from behind while collecting dried branches of trees in forest. He was hit by the boar in perineal region. His accompanying friends rescued him. Patient was brought to our centre three days after the injury. At presentation, he had no desire to pass urine and had continuous dribbling of urine from the perineal wound. He was in septic shock at presentation. Resuscitation was done with intravenous crystalloids, and broad spectrum antibiotics were given. On initial examination, a 3x2 cm cruciate shaped penetrating wound was seen in perineum. Clear fluid admixed with fecal matter and blood clots, was dribbling from wound continuously. On digital examination, this penetrating wound was found to be communicating with anterior wall of rectum with a rent of approximately 1.5x2 cm in the antero-lateral rectal wall. Further, there was erythema and tenderness in perineal and scrotal region with some necrotic patches over scrotum. No other body site was injured other than few abrasions over abdominal region.

Perineal wound was thoroughly washed with normal saline and betadine. Patient was given tetanus toxoid booster dose, as he was initially immunized but had not received last dose in five years. Anti-rabies immunoglobulins, together with the dosage of anti rabies vaccine were given. On evaluation with Computed Tomography, a well defined tract delineated by contrast was seen arising from the postero-lateral aspect of bladder and communicating with the anterior wall of rectum posteriorly and there was contrast collection and extravasation through the perineal wound. Urethral injury was ruled out [Table/Fig-1].

Patient was stabilized and shifted to the operation theatre. On proctoscopy, there was a perforation in anterior rectal wall extending from 1 o'clock to 3 o'clock position. A Foley catheter was inserted through anterior rectal wall perforation. Exploratory laparotomy was done through midline incision and bladder was opened. There was a rent of 1x1 cm in posterior bladder wall, approximately 1.5 cm above trigonal region, communicating with the anterior rectal wall. Ureteral continuity was confirmed, and any other injury was ruled out. Bladder and rectum were separated. Edges were freshened. Thorough antibiotic wash was given.

Rectal perforation was closed in two layers. Bladder tear was closed transvesically in two layers. Bladder was drained through suprapubic and per urethral catheter. Omentum was interposed between bladder and rectum. As dense inflammatory adhesions were present around the fistula, diversion colostomy was done. Abdominal drain was kept. Perineal and scrotal lesions were debrided and thoroughly washed. Lose interrupted stitches were taken at the perineal fistula site.

Patient improved post-operatively. Perineal fistula site healed gradually. Cystogram was done prior to catheter removal. No leak was demonstrated. Distal loopogram was performed after 6 weeks, which showed no leak, so diversion colostomy was closed. Patient was asymptomatic at the time of follow up after 6 months of colostomy closure.



**[Table/Fig-1]:** CT cystography showing air in bladder, contrast delineated tract between bladder and rectum, and contrast collection and extravasation.

## DISCUSSION

Wild boar are among the most common and widespread large mammals in the world. They are primarily nocturnal animal and, are generally shy in nature, so incidences of attack by wild boar are

rare. When wild boar comes across human being, they generally flee away [1]. They are aggressive during their mating season. It is very uncommon for a boar to become aggressive against human unless they are cornered [2]. They are dangerous due to their razor sharp tusks, which can cause serious injuries. They typically live in dense forests, wild grassland and brushwood [1]. They are commonly seen in Europe, Asia, North Africa and Greater Sunda Island and their species, *Sus scrofa cristatus* is commonly seen in India [3]. After two years of age, male wild boar develops tusks, which they can use during attack to injure their victim. But increasing deforestation, increased agricultural and industrial use of land, and shifting of human to sub-urban area, have resulted in increased incidences of confrontation between human and wild boar [4].

Most common site of injury by wild boar is posterior aspect of thigh however they can inflict multiple injuries and injuries at sites other than posterior thigh, when the injured falls to ground due to initial attack [5,6]. Injuries caused by them can be fatal, with the common cause of death being cranio-cerebral injury and multiple abdominal penetrating injuries [6,7]. Following trauma, thorough wound washing with adequate wound care, tetanus immunization, protection against rabies and proper antibiotics are necessary for proper management of patient.

In literature, we found only two case reports of recto-vesico-cutaneous fistula. Hashmonai et al., have reported the first case in a patient following tuberculosis infection [8]. Second case was reported by Kocot et al., in a patient of carcinoma prostate following salvage cryotherapy. They managed this patient by salvage cysto-prostatectomy and continent cutaneous urinary diversion [9]. In literature, we found no report of perineal injury

resulting in recto-vesico-cutaneous fistula due to wild boar attack. It is a rare presentation, but increased shifting of human to forest areas for land usage has resulted in increased injury incidences due to wild boar attack.

## CONCLUSION

Emergency physician should be aware of such rare cases so as to take prompt resuscitatory steps in order to stabilize the patient, treat infection with proper antibiotics, prevent tetanus and rabies infection and do emergency surgical interventions to reduce the morbidity and mortality resulting from such trauma.

## REFERENCES

- [1] British wild boar. Available at: HYPERLINK "http://www.britishwildboar.org.uk" http://www.britishwildboar.org.uk. Site last updated: 02 April 2012.
- [2] Gunduz A, Turedi S, Nuhoglu I, et al. Wild boar attacks. *Wilderness Environ Med.* 2007;18:117-19.
- [3] Lydekker, R. (1900), HYPERLINK "https://archive.org/stream/greatsmallgameof1900lyde/page/258/mode/2up" "The great and small game of India, Burma, & Tibet, London : R. Ward, pp. 258-66
- [4] Meng XJ, Lindsay DS, Sriranganathan N. Wild boars as sources for infectious diseases in livestock and humans. *Philos Trans R Soc Lond B Biol Sci.* 2009;27:364:2697-707.
- [5] Kose O, Guler F, Baz AB, et al. Management of a wild boar wound: a case report. *Wilderness Environ Med.* 2011;22(3):242-45.
- [6] Manipady S, Menezes RG, Bastia BK. Death by attack from a wild boar. *J Clin Forensic Med.* 2006;13:89-91.
- [7] Shetty M, Menezes RG, Kanchan T, et al. Fatal craniocerebral injury from wild boar attack. *Wilderness Environ Med.* 2008;19:222-23.
- [8] Hashmonai M, Bolkier M, Schramek A. Tuberculous recto-vesico-cutaneous fistula. *Br J Urol.* 1982;54(3):324.
- [9] Kocot A, Spahn M, Loeser A, et al. Recto-vesico-cutaneous fistula following salvage cryotherapy of the prostate due to recurrent localized prostate cancer. *Urologe A.* 2011;50(11):1428-30.

### PARTICULARS OF CONTRIBUTORS:

1. Associate Professor, Department of General Surgery, Government Medical College, Nagpur, Maharashtra, India.
2. Super-Speciality Medical Officer, Department of Urology, Seth GS Medical College & KEM Hospital, Mumbai, Maharashtra, India.
3. Senior Resident, Department of Gastro-Intestinal Surgery, Asian Heart Institute, Hyderabad, India.

### NAME, ADDRESS, E-MAIL ID OF THE CORRESPONDING AUTHOR:

Dr. Umesh Ravikant Shelke,  
Department of Urology, 8<sup>th</sup> floor, MSB building, Seth GS Medical College & KEM Hospital,  
Mumbai-400012, Maharashtra, India.  
E-mail: drumshelke@gmail.com

FINANCIAL OR OTHER COMPETING INTERESTS: None.

Date of Submission: **Nov 23, 2015**  
Date of Peer Review: **Jan 25, 2016**  
Date of Acceptance: **Feb 05, 2016**  
Date of Publishing: **May 01, 2016**