

Chronic Myeloid Leukaemia Presenting as Bilateral Retinal Haemorrhages with Multiple Retinal Infiltrates

PRIYANKA RAMKRISHNA RANE¹, RAKESH K. BAROT², DEVADATTA JAYANTILAL GOHEL³, NUPUR BHAGAT⁴

ABSTRACT

Chronic Myeloid Leukaemia (CML) causes retinopathy manifesting as venous dilation and tortuosity, perivascular sheathing, retinal haemorrhages, microaneurysms, cotton-wool spots and optic nerve infiltration. Retina is the most commonly involved intraocular structure in CML. However, retinal involvement is a rare form of presentation of CML and few cases have been reported. We report a case of CML presenting as unilateral sudden visual loss. Fundus showed multiple white centered retinal haemorrhages in both eyes with unilateral macular oedema. Blood work-up showed raised WBC count, high platelet count and low Haemoglobin. Cytological analysis of bone marrow biopsy confirmed Philadelphia chromosome. After a course of Imatinib, visual acuity improved and haemorrhages resolved with normalization of macular thickness. In our case, patient presented early, leading to early detection producing better visual prognosis. This highlights the importance of detailed hematological work up in patients with retinal involvement to rule out leukaemic retinopathy.

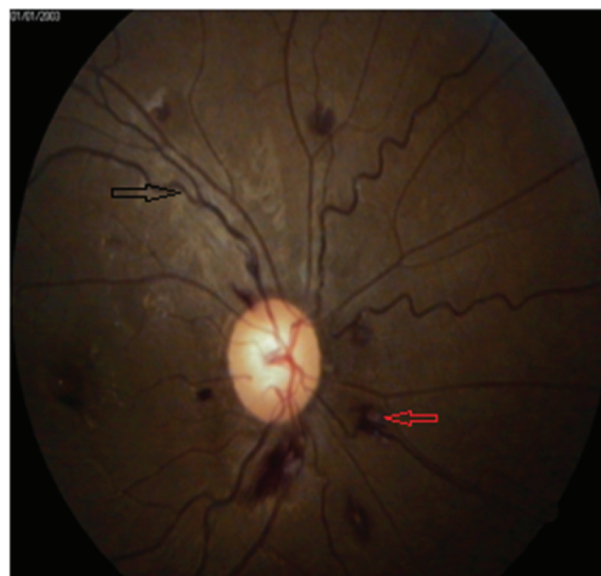Keywords: Leukaemic infiltration, Macular oedema, Imatinib

CASE REPORT

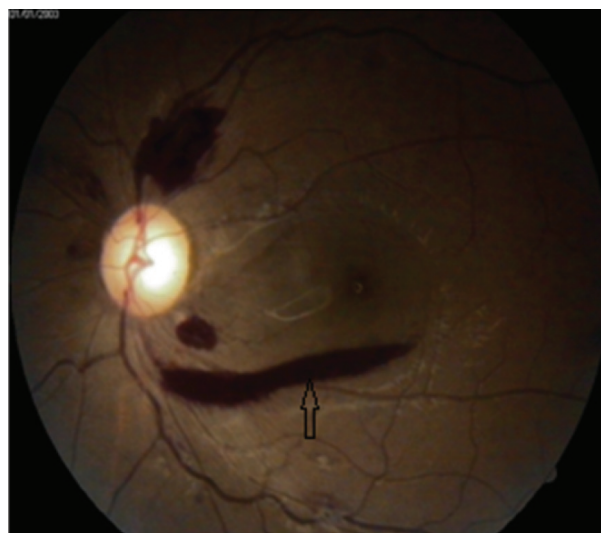
A 51-year-old female presented to the outpatient department of Guru Gobind Singh Hospital and Shri MP Shah Medical College, Jamnagar, with sudden diminution of vision in left eye since one month. She gave history of generalized fatigue over last 3 months. There was no history of trauma, diabetes mellitus and hypertension. She denied history of any eye medication or surgery. Family history was not contributory. Her best corrected visual acuity was 6/6 in the Right eye (RE) and 3/60 in the Left eye (LE). On ophthalmic examination anterior segment was unremarkable with normal pupillary reaction and intra ocular pressure of 16 mm of Hg in Both Eyes (BE). Extra ocular movements were normal in BE. Dilated fundus examination with 90D lens showed the presence of dilated and tortuous veins, white-centered haemorrhages (leukaemic infiltrations) and segmental perivascular white infiltrates scattered throughout the fundus in RE [Table/Fig-1]. LE fundus showed venous tortuosity, multiple pre retinal haemorrhages and multiple white-centered haemorrhages with dull foveal reflex suggestive of macular oedema in LE [Table/Fig-2]. Ocular Coherence Tomography (OCT) of macula of RE was normal while LE macula showed macular oedema [Table/Fig-3].

Laboratory investigations have been elaborated in [Table/Fig-4]. Haemoglobin electrophoresis and serum protein electrophoresis showed no abnormalities. Renal and hepatic functions were normal. The fasting glucose and haemoglobin A1c, lipid profile, reactive protein C activity, erythrocyte sedimentation rate, homocysteine level, serum protein S, protein C, and antithrombin III were within normal limits. Coagulation parameters were also normal. Physician's reference was done and massive splenomegaly was found.

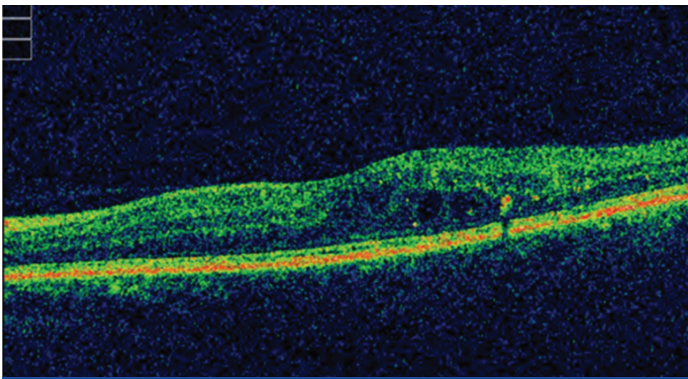
Thereafter patient was referred to Oncology Department of Civil Hospital, Ahmedabad for bone marrow biopsy. Bone marrow biopsy showed hypercellularity with increased myeloid to erythroid ratio along with megakaryocytosis. It did not reveal any fibrosis and blast percentage was 4%. The cytological examination along with the morphologic features confirmed the diagnosis of CML. Patient was started on oral Imatinib (800mg). After 2 months course of imatinib, her best corrected visual acuity in left eye improved to 6/18 and haemorrhages resolved significantly in BE. OCT macular analysis indicated normalization of macular thickness in left eye.



[Table/Fig-1]: RE fundus photograph showing white-centered haemorrhages (leukaemic infiltrations) and segmental perivascular white infiltrates.



[Table/Fig-2]: LE fundus photograph showing multiple pre-retinal haemorrhages and white-centered haemorrhages with macular oedema.



[Table/Fig-3]: Ocular coherence tomography evaluation of LE shows macular oedema.

Haemoglobin	9.0g/dL
WBC count	1,50,000/ μ L
Platelet count	4,48,000/ μ L
Peripheral smear	
Mature/Immature granulocytes	Increased
Blasts	1%
Basophils	5%
Serum lactate dehydrogenase	Elevated
Serum uric acid level	Elevated

[Table/Fig-4]: Laboratory investigations.

DISCUSSION

In 50% of patients with leukaemia ocular involvement is found clinically at the time of diagnosis. However, in majority of them the ocular involvement is asymptomatic [1,2]. Ocular involvement is frequently seen in acute than in chronic forms of leukaemia. In 3% of patients it presented as primary leukaemic infiltrate and as secondary complication in 39% [3]. However, retinal involvement is a rare form of presentation of CML and few cases have been reported [4-7].

Present case showed dramatic occurrence of unilateral sudden vision loss attributable to the macular oedema along with bilateral retinal haemorrhages with multiple retinal infiltrates associated with CML. In a similar case report, a 14-year-old boy presented with bilateral sudden visual loss following bilateral central retinal vein occlusion and massive retinal infiltrates

as a result of CML [3]. Two other cases have been reported of CML presenting as bilateral proliferative retinopathy [6,8]. In these cases severity of ophthalmic involvement is much more than our case. In our case, patient presented early leading to early detection producing better visual prognosis. Two case reports mainly showed ophthalmic involvement following CML detection. One case had proliferative retinopathy [4] while other showed peripheral retinal non perfusion [7] following CML. Our case report highlights the importance of detailed haematological work up in patients with retinal involvement to rule out leukaemic retinopathy in the absence of other systemic causal factors. Our case illustrates that even ophthalmic findings can serve as a clue to the underlying malignancy especially in case of leukaemia. Further, prompt treatment can result in resolution of the ocular findings and allow for better restoration of visual function.

CONCLUSION

Our case illustrates that bilateral retinal white centered haemorrhages may be the presenting feature of CML. Therefore, all cases with bilateral retinal white centered haemorrhages without systemic findings need thorough evaluation to rule out leukaemia. Early diagnosis and treatment in such cases is helpful for better visual recovery.

REFERENCES

- [1] Kincaid MC, Green WR. Ocular and orbital involvement in leukaemia. *Surv Ophthalmol.* 1983;27:211-32.
- [2] Schachat AP, Markowitz JA, Guyer DR, et al. Ophthalmic manifestations of leukaemia. *Arch Ophthalmol.* 1989;107(5):697-700.
- [3] Neha G, Meenakshi T, Usha K, Basudeb G, et al. Chronic myeloid leukaemia presenting with bilateral central retinal vein occlusion and massive retinal infiltrates. *American Association for Pediatric Ophthalmology and Strabismus.* 2012;16(4):406-08.
- [4] Huynh TH, Johnson MW, Hackel RE. Bilateral proliferative retinopathy in chronic myelogenous leukaemia. *Retina.* 2007;27:1245.
- [5] Mahneke A, Videbaek A. On changes in the optic fundus in leukaemia. aetiology, diagnostic and prognostic role. *Acta Ophthalmol (Copenh).* 1964;42:201-10.
- [6] Mandava N, Costakos D, Bartlett HM. Chronic myelogenous leukaemia manifested as bilateral proliferative retinopathy. *Arch Ophthalmol.* 2005;123:576-77.
- [7] Nobacht S, Vandoninck KF, Deutman AF, Klevering BJ. Peripheral retinal non-perfusion associated with chronic myeloid leukaemia. *Am J Ophthalmol.* 2003;135:404-06.
- [8] Macedo MS, Figueiredo AR, Ferreira NN, Barbosa IM, et al. Bilateral proliferative retinopathy as the initial presentation of chronic myeloid leukaemia. *Middle East Afr J Ophthalmol.* 2013;20(4):353-56.

PARTICULARS OF CONTRIBUTORS:

1. Registrar, Department of Ophthalmology, Rajiv Gandhi Medical College and Chhatrapati Shivaji Hospital, Kalwa, India.
2. Associate Professor and Head of Department, Department of Ophthalmology, Rajiv Gandhi Medical College and Chhatrapati Shivaji Hospital, Kalwa, India.
3. Professor and Head of Department, Department of Ophthalmology, Shri M.P. Shah Government College and Guru Gobind Singh Hospital, Jamnagar, India.
4. Registrar, Department of Ophthalmology, Rajiv Gandhi Medical College and Chhatrapati Shivaji Hospital, Kalwa, India.

NAME, ADDRESS, E-MAIL ID OF THE CORRESPONDING AUTHOR:

Dr. Priyanka Ramkrishna Rane,
B-3, Rudraksh C.H.S, Plot No.16, Sector-7, Airoli, Navi Mumbai-400708, India.
E-mail: priyankarane@yahoo.com

FINANCIAL OR OTHER COMPETING INTERESTS: None.

Date of Submission: Dec 08, 2015
Date of Peer Review: Jan 11, 2016
Date of Acceptance: Feb 24, 2016
Date of Publishing: May 01, 2016