

# JOURNAL OF CLINICAL AND DIAGNOSTIC RESEARCH

**How to cite this article:**

JOHN T , GUNA SHEKHAR M, KOSHY M. DENTIGEROUS CYST ASSOCIATED WITH SUPERNUMERARY TEETH: A REPORT OF THREE CASES. Journal of Clinical and Diagnostic Research [serial online] 2010 June [cited: 2010 June 17]; 4:2601-2606.

Available from

[http://www.jcdr.net/back\\_issues.asp?issn=0973-709x&year=2010 &month= June &volume=4&issue=3&page=2601-2606 &id=657](http://www.jcdr.net/back_issues.asp?issn=0973-709x&year=2010 &month= June &volume=4&issue=3&page=2601-2606 &id=657)

## CASE REPORT

# Dentigerous Cyst Associated With Supernumerary Teeth: A Report Of Three Cases

JOHN T \*, GUNA SHEKHAR M\*\*, KOSHY M\*\*\*

### ABSTRACT

Dentigerous cyst originates by the separation of the follicle from the crown of an unerupted tooth or a developing tooth bud. These cysts seldom associate with supernumerary teeth. The resorption of roots which are adjacent to a supernumerary tooth (mesiodens) or its cyst is a rare complication. The purpose of this article is to describe three rare cases of dentigerous cyst associated with supernumerary teeth and their complications and management.

**Key Words:** mesiodens. dentigerous cyst, root resorption, displacement

**Key Message:** Early detection comprising of a thorough clinical and radiographical examination is necessary for accurate diagnosis, to provide appropriate management and to prevent associated complications.

---

\*Associate Professor, Faculty of Oral Medicine and Maxillofacial Radiology, NTRUHS, AP, (India).

\*\*Associate Professor, Faculty of Pediatric Dentistry, NTRUHS, AP, (India).

\*\*\*Registrar Endodontist, Ministry of Health, Kuwait

**Corresponding Author:**

Dr. Tenny John

S-4, Block-3, Balajyothi-Kranthi apartments, JP Road, Bhimavaram, WG District-534202, AP, India

Mobile: +919848026081

E-mail: drtennyjohn@gmail.com

### Introduction

Dentigerous cyst (DC) is the most common developmental odontogenic cyst which originates from the separation of follicle from the crown of an unerupted tooth or a developing tooth bud [1]. It occurs most commonly in the second and third decade of life [2] and typically involves the mandibular third molar, the maxillary canines and the mandibular premolars, followed by supernumerary teeth and the central incisor in the decreasing order of the frequency of involvement [3].

DC around supernumerary teeth accounts for 5% of all dentigerous cysts and mostly involves a mesiodens in the anterior maxilla<sup>4</sup>. Mesiodentes are common in the anterior palate

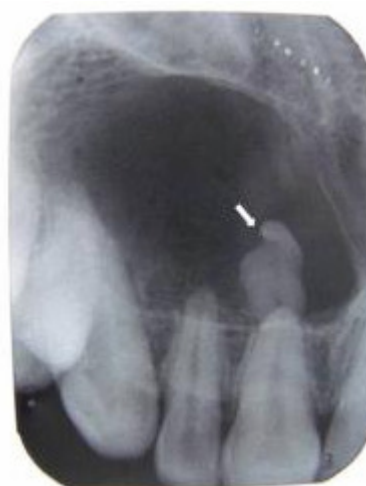region [5],[6] and may be erupted or impacted and the direction of the crown may be normal, inverted, or horizontal [7].

The common complications which are associated with these teeth include eruption disturbances and the displacement or rotation of the teeth [8],[9],[10]. Supernumerary teeth seldom associate with dentigerous cysts and are uncommon. This article reports three rare cases of dentigerous cysts associated with mesiodens and their complications and management.

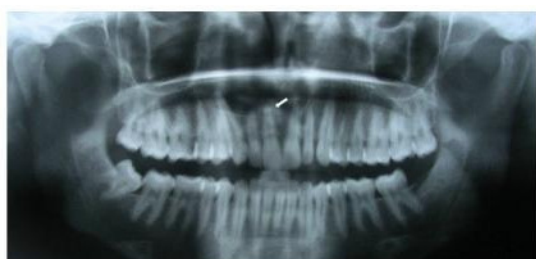### Case 1

A 22 year old Indian male presented with a swelling in the right maxillary anterior region. On general examination, the patient was apparently healthy and there was no history of systemic diseases or trauma. The swelling was noticed 6 months back, but was ignored by the patient as it was asymptomatic. Clinical examination revealed a soft, fluctuant, painless swelling, extending from the maxillary right central incisor to the right canine in the labial mucobuccal fold. The mucosa overlying the swelling appeared to be intact. The maxillary anterior teeth were non mobile and responded positively to vitality tests. The radiological

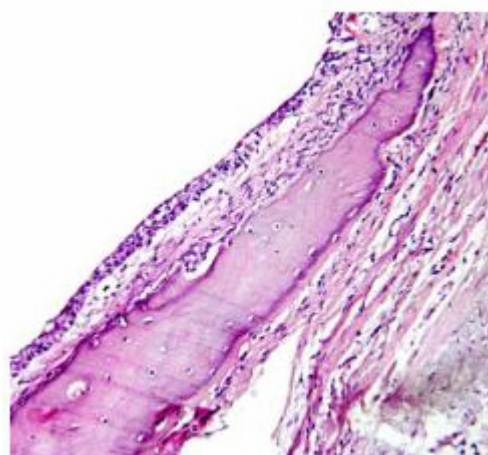
examination included panoramic, occlusal and periapical radiographs which showed an impacted supernumerary tooth (inverted mesiodens) with a short root apical to the maxillary right central incisor which was associated with a well defined unilocular radiolucent area in the anterior region of the maxilla. Displacement of the roots of the maxillary right lateral incisor and the canine was evident (**Figures 1-3**) [Table/Fig 1]. After clinical and radiographical examination, a diagnosis of dentigerous cyst involving an impacted mesiodens was made. Routine haematological investigations were normal. Extraction of the mesiodens and surgical enucleation of the cyst was done under local anaesthesia. Histological examination of the specimen confirmed the diagnosis of a dentigerous cyst (**Figure 4**) [Table/Fig 2]. The patient was under follow-up for 6 months and presented no complications.



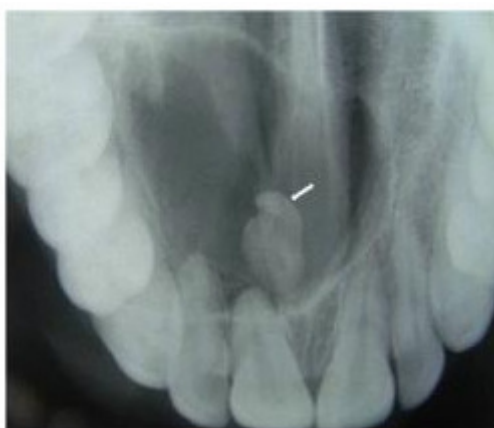(Table/Fig 3) Periapical radiograph (case 1)



(Table/Fig 1) Panoramic radiograph showing radiolucent lesion involving an inverted supernumerary apical to maxillary right central incisor (case 1)



(Table/Fig 4) Histological picture showing cystic lining with squamous epithelium and presence of mucous cells in the epithelial lining (H&E stain 20X)

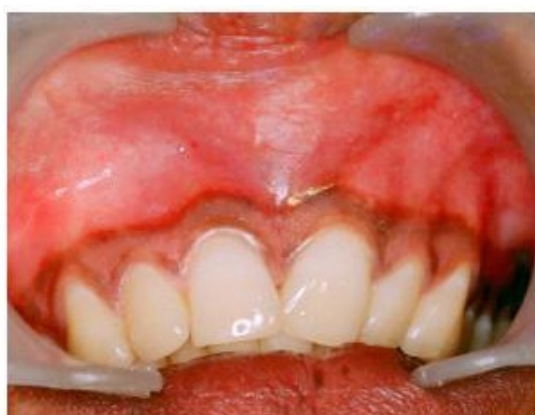

(Table/Fig 2) Occlusal radiograph showing a unilocular radiolucent lesion (case 1)

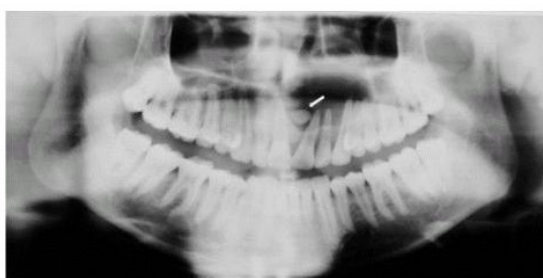### Case 2

A 24 year old male presented with a swelling in the labial mucobuccal fold between the maxillary central incisors (**Figure 5**) [Table/Fig 3]. Detailed anamnesis revealed that the swelling was slow growing, painless and was of 8 months duration. The overlying mucosa was intact and no bruit or pulsations were observed. The maxillary anterior teeth were non mobile and vital. The maxillary left central and lateral incisors and canine showed mild palatal inclination. Radiographs showed a large well defined radiolucent area involving the crown of an unerupted horizontally

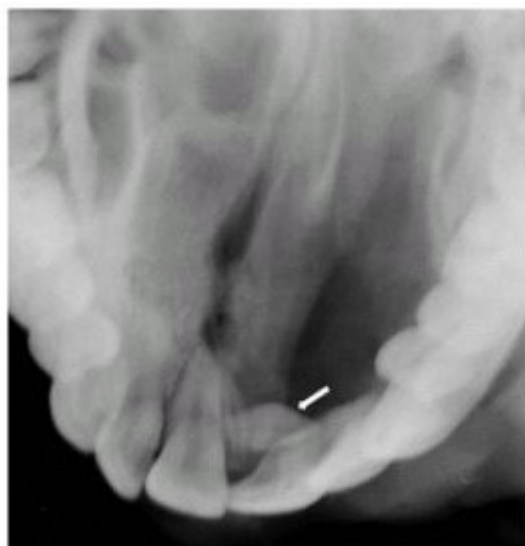
positioned mesiodens between the maxillary central incisors. Displacement of the roots of the maxillary left incisors and the canine was clearly evident, resulting in a change in their axial inclination. No evidence of the resorption of the roots was seen (**Figures 6-8**) [Table/Fig 4]. Clinical and radiographical findings were suggestive of dentigerous cyst. Routine haematological investigations were normal. The mesiodens was surgically extracted and the cystic lining was enucleated under local anaesthesia. The post operative healing was uneventful. The patient was under follow-up for six months and presented no complications. Histopathological examination of the specimen confirmed the diagnosis of a dentigerous cyst.



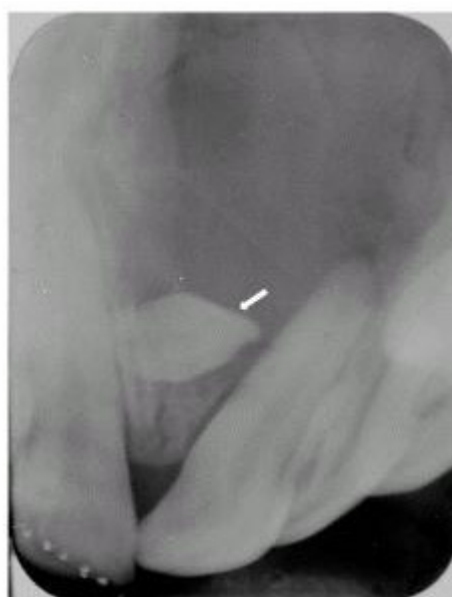(Table/Fig 5) Clinical picture with swelling in the mucobuccal fold between the maxillary central incisors (case 2)



(Table/Fig 6) Panoramic radiograph (case 2)



(Table/Fig 7) Occlusal radiograph (case 2)

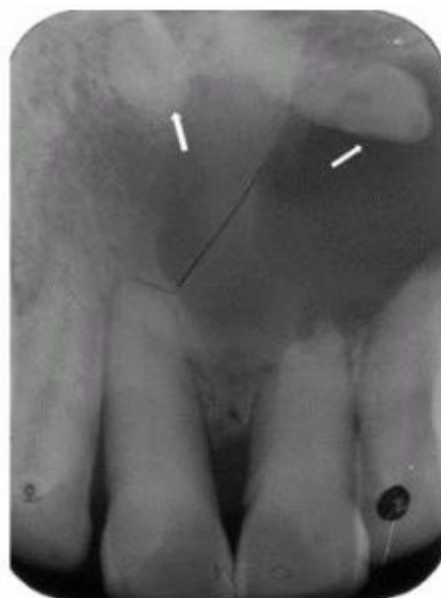

(Table/Fig 8) Periapical radiograph (case 2)

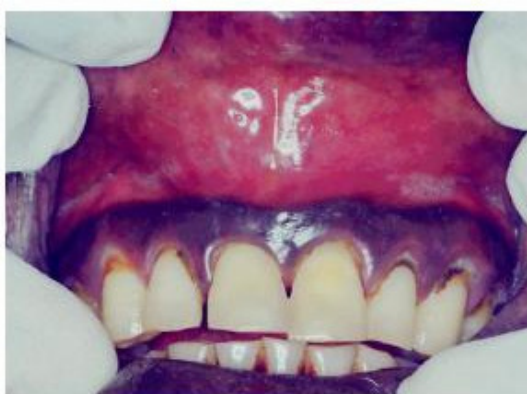### Case 3

A 46 year old male presented with a labial swelling (midline) in the anterior region of the maxilla (**Figure 9**) [Table/Fig 5]. The swelling was of 10 months duration and was slow growing. The patient gave a history of occasional pain which was associated with the swelling. Intra oral examination revealed multiple decayed molars. Root stumps were present in relation to 17 and 27. Further, 46,

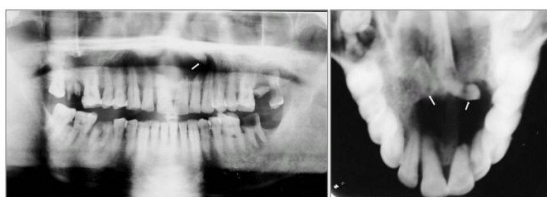37 and 28 were severely decayed. Generalized moderate to severe calculus and stains were noticed. The maxillary left central and lateral incisors were not carious and did not respond to vitality tests. A provisional diagnosis of a radicular cyst in relation to the maxillary left central incisor was made. On further investigation, the radiographs revealed a large radiolucent area in the anterior maxilla, involving one of the two impacted supernumerary teeth (mesiodens) with short roots and were suggestive of a dentigerous cyst. Further, root resorption of 21 and 22 was evident (Figures 10-11) [Table/Fig 6]. Routine haematological and biochemical tests were normal. Maxillary left incisors [21],[22] were endodontically treated and were obturated with gutta-percha. Then, under general anaesthesia, surgical extraction of the impacted supernumerary teeth and enucleation of the cyst was done, followed by retrograde filling of 21 and 22 with mineral trioxide aggregate. The post operative course was uneventful. The histological examination of the specimen was suggestive of a dentigerous cyst.



(Table/Fig 11) Periapical radiograph (case 3)



(Table/Fig 9) Clinical picture of midline swelling in maxillary arch in (case 3)



(Table/Fig 10) Panoramic and occlusal radiographs showing two supernumerary teeth and a cystic lesion in case 3

### Discussion

Literature reports the prevalence of the mesiodens to be in the range of 0.15% to 2.2% of the population [7]. The mesiodens can erupt or remain impacted and often cause developmental and eruption disturbances of permanent teeth which are adjacent to them, leading to crowding, displacement, diastema and in some cases, radicular resorption and dentigerous cyst formation [7],[8],[9],[10]. All the three cases described here presented cyst formation involving the mesiodens. In addition, displacement of the adjacent teeth was seen in two cases and one patient showed evidence of root resorption.

Some studies have reported that dentigerous cyst formation arising from supernumerary teeth account for 5.29-7% of the cases[11],[12],[13]. Asami et al (2004)[14] reported a prevalence of 11% and suggested that mesiodentes impacted for prolonged periods of time possess a higher risk of forming dentigerous cysts. Resorption of roots adjacent to a supernumerary tooth (mesiodens) or its cyst is a rare complication [7],[10],[11]. In case three presented here, the resorption of the roots of the teeth adjacent to a dentigerous cyst involving the mesiodens was evident. The possible reason for this may be related to the



longer duration of the impacted mesiodens and the associated lesion.

Differential diagnosis of radicular cyst, odontogenic keratocyst and adenomatoid odontogenic tumour was considered in our cases. Histological evaluation of the lesion has been recommended, owing to its potential to develop into an ameloblastoma or mucoepidermoid carcinoma [15],[16]. The characteristic feature of the lesion involving an unerupted tooth crown in the anterior region of the maxilla along with the radiographical and histological examination confirmed the diagnosis of dentigerous cyst in all the three cases.

Management of a supernumerary tooth depends on the type and position of the tooth and its effect on the adjacent teeth. Removal of the supernumerary has been recommended where there is evidence of the associated pathology, eruption disturbances, displacement of the incisors or where the spontaneous eruption of the supernumerary tooth has occurred [17].

Surgical removal of the cyst has been considered as the preferred choice of treatment. Marsupialization has been recommended for dentigerous cysts in children to allow the eruption of unerupted tooth; and should be preferred for large cysts where enucleation and tooth removal might result in damage to the nerve and blood vessels supplying the adjacent teeth [15],[16]. In all the three cases, surgical removal of the impacted mesiodens and enucleation of the associated cyst was performed.

When the supernumerary tooth is evident, the direction of the crown, the location, the influence on adjacent teeth, the resorption of adjacent roots and the formation of dentigerous cysts should be carefully evaluated [18]. Conventional radiographical examination involving panoramic, occlusal and periapical views have been used to locate their exact position for proper treatment plan and surgical removal. Computed tomography (CT) and Cone-beam CT have emerged as diagnostic techniques to assess supernumerary teeth.

Early detection comprising of a thorough clinical and radiographical examination is necessary for accurate diagnosis to prevent associated complications.

## References

- [1] Ziccardi VB, Eggleston TI, Schneider RE, Using fenestration technique to treat a large dentigerous cyst. *J Am Dent Assoc* 1997; 128: 201-5.
- [2] Shear M. Dentigerous (follicular) cyst. In *Cysts of the oral region*, 2<sup>nd</sup> Ed. Bristol: Weight PSG; 1983. P. 56-75
- [3] Desai RS, Vanaki SS, Tegginamani AS. Dentigerous cyst associated with permanent central incisor: A rare entity. *J Indian Soc Pedod Prev Dent* 2005; March: 49-50.
- [4] Dinkar AD, Dawasaz AA, Shenoy S. Dentigerous cyst associated with multiple mesiodens: A case report. *J Indian Soc Pedod Prev Dent* 2007; 25: 56-59.
- [5] Welbury R. Special situations. In: Heasman P, editor. *Master Dentistry. Vol. 2. Restorative Dentistry, Paediatric Dentistry and Orthodontics*. Toronto: Churchill Livingstone, 2003; pp 199-26.
- [6] Alaejos C, Contreras MA, Buenechea R, Berini L, Gay C. Mesiodens: a retrospective study of 44 patients. *Med Oral*. 2000; 5:81-88.
- [7] Kaan Gunduz, Peruze Celenk, Zeynep Zengin, Pinar Sumer. Mesiodens: a radiographic study in children. *J Oral Sci* 2008; 50: 287 – 91.
- [8] Rajab LD, Hamdan MA. Supernumerary teeth: review of the literature and a survey of 152 cases. *Int J Paediatr Dent*. 2002;12: 244 - 54.
- [9] Liu DG, Zhang WL, Zhang ZY, Wu YT, Ma XC. Three-dimensional evaluations of supernumerary teeth using cone-beam computed tomography for 487 cases. *Oral Surg Oral Med Oral Pathol Oral Radiol Endod*. 2007;103: 403-11.
- [10] Kim SG, Lee SH. Mesiodens: a clinical and radiographic study. *J Dent Child* 2003; 70: 58-60.
- [11] Hyun HK, Lee SJ, Lee SH, Hahn SH, Kim JW. Clinical characteristics and complications associated with mesiodentes. *J Oral Maxillofac Surg* 2009; 67: 2639 – 43.
- [12] Kessler HP, Kraut RA. Dentigerous cyst associated with an impacted mesiodens. *Gen Dent* 1989; 37: 47-49.
- [13] Hurlen B, Humerfelt D. Characteristics of premaxillary hyperdontia. A radiographic study. *Acta Odontol Scand* 1985; 43: 75-81.
- [14] Asaumi JI, Shibata Y, Yanagi Y, et al. Radiographic examination of mesiodens and their associated complications. *Dentomaxillofac Radiol* 2004; 33: 125-27.
- [15] Kojima Y, Seo R, Maki K, Kimura M. A case of dentigerous cyst in a thirteen- year old girl. *Pediatric Oral Maxillofac Surg* 2005;15:26-32.
- [16] Hyomoto M, Kawakami M, Inove M, Kirita T. Clinical conditions for eruption of maxillary canines and mandibular premolars associated

- with dentigerous cysts. Am J Orthod Dentofacial Orthop 2003;124: 515-520.
- [17] Garvey MT, Barry HJ, Blake M. Supernumerary teeth: an overview of classification, Diagnosis and Management. J Can Dent Assoc 1999; 65: 612-16.
- [18] Von Arx T. Anterior maxillary supernumerary teeth: A clinical and radiographic study. Aust Dent J 1992; 37: 189 – 95.