

**How to cite this article:**

KARANAM L.S.P., BADDAM S.R, DEV B, JOSEPH S. Carotid Cavernous Fistulae: Various Presentations And Treatment approaches: Results in 25 Cases Journal of Clinical and Diagnostic Research [serial online] 2010 August [cited: 2010 August 20 ]; 4:2790-2796.

Available from

[http://www.jcdr.in/article\\_fulltext.asp?issn=0973-709x&year=2010&volume=&issue=&page=&issn=0973-709x&id=822](http://www.jcdr.in/article_fulltext.asp?issn=0973-709x&year=2010&volume=&issue=&page=&issn=0973-709x&id=822)

## ORIGINAL ARTICLE

### Carotid Cavernous Fistulae: Various Presentations And Treatment Approaches: Results in 25 Cases

KARANAM L.S.P. \*, BADDAM S.R\*\*, DEV B \*\*\*, JOSEPH S \*\*\*\*

#### ABSTRACT:

**Aim:** To discuss the clinical presentation and the efficacy of endovascular management by various methods as the treatment option for direct carotid cavernous fistulae. **Method and materials:** In our study, 25 patients were included during the period from 04/02/2006 to 02/12/2008. 16 were male patients and 09 were female patients with a mean age of 37 years. 25 patients presented with Type A carotid fistulae, of which 21 patients had an aetiology of trauma. A majority of the patients (21) presented with proptosis, the other symptoms being redevye (19), diplopia (9), headache (13) and diminished vision (17). Pre procedural workup with CT, CTA, MR and MRA was done in all the patients. High resolution DSA was done by using Advantax LCN+ (GE Biplane system). Embolisation materials in the form of balloons were used in 15 patients and coils in 5 patients. Both balloons and coils were used in 3 patients. **Results:** Complete cure in the form of total reversion was achieved in twenty one patients. Improvement with residual pathology was achieved in two patients in whom there was complete clinical cure, but the angiogram demonstrated small residual fistula. The procedure was abandoned because of technical reasons in one patient. Spontaneous closure of the fistula occurred in one patient. Complications in the form of inadvertent balloon detachment occurred in two patients. Thus, complete cure was seen in 84% of our patients which is in par with the worldwide literature of 84-87% success rate. **Conclusion:** Endovascular therapy is the treatment of choice for Direct carotid cavernous fistulae.

**Key Words:** Interventional Radiology, Carotid, Fistulae

\*Resident, Department of Radiology and Imaging Sciences

\*\*Professor, Department of Radiology and Imaging Sciences

\*\*\*Professor and Head, Department of Radiology and Imaging sciences, Sri Ramachandra University, Chennai.

Institution: Department of Radiology and Imaging Sciences, Sri Ramachandra University, Chennai - 600 116, India.

**Corresponding Author:**

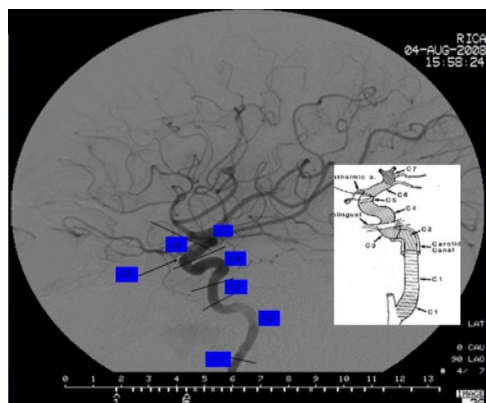
Dr . Lakshmi Sudha prasanna  
Resident in Radiology.

Department of Radiology and Imaging Sciences  
Sri Ramachandra Medical College and Research Institute, Chennai - 600 116, India.

Ph: 91- 9940517748(R), 91- 44- 24766917 (O), Fax: 91- 44- 24767008

#### Indroduction

Carotid cavernous fistulae (CCF) are spontaneous or acquired communications between the carotid artery and the cavernous sinus. These lesions may be associated with acute visual decline or haemorrhage. Sub selective catheterization and angiography of the cranial vasculature related to this pathology has helped us in an intense angiographic search for the supply to the fistula. The cavernous sinus is an anatomical complex containing elements which differ both in their structure and origin. The cavernous segment of the carotid artery [Table/Fig 1] is unique, as it is the only anatomical location in the body where an artery is completely surrounded by a venous structure.



**[Table/Fig 1]: Digital subtraction angiogram depicting various segments of internal carotid artery**

The knowledge of relations of various cranial nerves to the cavernous sinus very important, it differs greatly from other venous sinuses due to its location and structure. The relationship between the venous sinus proper and the ICA is of peculiar importance. The venous sinus proper cannot change a lumen width as a dense cavernous capsule limits it. Thus, pulse increase of the ICA volume is possible only at the expense of the reduction of the cavernous sinus volume. The cavernous sinus is the most important regulator of cerebral circulation. This “venous heart” has a great impact on the intracranial venous circulation.

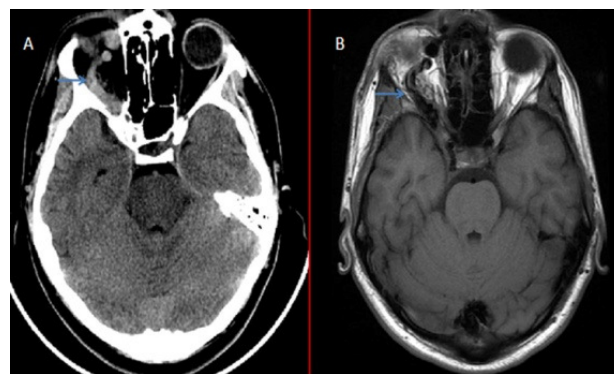
The cavernous sinus has rich communications - with the facial veins through the superior and inferior ophthalmic veins, with the transverse and sigmoid sinuses through the superior and inferior petrosal sinuses, with the cerebral cortical veins through the sphenoparietal sinus, and with the pterygoid plexus. Thus, these lesions can have a wide range of clinical presentations. Type A CCF are direct fistulae between the ICA and the cavernous sinus, and are most commonly secondary to trauma. Type B, type C and type D CCFs, are low flow indirect fistulae where multiple micro fistulae are located within the wall of the cavernous sinus and drain into it. The arterial supply to these lesions may originate from the dural branches of the ICA (Type B),

the dural branches of the ECA (Type C) or from the dural branches of the ICA and the ECA (Type D). The most common treatment widely used for Carotid Cavernous fistulae include embolisation of the fistulae by using a balloon or by coils. We discuss here, our experience in the presentation and the treatment of the Type A fistulae which are the most common variety of all the types.

### Materials and Methods

25 patients who were diagnosed to have CCF presented to us during the period from 2006-2008. Out of the 25 patients, 16 were males and 9 were females. The youngest patient was 7 years of age and the oldest was 68 years old, with a mean age of 37 years. The procedure was abandoned in 1 patient due to technical difficulties. Most of the patients were diagnosed clinically, the diagnosis being supplemented by imaging. CT/MRI [Table/Fig 2].

was used to diagnose the lesion The rest of the musculoskeletal injuries were also evaluated and treated on a priority basis. These lesions also provided a base line for further follow up.



**[Table/Fig 2]: CT and MR image demonstrating the enlarged superior ophthalmic vein on the right side.**

The line of management was decided upon, after taking into consideration the feasibility of the endovascular approach. The hardware and the embolisation or occlusion materials were dependent on the goal of the procedure, the selectivity being accomplished. Mostly, balloon occlusion of the [Table/Fig 3].

site with or without coil embolisation was done in the direct type of fistula.



[Table/Fig 3] showing the inflated detachable balloon threaded on a delivery catheter

Post procedure, patients were observed for symptomatic responses and thus, for the accomplishment of the pre-therapeutic goals.

The follow-up protocol included clinical examination at 1- 3months interval for one year and every 6 months, the following year. Conventional radiographs were obtained to see the position of the balloons or the coils used. Repeat angiography was done in patients who showed non-satisfying response and the next strategies were planned accordingly.

### Results

The patients were divided according to the angiographic classification into the direct and indirect types and according to aetiology as the traumatic and the spontaneous types. Only direct traumatic fistulae were included in the present series. Complete cure in the form of total reversion was achieved in twenty one patients. Improvement with residual pathology was achieved in two patients in whom there was complete clinical cure, but the angiogram demonstrated small residual fistulae. The procedure was abandoned because of technical reasons in one patient. Spontaneous closure of the fistula occurred in one patient. Complications in the form of inadvertent balloon detachment occurred in two patients. Thus, complete cure was seen in 84% of our patients

which is in par with the worldwide literature of 84-87% success rate.

[Table/Fig 4]: Distribution according to embolisation material used:

Balloons	15
Coils	05
Both balloons and coils	03

Post procedural complications in the form of transient cranial nerve palsies (IIIN, IVN) occurred in two patients. One patient had an MCA infarct due to the inadvertent dislodgement of the balloon into the MCA and the patient developed hemiplegia.

[Table/Fig 5]: Outcomes of the procedure were graded as:

Complete cure	21	84%
Procedure abandoned	01	4.0%
Complications	02	8.0%
Spontaneous closure of fistula	01	4.0%

Here, complete cure means a total reversion of the disease both clinically and on angiographic analysis(table5).

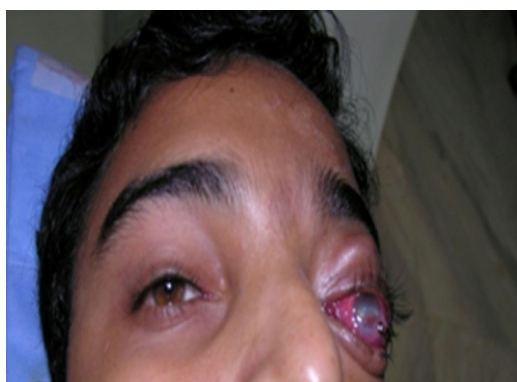### Discussion

In our series of 25 patients with direct fistulae, 21 had trauma as an etiological factor. The most common presenting symptom was proptosis (80%) and 70% had pulsating exophthalmos on clinical examination. Diminished vision was seen in 50% of the patients in our series. Diagnostic cerebral angiogram, which is the gold standard imaging, was done in all the patients. The rent of the fistula was seen most commonly in the Clinoid segment of the internal carotid artery (C5 segment).

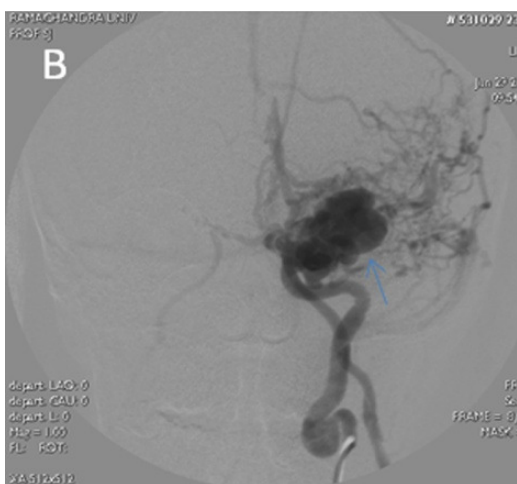
Several series have been published, describing therapeutic embolisation of the traumatic carotid cavernous fistulae. These include reports by Serbinenko<sup>1</sup>, Debrun et al<sup>2,15</sup>, Vinuela et al, Norman et al<sup>6</sup> and Halbach et al<sup>5,15,17</sup> The indications of urgent treatment for these fistulae were rapid loss of vision, the presence of pseudoaneurysm, cortical venous drainage and the thrombosis of the venous tracts<sup>11</sup> Noteworthy, are the excellent results obtained by a variety of different techniques and

embolisation methods for treating the CCF with acceptable morbidity and mortality rates as compared to direct surgical intervention.

A majority of the patients (15) in our study were treated by balloon embolisation. Embolisation was done in a single session in these patients. No other adjunctive treatment was needed in these 15 patients in whom complete regression of the fistula was noted and they improved clinically [Table/Fig 6,7,8,9]:.Clinical improvement was seen as early as 24 hours, with complete regression of the symptoms within one week in this group of patients.



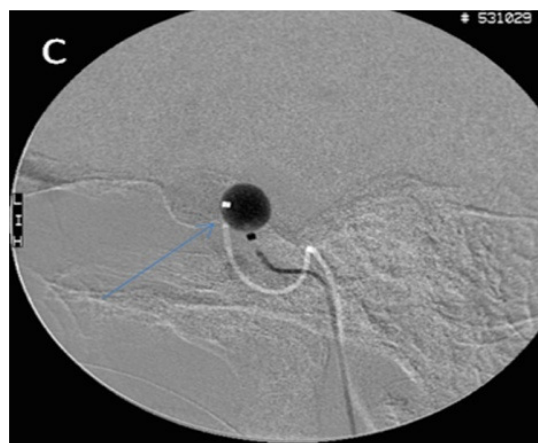
[Table/Fig 6]: 35 year old male presented with proptosis and diminution of vision from 2 months after road traffic accident.



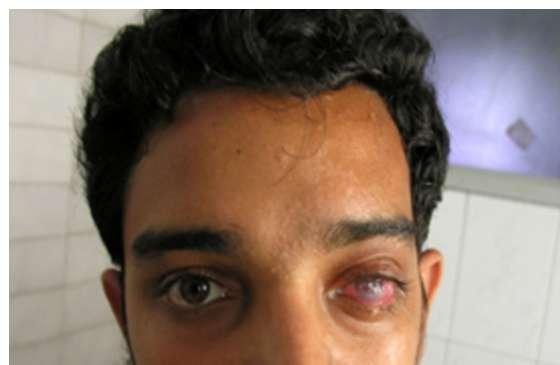
[Table/Fig 7]: Pre procedure Internal carotid Angiogram demonstrating the fistulous communication and dilated superior ophthalmic vein which is filling in the arterial phase

A large series of patients have proved the effectiveness of transarterial balloon

embolization, which is currently the treatment of choice for this disease. Embolization of a carotid cavernous fistula (CCF) by means of a detachable balloon is an established method for treating CCFs while preserving a patent parent internal carotid artery (ICA). However, failure to embolize the CCF may occur on a few occasions, such as when the balloon cannot pass through the fistula into the cavernous sinus by blood flow, or when the inflated balloon in the cavernous sinus retracts to the carotid artery. If the placement of balloons by the intra-arterial approach is not possible, coil embolization of the fistula via an arterial or a venous route may be attempted<sup>3</sup>.



[Table/Fig 8]: Detachable balloon negotiated through the fistula with regression of the fistula



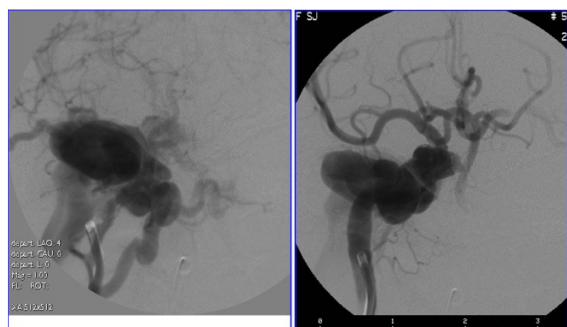
[Table/Fig 9]: Post procedure the patient shows decrease in proptosis. The vision was improved

In a group of three patients among the 25 in our series, the fistulae were not regressed after one or two sessions of the balloon embolisation. In these patients, coils were used for



embolisation since the symptoms persisted and there was decline in the vision. In these patients in whom previous balloon embolisation was done and subtotal occlusion was achieved, navigation of additional balloons was unsuccessful because of the presence of the previous balloons blocking the orifice of the fistula. Hence, microcoils were used for embolisation via the transarterial route for complete obliteration of the fistulous communication. Successful regression of the fistula was demonstrated in the post procedure angiograms in all the three patients .Gradual improvement of the proptosis and vision was seen in all the patients.

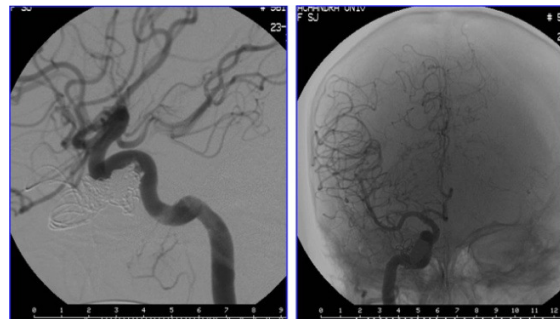
In another group of three patients, coils alone were used for embolisation **Table/Fig 10,11,12**. In these patients, the size of the fistula was too large.



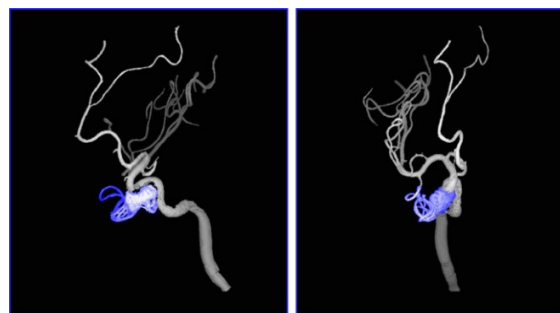
**[Table/Fig 10]:** Preprocedure angiogram showing the fistulous communication and the cavernous sinus and the dilated superior ophthalmic vein

Balloon embolisation in cases with large fistula can cause retraction of the balloon into the ICA. Also, multiple balloons occupying the cavernous sinus can cause cranial nerve palsies. In addition, incomplete occlusion of the fistulous opening can produce pseudo aneurysm. Hence, transarterial catheterization with a micro catheter and embolisation with microcoils was done in these patients and obliteration of the fistulous communication was achieved after the treatment with improvement in the clinical symptoms of the patients. The technical pitfalls reported in the literature which are associated with embolisation done with coils, include the impossibility of easy retrieval, the relative stiffness of the coils, the

risk of perforation and the difficulty of packing them tightly. However, we did not encounter any of these difficulties in our experience with coil embolisation.



**[Table/Fig 11]:** Post procedure angiogram showing regression of the fistula and the coil mass insitu.



**[Table/Fig 12]:** Post procedure 3D volume rendering images showing the coil mass insitu.

Two of the patients in our series did not respond to either therapy and underwent a complete occlusion of the distal cervical ICA. The most common indication for ICA occlusion was a sinus which could be entered but could not be occluded, or associated large pseudo aneurysms or a sinus which could not be navigated. A temporary balloon occlusion test was performed in these patients before the occlusion of the parent vessel to assess the collateral circulation from the contra lateral side.

The procedure was abandoned in one patient due to technical complications. This patient had a large tear in the cavernous segment of the carotid artery and carotid blow out, and hence, the balloon could not be properly positioned in the fistula. The balloon occlusion test was not tolerated in this patient, who underwent surgical trapping at a later date. In one patient, inadvertent dislodgement of the

balloon into the MCA resulted in an infarct in the MCA territory and he developed post procedure hemiplegia. Spontaneous regression of the fistula occurred in one patient who presented with proptosis and chemosis. An angiogram which was done, demonstrated a fistula on presentation. Carotid compression manoeuvre<sup>5</sup> was explained to the patient who came for follow up after 2 months. A repeat angiogram was done, which did not show any fistula and there was complete improvement in the patients' symptoms. Spontaneous regression of high flow fistula is very rare and we encountered one in our experience.

In case of indirect fistulae, most patients do not have bruit or pulsatile exophthalmos, which indicates a vascular lesion. Diagnosing these slow flow fistulas is clinically difficult. The symptoms are not as dramatic as in traumatic high flow cavernous sinus fistulas. This diagnosis should always be considered in patients with a red eye and arterialized episcleral vessels. Although dural CCFs tend to be low-flow and low-pressure lesions as compared to direct CCFs, the failure of the trial of manual carotid artery-jugular vein compression therapy with increasing symptoms of diminished vision, headache, diplopia and chemosis, is considered as an indication for embolisation in this spontaneous group.

Embolisation of External carotid artery feeders is first done in these cases to decrease the symptoms of the patients. The embolic materials used for the embolization include coils or balloons for the transvenous approach. PVA particles, N butyl cyanoacrylate glue and onyx are used for transarterial embolisation. The goal of embolisation in patients with these fistulae is the alleviation of the patients' symptoms and not angiographic cure.

## Conclusion

Endovascular treatment is the procedure of choice with acceptable risk in the direct type of carotid cavernous fistulae with traumatic aetiology. The goal of the treatment is the preservation of the carotid artery with obliteration of the fistula and clinical improvement.

## References

- [1] Serbinenko FA. Balloon catheterization and occlusion of major cerebral vessels. *J Neurosurg* 1974; 41 : 125 - 145.
- [2] Debrun G, Lacour P, Caron JP, Hurth M, Comoy J, Keravel Y. Detachable balloon and calibrated-leak balloon techniques in the treatment of cerebral vascular lesions. *J neurosurg* 1978; 49:635-649
- [3] Hieshima GB, Grinnell VS, Mehringer CM. A detachable balloon for therapeutic transcatheter occlusions, *Radiology* 1981; 138:227-228
- [4] Higashida RT, Halbach VV, Dowd C, et al. Endovascular detachable balloon embolisation therapy of cavernous carotid artery aneurysms: results in 87 cases. *J Neurosurg* 1991;123:318-320
- [5] Norman D, Newton TH, Edwards MS, DeCaprio V. Carotid-cavernous fistula: closure with detachable silicone balloons. *Radiology* 1983; 149:149-157
- [6] Sanders WP, Burke TH, Mehta BA. Embolisation of intracranial aneurysms with Guglielmi detachable coils augmented by micro balloons, *AJNR Am J Neuroradiol* 1998; 19:917-920
- [7] Thomas J, Masaryk John Perl, Robert C. Wallace, Michelle Magdinecand Douglas Chyatte Detachable Balloon Embolisation: Concomitant Use of a Second Safety Balloon *American Journal of Neuroradiology* 1999; 20:1103-1106.
- [8] Perase P, Morris, Balloon Reconstructive Technique for the Treatment of a Carotid Cavernous Fistula. *American Journal of Neuroradiology* 1999; 20:1107-1109
- [9] Debrun G, Lacour P, Viñuela F, et al: Treatment of 54 traumatic carotid-cavernous fistulas. *J Neurosurg* 55:678-682, 1981
- [10] Debrun GM, Vinuela F, Fox AJ, Davis KR, Ahn HS, Indication for treatment and classification of 132 carotid-cavernous fistulas, *Neurosurgery* 1988;22:285-289.
- [11] Halbach VV, Hieshima GB, and Higashida RT, Reicher M. Carotid cavernous fistulae: indication for urgent treatment. *AJR Am J Roentgenol* 1987; 149: 587-593.
- [12] Halbach VV, Higashida RT, Hieshima GB, Reicher M, Norman D, Newton TH. Dural fistulas involving the cavernous sinus: results of treatment in 30 patients. *Radiology* 1987; 163: 437-442.
- [13] Halbach VV, Higashida RT, Hieshima GB, Hardin CW, Pribram H. Transvenous embolization of dural fistulas involving the cavernous sinus. *AJNR Am J Neuroradiol* 1989; 10:377-383.
- [14] Halbach VV, Higashida RT, Barnwell SL, Down CF, Hieshima GB. Transarterial platinum coil embolisation of carotid-cavernous fistula. *AJNR Am J Neuroradiol* 1991; 12:429-433
- [15] Barrow DL, Spector RH, Braun IF, Landman JA, Tindall SC, Tindall GT. Classification and treatment of spontaneous carotid cavernous fistulas. *J Neurosurg* 1985; 62: 248-256.
- [16] Lewis al, Tomsick TA, Tew JM. Management of 100 consecutive direct carotid-cavernous fistulas: results of treatment with detachable balloons. *Neurosurgery* 1995; 36:239-244
- [17] Uflacker R, Lima S, Ribas GC, Piske RL. Carotid-cavernous fistulas: Embolization through the superior orbital vein approach. *Radiology* 1986; 159:175-179
- [18] Debrun GM, Vinuela F, Fox AJ, Davis KR, Ahn HS. Indications for treatment and classification of 132 carotid-cavernous fistulas. Debrun GM. Endovascular management of carotid-cavernous fistulas In: Valavanis A, ed. *Interventional Neuroradiology*. New York, NY: Springer, 1993;23-34