

"Histiocytosis X" – A Rare Case Report

EMMANUEL DHIRAVIA SARGUNAM AZARIAH¹, DEEPAK CHANDRASEKARAN², RAVINDRAN CHINNASWAMI³, SIVARAMAKRISHNAN BALASUBRAMANIAM⁴, ESWARI JAGDISH⁵

ABSTRACT

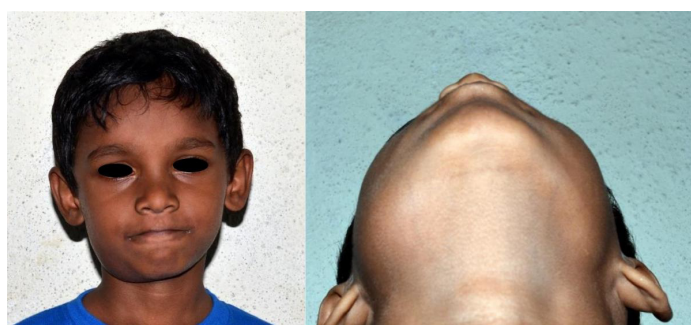Histiocytosis X is an idiopathic disease, characterized by a disorder of the reticulo-endothelial system in the human body. Histopathological studies carried out right from the 1800s have seen a significant similarity in the pathologic process of different stages in particular clinical syndromes showing proliferation of mature histiocytes. It was then modified by Lichenstein in 1953 as "Histiocytosis X". The exact aetiology is unknown; hence, the name "Histiocytosis X". The disease classically presents with three syndromes namely Eosinophilic granuloma, Letterer-Siwe disease and Hand-Schuller-Christian disease. These syndromes present with a spectrum of clinical manifestations with histiocytic proliferation in the granulomatous lesion. The disease is neither familial nor hereditary, nor does it have any microbiological pathologic origin. This disease can be conservatively managed by antibiotics and steroids or surgical curettage with radiotherapy. We report a five-year-old male child who was incidentally diagnosed to have Histiocytosis X. This patient was managed with a moderate surgical procedure with total avoidance of radiotherapy. An adequate follow-up of this patient shows total regression of the lesion and good bone healing.

Keywords: Bone lesion, Child, Jaw Disease, Langerhans cell histiocytosis

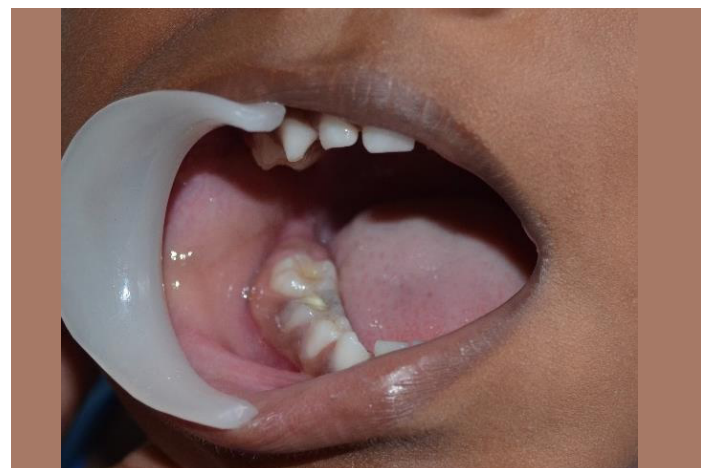CASE REPORT

A five-year-old child patient came with a chief complaint of intermittent pain on the lower right side of the face since one month duration. Swelling was small in size and gradually increased to present size. On extra-oral examination, a localized swelling measuring approximately 4x5cm extending anteriorly from the right commissure of the lip up to the angle of mandible. Inferiorly up to the lower border of the mandible [Table/Fig-1]. Lymph node examination revealed two palpable submandibular lymph nodes on the right side which were mobile and tender on palpation. Intra-oral examination presented with restricted mouth opening with inter-incisal opening of 1.5cm and an ovoid solitary swelling in relation to the right buccal sulcus in relation to 43 to an erupting 47 extending till the retro-molar trigone which was tender on palpation [Table/Fig-2]. On bimanual palpation, expansion of the buccal and lingual plate was present. Orthopantomogram (OPG) and Cone Beam Computerized Tomogram (CBCT) revealed an ill-defined radiolucency from the mesial root of 46 to the ascending ramus with expansion of the lower border of the mandible [Table/Fig-3]. To diagnose the involvement of other systems in this triad a diagnostic 99 TC-MDP whole body scintigraphy was performed. The scintigraphy showed an increase tracer pooling in the right side of the mandible with no evidence of bony metastasis at other sites of the body [Table/Fig-4]. An incisional biopsy was deferred as the

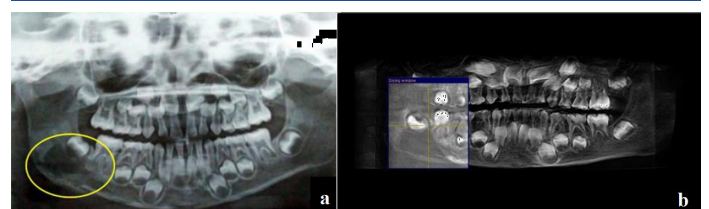
patient was uncooperative to local anaesthetic procedure. Patient was taken up for localized lesion enucleation, bone curettage and extraction of the tooth germ (46 and 47) with excision of the right submandibular lymph node. Under general anaesthesia, right Risdon's submandibular incision was placed and layer by layer dissection was performed to reach the submandibular region [Table/Fig-5]. The submandibular lymph node was removed. Facial artery was ligated and the lower border of the mandible was reached. The lesion was identified and enucleated. Peripheral osteotomy was done for the adjacent bone along with removal



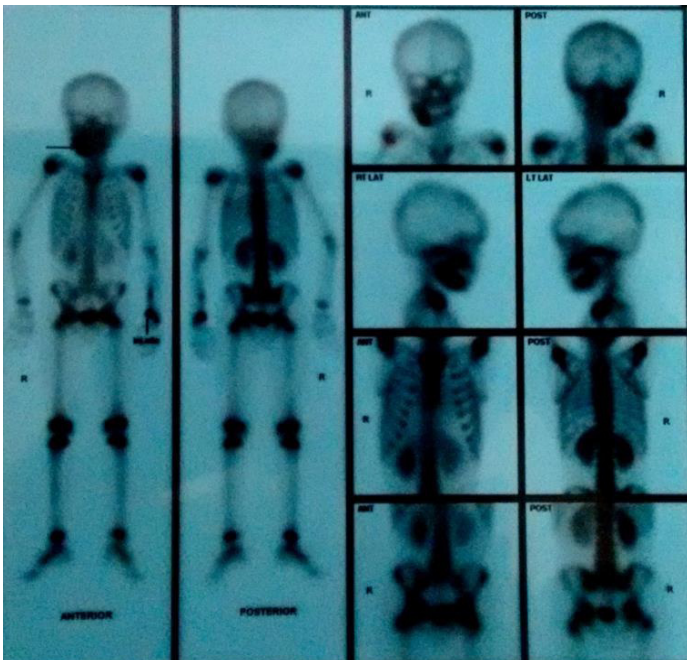
[Table/Fig-1]: Clinical photograph.



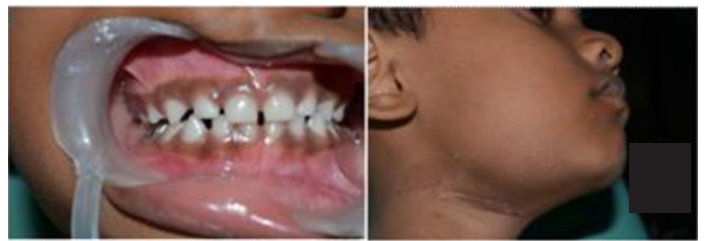[Table/Fig-2]: Intra-oral photograph – swelling in the right vestibule.



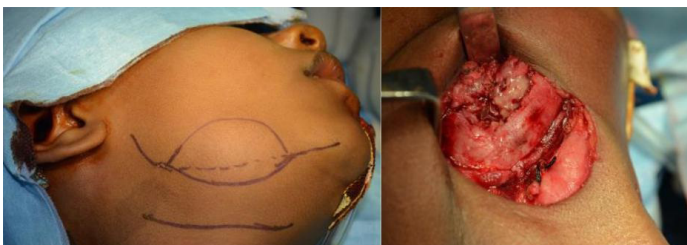[Table/Fig-3a,b]: (a) Orthopantomogram; (b) Cone beam CT – showing the lesion on the right side mandible.



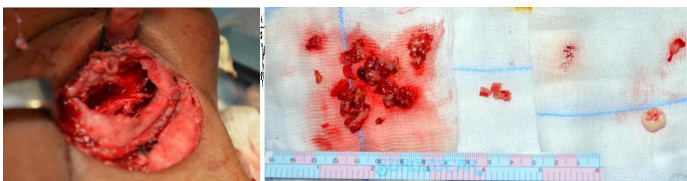[Table/Fig-4]: A 99 TC-MDP whole body scintigraphy showing an increase tracer pooling in the right side of the mandible with no evidence of bony metastasis at other sites of the body.



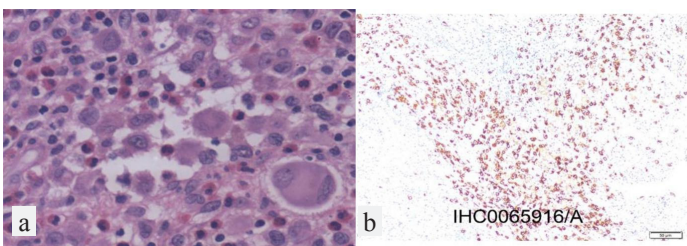
[Table/Fig-8]: One year post-operative clinical photo and orthopantomogram showing good bone healing.



[Table/Fig-5]: Surgical approach to the lesion.



[Table/Fig-6]: Surgical defect and the curetted lesion along with tooth germ 46 and 47.



[Table/Fig-7a,b]: Microphotograph showing (a) Histiocytes (large cells) in dense eosinophilic infiltrate at 40X; (b) Immunohistochemistry with CD 1a immunoreactive in tumour cells (4X).

of 47 tooth follicle [Table/Fig-6]. Haemostasis was obtained. The curetted specimen was sent for histopathological analysis which was suggestive of solitary eosinophilic granuloma [Table/Fig-7a]. For confirmatory diagnosis, an immunohistochemistry was performed which showed CD 1A immunoreactive in the tumour cells correlating with Langerhans Cell Histiocytosis (LCH) [Table/Fig-7b]. Post-operatively, patient was treated with the Tablet Indomethacin 300 mg BD regimen for a period of 2 months. Radiotherapy was deferred due refusal of the parents. He was periodically observed for a year and showed no evidence of recurrence till date. A one year post-operative OPG showed good wound healing with no signs of recurrence of the lesion [Table/Fig-8].

DISCUSSION

Histiocytosis is an idiopathic disease characterized by a disorder of the reticulo-endothelial system in the human body [1]. Paul Langerhans first described the epidermal dendritic cells in 1868 [2]. Histopathological studies carried out from 1800s have seen significant similarity in the pathologic process of different stages in particular clinical syndromes showing proliferation of mature histiocytes [3]. LCH is an accumulation of phenotype of Langerhans cells which are arrested at an early stage of maturation and are functionally deficient [4]. In 1933, Siwe grouped these cases under one syndrome and termed it "reticuloendotheliosis". Later in 1944, Jaffe and Lichenstein gave the disease a different syndrome "peculiar inflammatory histiocytosis" [5]. It was modified by Lichenstein in 1953 as "Histiocytosis X". The exact aetiology is unknown; hence, the name "Histiocytosis X". The disease classically presents with three syndromes namely eosinophilic granuloma, Litterer-Siewe disease and Hand Sculler Christian disease. These syndromes present with a spectrum of clinical manifestations with histiocytic proliferation in granulomatous lesion. It is considered as "non-lipid reticulososes" in which there is an increase of cells in the reticulo-endothelial system with or without the accumulation of lipid material [6]. The disease is neither familial nor hereditary and does not have any microbiological origin.

Diagnosis of this condition is based on the histological and hematological features given by International Histiocytic Society [7]. It can be divided into three entities based on the region involved and severance of the disease. They are isolated lesion (eosinophilic granuloma); Hand-Schuller-Christian disease and Litter-Siewe disease [6]. The variability in the signs and symptoms of these conditions makes this disease a complex system. The primary signs are orally involved starting with ulceroproliferative gingiva, mobile teeth and bleeding gums, a reasonable differential diagnosis can be made ruling out the non-systemic condition. Oral cavity lesions may occur before the appearance of lesion elsewhere in the body [8]. This makes a dentist a sentinel person to identify this condition which can be brutal if diagnosed at a later stage. Mandible has twice more predilection than maxilla. It usually occurs from 5 to 15 years of age. This is very much consistent with our patient with mandibular involvement, who also fell within this criteria. These lesions can be managed with Non-Steroid Anti-Inflammatory Drugs (NSAIDs) and surgical curettage [9-12]. There is a recurrence rate of 7.3% if it occurs in the mandible [13]. [Table/Fig-9] shows the frequency and distribution of this rare condition and how these were managed. A Positron Emission Tomography (PET) scan was performed to rule out any distant new lesion [14-20].

S.No.	Author	Patient Details	Clinical Presentation	Radiographic Presentation	Treatment	Follow-up
1	Sigala JL et al., [14]	50 Patients 26-Female 24-Male	Letterisieve Disease-7 cases Hand Schuller Christian Disease-37 cases Eosinophilic Granuloma-6 cases 76%-Bone Lesion 46%-Hepatomegaly 36%-Oral Lesions	-	Extraction of teeth + Bone Curettage + Radiotherapy	Nil
2	Rapidis et al., [15]	50 cases Mandible-38 Skull-18 Maxilla-16 Lungs-10 Ribs-8 Long Bones-8 Oral Soft Tissues-4 Vertebrae-4 Skin and Generalised	26 cases-Solitary oral lesion 24 cases-Systemic involvement	-	Surgery-15 cases Surgery + DXT+Cx-12 cases Surgery + DXT-7 cases Surgery + Cx-7 cases DXT + CX-8 cases	5 years
3	Rapidis et al., [6]	1. 3-year-old patient 2. 2-year-old patient	1. Left side mandible 2. Mandible	Radiolucent lesion Punched out irregular	1. Radiation 2500 rads 2. No Treatment	14 months
4	Wong et al., [16]	3 patients	1. Left pre-auricular and left condyle 2. Left condyle 3. Right condyle	1. CT Scan- circumscribed cystic lesion superficial sclerosis with periosteal reaction 2. X ray-Radiolucent lesion-Condylar neck and head 3. CT Scan-Lytic lesion in the right condyle	Surgical exploration and curettage-3 cases	1. 3 year 2. 1 year 3. 5 years
5	Lee et al., [17]	2 patients	Mandibular angle left side T4 vertebrae, right ilium, left iliac bone metaphysis of both femurs	CT Scan-Unilocular radiolucency 2 patient-Multilocular radiolucency	Corticosteroids	15 months
6	Felstead et al., [8]	1 patient	Right side mandible	CT scan-abnormal enlargement of hemi mandible	Chemotherapy + Intra- lesional steroids	5 years
7	Merglova et al., [18]	2 patients	Bilateral maxilla	MRI-Involvement of skeletal bones	Chemotherapy followed radiotherapy and corticosteroids	1 patient: 12 month 2 patient: 8 year
8	Daming et al., [19]	1 patient	Neck region	CT scan-Osteolytic lesion of jugular foramen extending to the lateral mass of atlas	Surgery + Radiotherapy 10 Gy	6 months
9	Vashisht et al., [20]	1 patient	Bilateral parotid region	MRI Scan-Bilateral parotid enlargement : Multi cystic	Corticosteroids + Vinblastine	12 months

[Table/Fig-9]: Clinical presentation of "Histiocytosis x" in the oral and maxillofacial region.
DXT-Local steroid injection; Cx-chemotherapy; Gy-Gray.

Management of histiocytosis is done on individual case basis [21] which includes use of local steroid injection (DXT), radiotherapy and chemotherapy (CX). Though different methods have been advocated, radiotherapy is rarely used in children. We followed a similar treatment protocol of avoiding radiotherapy. Patient was started on NSAIDs (Indomethacin) regimen for a period of two months. Extent and progress of the disease should be studied periodically and a biopsy should be done every seven months to set a good treatment protocol and to rule out other comorbidities [8].

CONCLUSION

Histiocytosis X is a complex disease which can be diagnosed step by step. If the practitioner follows every sign and symptom to detail, the differential diagnosis can highlight the positives of the disease very easily. In the differential diagnosis, it is mandatory to consider both benign and malignant bone lesions of the oral cavity and soft tissues. This particular case is a solitary eosinophilic granuloma where the other signs of Letterer-Siewe and Hands-Schuller-Christian disease have been ruled out at present. This patient was managed without radiotherapy. Treatment results showed good bone healing without recurrence with reduced systemic adverse

effects. For a good treatment protocol, observation and palliative therapy is mandatory over a long period for best results.

REFERENCES

- [1] Gorsky M, Silverman S Jr, Lozada F, Kushner J. Histiocytosis X: Occurrence and oral involvement in six adolescent and adult patients. *Oral Surg Oral Med Oral Pathol.* 1983;55(1):24-28.
- [2] Langerhans P. U'ber die Nerven der menschlichen Haut. *Arch Abl B Pathol.* 1868;44:325e337.
- [3] Shklar G, Taylor R, Schwartz S. Oral lesions of eosinophilic granuloma: Histologic and clinical considerations. *Oral Surg Oral Med Oral Pathol.* 1965;19:613-22.
- [4] Histiocytosis syndromes in children. Writing group of the histiocytosis society. *Lancet.* 1987;1(8526):208e209.
- [5] Sedano HO, Cernea P, Hosxe G, Gorlin RJ. Histiocytosis X. Clinical, radiologic, and histologic findings with special attention to oral manifestations. *Oral Surg Oral Med Oral Pathol.* 1969;27(6):760-71.
- [6] Rapidis AD, Langdon JD, Patel MF, Harvey PW. Histiocytosis X: Current concepts and a report of two cases. *Br J Oral Surg.* 1979;16(3):219-33.
- [7] The Histiocytosis Society. Available from URL:<http://www.histiocytosisociety.org>.
- [8] Felstead AM, Main BG, Thomas SJ, Hughes CW. Recurrent Langerhan's cell histiocytosis of the mandible. *Br J Oral Maxillofac Surg.* 2013;51(3):264-65.
- [9] Ladisch S, Gardner H. Treatment of Langerhan's cell histiocytosis – evolution and current approaches. *British Journal of Cancer Supplement.* 1994;23:S41-46.
- [10] Arcei RJ, Brenner MK, Pritchard J. Controversies and new approaches to treatment of Langerhan's cell histiocytosis. *Hematology/Oncology Clinics of North America.* 1998;12:339– 57.

- [11] Fowles JV, Bobechko WP. Solitary eosinophilic granuloma in bone. *Journal of Bone and Joint Surgery British Volume*. 1970;52:238–43.
- [12] Slater JM, Swarm OJ. Eosinophilic granuloma of bone. *Medical and Pediatric Oncology*. 1980;8:151–64.
- [13] Ardekian L, Peled M, Rosen D, Rachmiel A, Abu el-Naaj I, Laufer D. Clinical and radiographic features of eosinophilic granuloma in the jaws: Review of 41 lesions treated by surgery and low-dose radiotherapy. *Oral Sur, Oral Med, Oral Pathol, Oral Radiol Endod*. 1999;87:238–42.
- [14] Sigala JL, Silverman S Jr, Brody HA, Kushner JH. Dental involvement in histiocytosis. *Oral Surg Oral Med Oral Pathol*. 1972;33(1):42-48.
- [15] Rapidis AD, LangdonJD, Harvey PW, Patel MF. Histiocytosis X. An analysis of 50 cases. *Int J Oral Surg*. 1978;7(2):76-84.
- [16] Wong GB, Pharoah MJ, Weinberg S, Brown DH. Eosinophilic granuloma of the mandibular condyle: Report of three cases and review of the literature. *J Oral Maxillofac Surg*. 1997;55(8):870-78.
- [17] Lee SH, Yoon HJ. Intralesional infiltration of corticosteroids in the treatment of localized Langerhan's cell histiocytosis of the mandible: Report of two cases. *Oral Surg Oral Med Oral Pathol Oral Radiol*. 2013;116(4):e255-60.
- [18] Merglova V, Hrusak D, Boudova L, Mukensnabl P, Valentova E, Hosticka L. Langerhans cell histiocytosis in childhood - Review, symptoms in the oral cavity, differential diagnosis and report of two cases. *J Craniomaxillofac Surg*. 2014;42(2):93-100.
- [19] Daming C, Yajun X, Zhaoli S, Rui S, Meiqing L. Langerhan's cell histiocytosis in the jugular foramen. *Neurol Neurochir Pol*. 2014;48(2):158-62.
- [20] Vashisht D, Muralidharan CG, Sivasubramanian R, Gupta DK, Bharadwaj R, Sengupta P. Histiocytosis. *Med J Armed Forces India*. 2015;71(2):197-200.
- [21] Windebank K. Advances in the management of histiocytic disorders. *Paediatrics and Child Health*. 2008;18:129–35.

PARTICULARS OF CONTRIBUTORS:

1. Associate Professor, Department of Oral and Maxillofacial Surgery, Faculty of Dental Sciences, Sri Ramachandra University, Chennai, Tamil Nadu, India.
2. Reader, Department of Oral and Maxillofacial Surgery, Faculty of Dental Sciences, Sri Ramachandra University, Chennai, Tamil Nadu, India.
3. Head of Department, Department of Oral and Maxillofacial Surgery, Faculty of Dental Sciences, Sri Ramachandra University, Chennai, Tamil Nadu, India.
4. Postgraduate Student, Department of Oral and Maxillofacial Surgery, Faculty of Dental Sciences, Sri Ramachandra University, Chennai, Tamil Nadu, India.
5. Postgraduate Student, Department of Oral and Maxillofacial Surgery, Faculty of Dental Sciences, Sri Ramachandra University, Chennai, Tamil Nadu, India.

NAME, ADDRESS, E-MAIL ID OF THE CORRESPONDING AUTHOR:

Dr. Emmanuel Dhiravia Sargunam Azariah,
Department of Oral and Maxillofacial Surgery, Faculty of Dental Sciences, Sri Ramachandra University,
1, Sri Ramachandra Nagar, Chennai, Tamil Nadu, India.
E-mail: emmanuelazariah@gmail.com

Date of Submission: **May 25, 2016**Date of Peer Review: **Jun 30, 2016**Date of Acceptance: **Sep 12, 2016**Date of Publishing: **Oct 01 2016****FINANCIAL OR OTHER COMPETING INTERESTS:** None.