

# Morphometric Analysis of the Occipital Condyle and Its Surgical Importance

SANDEEP SALUJA<sup>1</sup>, SUSHANT SWAROOP DAS<sup>2</sup>, NEELAM VASUDEVA<sup>3</sup>

## ABSTRACT

**Introduction:** The Occipital Condyle (OC) is an integral component of craniovertebral region which is predisposed to a wide array of traumatic, degenerative and neoplastic diseases. Frequent surgical interventions of OC are required for successful management of these conditions. Hence a meticulous anatomical knowledge of the OC is vital but variability in morphometric dimensions exist amongst different races and hinder the standardization of measurements.

**Aim:** The aim of this study was to present a morphometric reference database for OC of the Indian population and enable comparisons with other populations.

**Materials and Methods:** The study was performed on 228 OC of 114 adult human skulls. Linear measurements of the OC were taken with the help of digital Vernier's calliper and angular measurements were determined with software Image J.

**Statistical Analysis:** Mean and standard deviation of the morphometric parameters taken into account were analysed. The comparison of morphometric dimensions of the right and left sides was carried out using Student's t-test and p-value was calculated.

**Results:** The morphometric analysis of the OC established that mean width was larger (12.97 mm) in Indians population when compared to other races. The anterior and posterior intercondylar distances as well as the distances between the tips of OC and opisthion and basion were observed to be shorter in Indians. We found a significant difference ( $p=0.01$ ) among the distance between Posterior tip of Occipital Condyle (POC) and basion of the right and left sides. The sagittal condylar angle and sagittal intercondylar angle were found to be greater in our study when compared to other researchers. There existed a highly significant difference ( $p=0.001$ ) between the sagittal condylar angles of the right and left sides.

**Conclusion:** The present morphometric study would be valuable for the successful instrumentation of the OC as wider and ventrally oriented OC as well as smaller intercondylar distances may pose challenge to the surgeons during condylectomy. The data of present study offer anatomical reference to the surgeons and would be helpful in designing implants for the OC.

**Keywords:** Condylectomy, Implants, Instrumentation, Morphometry, Sagittal condylar angle

## INTRODUCTION

The human Occipital Condyle (OC) is the distinctive bony structure linking the skull and the vertebral column [1]. The OC partly cover the fringe of the foramen magnum anteriorly and form an articulation with the superior articular facets on the lateral masses of the atlas inferiorly. Each OC which is oval in outline and oriented obliquely is traversed by hypoglossal canal. A condylar fossa is situated just posterior to the OC and can contain a posterior condylar canal for an emissary vein from the sigmoid sinus. Laterally, the occipital bone connects with the petrous part of the temporal bone anteriorly and the mastoid process posteriorly [2].

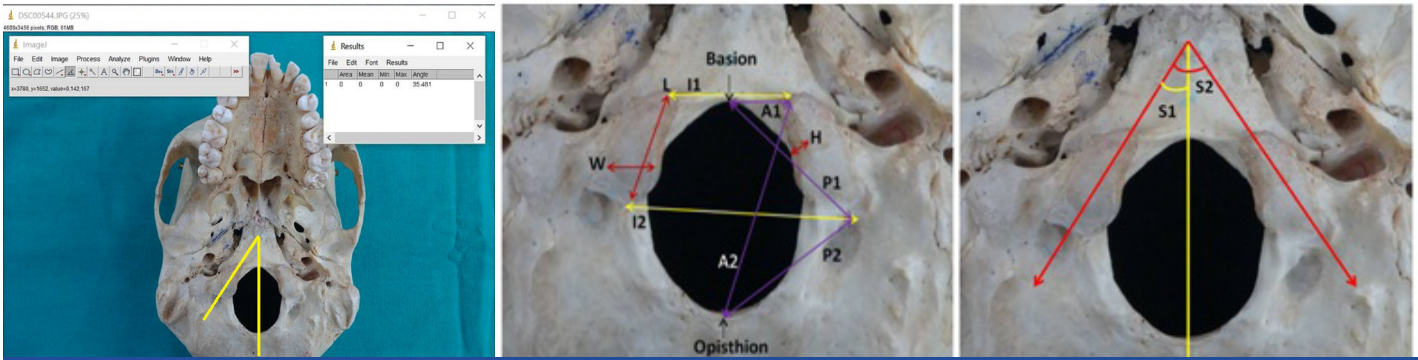
During interventional operations; the direction, angle and position of the nail may change according to the OC morphometry and the difference in measurements may alter the surgical procedure [3]. Occipital plates are frequently utilized during occipitocervical fixation but the complex anatomy of the craniocervical junction poses challenge during these procedures [4]. The surgical mistakes in this region may damage the neuro-vascular structure and result in craniocervical instability. Further, the management of ventrally placed space-occupying lesion at the level of foramen magnum necessitates the use of dorsal approach as high rate of morbidity and complications are frequently linked with ventral approaches. This requires transcondylar approach demanding

partial resection of the OC which is a vital step for entrance to the ventral and ventrolateral foramen magnum [1]. Hence, the surgical instrumentation of the craniovertebral region necessitates a thorough anatomical knowledge of the OC.

Differences exist in OC morphometric values across different study populations. So far, out of the studies available, few determine the morphometry of OC, especially in the Indian population [1,3-16]. The present study quantified morphometric characteristics of the OC which are mandatory for safe screw placement during surgical instrumentation of this region.

## MATERIALS AND METHODS

The present study included 228 OC of 114 adult human skulls of unknown sex which were part of the osteological collection of the Department of Anatomy. The study commenced in July, 2015 and accomplished in May, 2016. Skulls that were damaged or those with deformities, which may influence measurements, were excluded from the study and only intact skulls in good condition were studied. All linear measurements were ascertained using digital Vernier's calliper with 0.01mm precision while angular measurements were recorded with software Image J. [Table/Fig-1] demonstrates methodology of angle measurement.



**[Table/Fig-1]:** Methodology of angle measurement with software Image J. **[Table/Fig-2]:** Inferior view of base of skull showing; (L)- Length of OC; (W)- Width of OC; (H)- Height of OC; (I1)- Anterior intercondylar distance; (I2)- Posterior intercondylar distance; (A1)- Distance between the anterior tip of occipital condyle and basion; (A2)- Distance between the anterior tip of occipital condyle and opisthion; (P1)- Distance between the posterior tip of occipital condyle and basion; (P2)- Distance between the posterior tip of occipital condyle and opisthion **[Table/Fig-3]:** Inferior view of base of skull showing; (S1)- Sagittal condylar angle; (S2)- Sagittal intercondylar angle.

The following morphometric parameters were studied and analysed:

**1. Linear Parameters [Table/Fig-2]**

**Length of OC:** Maximum anteroposterior distance between anterior and posterior tips of OC.

**Width of OC:** Maximum transverse distance between medial and lateral border of OC.

**Height of OC:** Maximum vertical distance between upper and lower border of medial margin of OC.

**Anterior Intercondylar Distance (AICD):** Distance between anterior tips of right and left OC.

**Posterior Intercondylar Distance (PICD):** Distance between posterior tips of right and left OC.

Distance between the anterior tip of Right OC and Basion (Right AOCB)

Distance between the anterior tip of Left OC and Basion (Left AOCB)

Distance between the anterior tip of Right OC and Opisthion (Right AOCO)

Distance between the anterior tip of Left OC and Opisthion (Left AOCO)

Distance between the posterior tip of Right OC and Basion (Right POCB)

Distance between the posterior tip of Left OC and Basion (Left POCB)

Distance between the posterior tip of Right OC and Opisthion (Right POCO)

Distance between the posterior tip of Left OC and Opisthion (Left POCO)

**2. Angular Parameters [Table/Fig-3]**

**Sagittal Condylar Angle (SCA):** The angle between OC axis and midline passing through basion and opisthion.

**Sagittal Intercondylar Angle (SICA):** The angle between the long axis of right and left OC.

**STATISTICAL ANALYSIS**

The mean and standard deviations of the linear and angular parameters were calculated. The comparison of morphometric dimensions of the right and left sides was performed using Student's t-test and p-value was calculated.

**RESULTS**

**1. Linear Parameters:** Mean length and width of the OC were 22.75±2.90mm and 12.97±1.53mm respectively, while mean height was found to be 9.21±1.22mm. These dimensions of the OC were comparable on both the sides.

Parameters		Range (Min-Max) (mm)	Mean (mm)	Standard Deviation	Significance (p-value)
Occipital Condyle	Length	Right	16.61-27.88	22.90	0.41
		Left	17.89-29.27	22.60	
		Mean	16.61-29.27	22.75	
	Width	Right	10.89-16.39	12.98	0.97
		Left	10.51-15.88	12.97	
		Mean	10.51-16.39	12.97	
	Height	Right	6.02-11.85	9.32	0.12
		Left	6.35-11.16	9.12	
		Mean	6.02-11.85	9.21	
Anterior Intercondylar Distance		12.68-26.82	17.81	2.93	-
Posterior Intercondylar Distance		27.62-49.58	38.91	4.16	-
Distance between AOC & Basion	Right	6.37-15.39	9.74	0.41	
	Left	6.55-12.9	9.56		
	Mean	6.37-15.39	9.65		
Distance between AOC & Opisthion	Right	33.72-43.92	37.53	0.43	
	Left	33.32-43	37.88		
	Mean	33.32-43.92	37.70		
Distance between POC & Basion	Right	22.08-39.35	28.16	0.01	
	Left	23.32-32.16	26.93		
	Mean	22.08-39.35	27.54		
Distance between POC & Opisthion	Right	22.26-31.14	26.78	0.19	
	Left	21.42-33.64	26.17		
	Mean	21.42-33.64	26.48		

**[Table/Fig-4]:** Linear parameters of occipital condyle.

Anterior and posterior intercondylar distances were noted to be 17.81±2.93mm and 38.91±4.16mm respectively.

The distance between Anterior Tip of OC (AOC) and basion was 9.65±1.56mm while the distance between AOC and opisthion was 37.70±2.37mm. Mean distance between Posterior Tip of OC (POC) and opisthion was observed to be 26.48±2.24mm and there was no significant difference among these parameters on both the sides. But the distance between POC and basion was observed to be 27.54±2.81mm and it was significantly greater on the right side (p-value= 0.01).

[Table/Fig-4] summarizes the mean and standard deviation of each linear parameter.

**2. Angular Parameters:** Mean sagittal condylar angle was noted to be 42.57°±4.48 and it was significantly larger on the left side (p-value= 0.001). Mean sagittal intercondylar angle was observed to be 87.97°±8.75 [Table/Fig-5].

Parameters		Range (Min-Max) (degrees)	Mean (degrees)	Standard Deviation	Significance (p-value)
Sagittal Condylar Angle	Right	33.27-53.52	41.10	4.45	0.001
	Left	37.21-53.77	44.04	4.07	
	Mean	33.27-53.77	42.57	4.48	
Sagittal Intercondylar Angle		71.47-109.21	87.97	8.75	

**[Table/Fig-5]:** Angular parameters of occipital condyle.

## DISCUSSION

Lesions of craniovertebral regions are presently managed by lateral approaches. Different forms of lateral approaches to this section have been illustrated, including transfacetal approach, the partial transcondylar approach, the complete transcondylar approach, the extreme-lateral transjugular approach and the transtuberular approach. Majority of these approaches demand resection of the OC partially or completely. The dimensions and orientation of the OC may influence the surgical approach to the lesions of craniovertebral junction [1,3,4].

Different investigators have reported variable morphometry of OC [1,3-13]. These variations may be due to different methods of data assimilation and genetic endowment of different populations. Most of the researchers conducted morphometry of OC in dry skulls, though a few investigators studied cadaveric specimens and CT scans which can yield variable results [1,3,4,6,7,10,12,13]. Similarly, morphometric analysis of the OC of different population can exhibit inconsistent values. In the present study we have endeavoured to analyze OC morphometry and provide a reference database for designing customized implants and screws for Indian population. Such data also allows for comparison with other study populations and enables identification of osteological remains, especially of Indian population.

In present study in Indian population, we found the mean length of OC to be 22.75 mm which was comparable to the findings of Lang J and Hornung G in German population (22.9 mm) and Bozbuga M et al., in Turkish population (23.1 mm) but Yu Z et al., in Chinese population (21.53 mm), Salih AM et al., in Sudanese population (20.66 mm) and Wen HT et al., in American population (21 mm) observed shorter length of OC [5-9]. Other researchers including Naderi S et al., Bozbuga M et al., Kizilkanat ED et al., in Turkish population, Dowd GC et al., in American population, Olivier GE in French population and Guidotti A in Italian population reported higher values than our findings [1,6,10-13] [Table/Fig-6]. The anatomical and biomechanical effects of partial condylectomy are different in long type and short type OC. Greater occipitocervical instability results in short OC with the same amount of partial condylectomy, whereas a long condyle may necessitate more widespread resection for optimum visualization [1].

The mean OC width may engage similar surgical contemplations. In the present study, we found the mean width of OC to be 12.97 mm which was comparable to the finding of Salih AM et al., (12.81mm) in Sudanese population and Kizilkanat ED et al., (13.1mm) in Turkish population [Table/Fig-6] [8,10]. Other researchers reported lesser values suggesting that OC of Indian population are wider [1,3,4,6,12]. Condylectomy in a wider condyle may be more challenging. The height of the OC is also a significant surgical issue. The greater height of OC may facilitate the successful screw placement during occipitocervical fixation. The mean height of the OC was noted to be 9.21 mm in Indian population which was analogous to the other populations [Table/Fig-6].

Anterior and Posterior intercondylar distances illustrate the orientation and convergence of OC which is essential prerequisite for screw placement during occipitocervical fixation. These

parameters were found to be lesser in our study compared to other researchers [Table/Fig-7]. Shorter AICD and PICD may offer challenges during condylectomy by lateral approach.

The distances between the tips of OC and opisthion and basion are also essential anatomical features. The AOCB and AOCO distances were noted shorter in our study than findings of Naderi S et al., and Ozer MA et al., [Table/Fig-7] [1,3]. However, the POCB and POCO distances were comparable to the findings of Naderi S et al., but shorter than those reported by Ozer MA et al., [Table/Fig-7] [1,3]. These values suggest that tips of OC are nearer to the median plane in Indian population which should be considered during application of screws in the OC. Awareness of these findings can prevent injury to the adjacent neurovascular structures.

Researchers	Year	Population	Length (mm)	Width (mm)	Height (mm)
Present study	2016	Indian	22.75	12.97	9.21
Yu Z et al., [7]	2014	Chinese	21.53	-	-
Salih AM et al., [8]	2014	Sudanese	20.66	12.81	-
Ozer MA et al., [3]	2011	Turkish	23.95	11.3	-
Le TV et al., [4]	2011	American	22.4	11.2	9.9
Kizilkanat ED et al., [10]	2006	Turkish	24.5	13.1	-
Naderi S et al., [1]	2005	Turkish	23.6	10.5	9.2
Bozbuga M et al., [6]	1999	Turkish	23.1	11.3	-
Dowd GC et al., [11]	1999	American	30	-	-
Wen HT et al., [9]	1997	American	21	-	-
Lang J and Hornung G [5]	1993	German	22.9	-	-
Guidotti A [13]	1984	Italian	23.7	-	-
Olivier GE [12]	1975	French	23.7	11.5	8.8

**[Table/Fig-6]:** Comparison of occipital condyle dimensions with previous studies.

Resear-chers	AICD (mm)	PICD (mm)	AOCB (mm)	AOCO (mm)	POCB (mm)	POCO (mm)	SCA (degree)	SICA (degree)
Present study	17.81	38.91	9.65	37.70	27.54	26.48	42.57	87.97
Ozer MA et al., [3]	20.9	43.1	11.4	40.5	29.4	29.5	35.5	68.7
Le TV et al., [4]	-	-	-	-	-	-	20.3	-
Kizilkanat ED et al., [10]	22.6	44.2	-	-	-	-	31.4	62.2
Naderi S et al., [1]	21.0	41.6	10.8	39.0	27.8	26.4	29.6	59.3
Bozbuga M et al., [6]	-	30.2	-	-	-	24.3	28.9	57.8
Lang J and Hornung G [5]	-	-	-	-	-	-	-	41.4

**[Table/Fig-7]:** Comparison of occipital condyle dimensions with previous studies.

Parameters (mm)	Present study	Tale AK [14]	Sahoo S [15]	Kalthur SG [16]
Length of OC	22.75	22.01	22.55	22
Width of OC	12.97	11.25	12.73	11
Height of OC	9.21	8.22	-	9
AICD	17.81	21.28	20.31	21
PICD	38.91	40.61	41.17	39
AOCB	9.65	-	11.03	12
AOCO	37.70	-	-	39
POCB	27.54	-	-	27
POCO	26.48	-	27.84	28

**[Table/Fig-8]:** Comparison of occipital condyle dimensions with other Indian studies.

Sagittal condylar angle and sagittal intercondylar angle constitute vital parameters for insertion of screws in the OC. We report higher values of these angles (SCA: 42.57°; SICA: 87.97°) compared to other researchers suggesting that OC of Indian population converge more ventrally [Table/Fig-7]. Wide SCA and SICA may provide additional space for posterolateral approach during condylectomy and may be more useful for reaching the foramen magnum [1]. Further these facts should be reckoned during placement of screws and plates in the OC.

Ultimately, the other Indian researchers found analogous results for length and height of the OC but other parameters were observed to be variable [14-16] [Table/Fig-8] displays the comparison between different Indian studies and provides a range of each parameter for Indians which should be considered during operative procedures of craniovertebral region.

## LIMITATION

We could not incorporate the morphometric parameters of adjacent structures due to the scrupulous nature of manual measurements of 228 OC by digital callipers, which require time and accurate positioning. Further studies are required on the morphometry of foramen magnum, hypoglossal canal, jugular foramen and upper cervical vertebrae to complete the morphometric database for successful surgeries of craniovertebral region.

## CONCLUSION

The present study yielded the characteristics of the Indian OC. We found the wider OC in Indians when compared to other populations. The intercondylar distances were found to be shorter and the tips of the OC were closer to the median plane suggestive of vigilant instrumentation of OC in Indian population. We observed the sagittal condylar angle and sagittal intercondylar angle to be wider in Indians. Hence, awareness of detailed morphometry of the OC can facilitate the successful instrumentation and minimize the neurovascular injuries. We anticipate that our study will be able to provide a reference database for designing implants and for planning the appropriate surgical approach in the OC.

## REFERENCES

- [1] Naderi S, Korman E, Çitak G, Güvençer M, Arman C, Senoğlu M, et al. Morphometric analysis of human occipital condyle. *Clin Neurol Neurosurg.* 2005;107(3):191-99.
- [2] Standring S, Editor. *Gray's Anatomy: The Anatomical Basis of Clinical Practice.* 40<sup>th</sup> Ed. Scotland: Churchill Livingstone Elsevier; 2008.
- [3] Ozer MA, Celik S, Govsa F, Ulusoy MO. Anatomical determination of a safe entry point for occipital condyle screw using three-dimensional landmarks. *Eur Spine J.* 2011;20(9):1510-17.
- [4] Le TV, Dakwar E, Hann S, Effio E, Baaj AA, Martinez C, et al. Computed tomography-based morphometric analysis of the human occipital condyle for occipital condyle-cervical fusion: Clinical article. *Journal of Neurosurgery: Spine.* 2011;15(3):328-31.
- [5] Lang J, Hornung G. The hypoglossal channel and its contents in the posterolateral access to the petroclival area. *Neurochirurgia.* 1993;36(3):75.
- [6] Bozbuga M, Öztürk A, Bayraktar B, Ari Z, Sahinoglu K, Polat G, et al. Surgical anatomy and morphometric analysis of the occipital condyles and foramen magnum. *Okajimas Folia Anatomica Japonica.* 1999;75(6):329-34.
- [7] Yu Z, Ma X, Jiang J, Jin X, Lv F, Wang L, et al. Feasibility of screw placement in the occipital condyle of chinese patients for occipitocervical arthrodesis: a cadaveric study. *Turk Neurosurg.* 2015;25(4):559.
- [8] Salihi AM, Ayad CE, Abdalla EA. Characterization of occipital condyles in sudanese using computerized tomography. *Glo Adv Res J Med Med Sci.* 2014;3(12):437-44.
- [9] Wen HT, Rhoton Jr AL, Katsuta T, Oliveira ED. Microsurgical anatomy of the transcondylar, supracondylar, and paracondylar extensions of the far-lateral approach. *J Neurosurg.* 1997;87(4):555-85.
- [10] Kizilkanat ED, Boyan N, Soames R, Oguz O. Morphometry of the hypoglossal canal, occipital condyle, and foramen magnum. *Neurosurgery Quarterly.* 2006;16(3):121-25.
- [11] Dowd GC, Zeiller S, Awasthi D. Far lateral transcondylar approach: dimensional anatomy. *Neurosurgery.* 1999;45(1):95.
- [12] Olivier GE. Biometry of the human occipital bone. *J Anat.* 1975;120(Pt 3):507.
- [13] Guidotti A. Morphometrical considerations on occipital condyles. *Anthropol Anz.* 1984;117-9.
- [14] Tale AK, Kulkarni PR, Shaikh SI, Fupare SS. Morphometric study of the occipital condyle and its surgical importance. *Int J Anat Res.* 2016;4(1):1802-05.
- [15] Sahoo S, Giri SK, Panda SK, Panda P, Sahu MC, Mohapatra C. Morphometric analysis of the foramen magnum and occipital condyles. *Int J Pharm Sci Rev Res.* 2015;42:198-204.
- [16] Kalthur SG, Padmashali S, Gupta C, Dsouza AS. Anatomic study of the occipital condyle and its surgical implications in transcondylar approach. *J Craniovertebr Junction Spine.* 2014;5(2):71.

### PARTICULARS OF CONTRIBUTORS:

1. Assistant Professor, Department of Anatomy, GS Medical College & Hospital, Pilkhuwa, Hapur, Uttar Pradesh, India.
2. Senior Resident, Department of Anatomy, Maulana Azad Medical College, New Delhi, Delhi, India.
3. Director Professor and HOD, Department of Anatomy, Maulana Azad Medical College, New Delhi, Delhi, India.

### NAME, ADDRESS, E-MAIL ID OF THE CORRESPONDING AUTHOR:

Dr. Sandeep Saluja,  
Flat No. KM00030806, KM-03, Kosmos, Jaypee Greens Wish Town, Sector-134, Noida, Uttar Pradesh, India.  
E-mail: sandeep.saluja1980@gmail.com

FINANCIAL OR OTHER COMPETING INTERESTS: None.

Date of Submission: **Aug 02, 2016**

Date of Peer Review: **Aug 30, 2016**

Date of Acceptance: **Sep 12, 2016**

Date of Publishing: **Nov 01, 2016**