

Interstitial Lung Disease with Chilaiditi Syndrome

KRANTI GARG¹, PRASANTA RAGHAB MOHAPATRA², DEEPAK AGGARWAL³, ROBIN GUPTA⁴, ASHOK KUMAR JANMEJA⁵

ABSTRACT

Chilaiditi sign is the peculiar radiographic presentation of interposition of colon between diaphragm and liver. When associated with symptomatology, it is called as chilaiditi's syndrome. Though rare, respiratory symptoms may be present. In such cases, it becomes difficult to determine if the symptomatology is due to the syndrome only, or there is some underlying lung involvement, until this is specifically considered in the differential diagnosis. We present a male patient, where thorough investigations revealed Interstitial Lung Disease (ILD), along with Chilaiditi sign on chest radiograph. Respiratory symptomatology responded partially to the management of underlying ILD. It is left for discussion, whether the Chilaiditi syndrome was also contributing to the overall clinical presentation or the respiratory complaints were solely due to ILD and Chilaiditi sign was an incidental finding.

Keywords: Chilaiditi sign, Peculiar radiographic presentation, Symptomatology

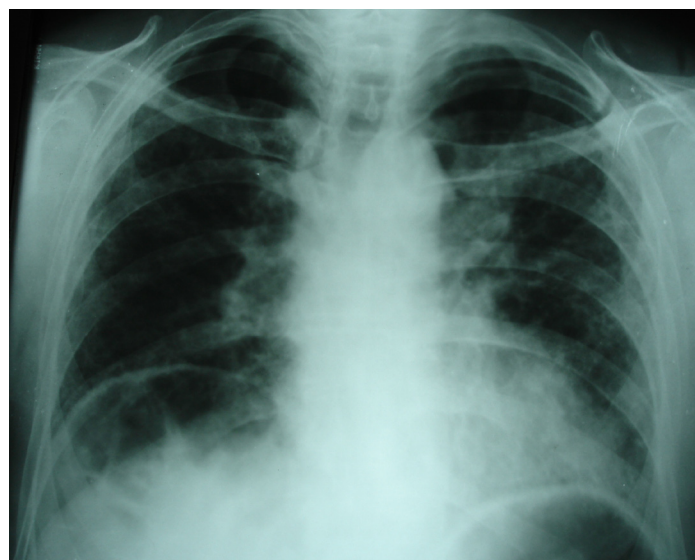CASE REPORT

A 70-year-old male with smoking history of 50 pack years presented to pulmonary medicine department with complaints of gradually progressive shortness of breath for last 3 years, chest discomfort and productive cough for last one month. General physical examination was within normal limits. Examination of the respiratory system revealed bilateral wheeze and bilateral basal crepitus.

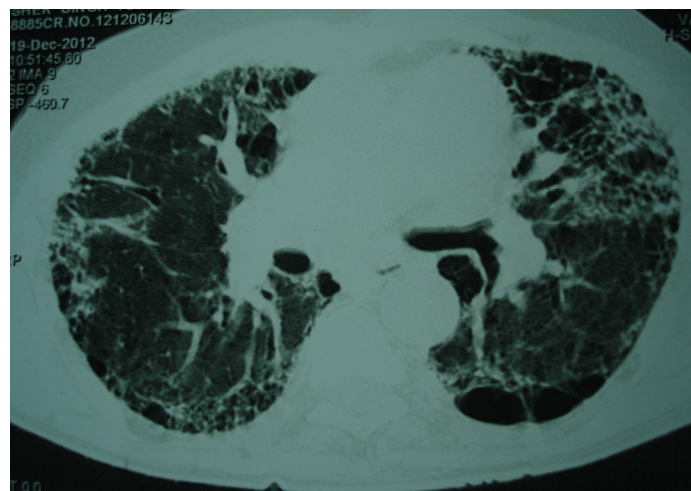Routine haemogram, serum rheumatoid factor, anti-nuclear antibody levels and C-reactive protein were within normal limits. Sputum was negative for acid fast bacilli. Chest radiograph revealed bilateral reticular pattern with hypertranslucent shadow below the right diaphragm suggestive of interposition of gut loops between right hemidiaphragm and liver [Table/Fig-1]. High resolution CT thorax showed intralobular as well as interlobular interstitial thickening with areas of parenchymal fibrosis, honey combing predominantly in subpleural areas bilaterally [Table/Fig-2]. The above features were suggestive of ILD. Also seen was the interposition of colon between liver and diaphragm, colonic haustral pattern was seen suggestive of Chilaiditi sign [Table/Fig-3]. The diagnosis of Chilaiditi

syndrome was made on the basis of presence of symptoms along with chilaiditi sign.

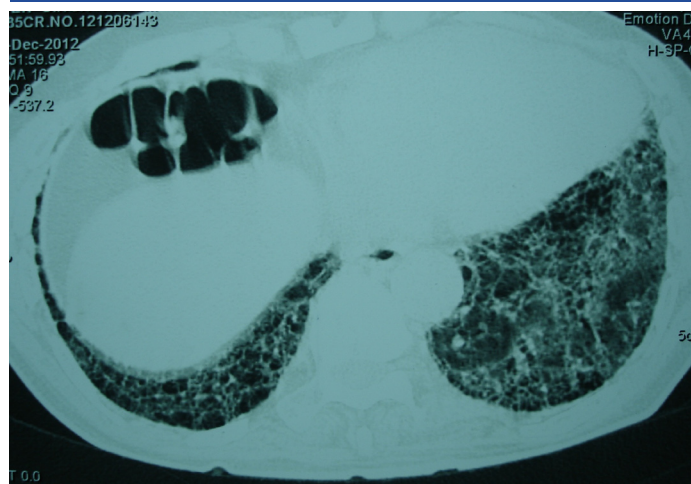
Patient was started on inhaled bronchodilators, intravenous anti-biotics, diuretics, perfenidone and symptomatic treatment for ILD.



[Table/Fig-1]: Chest radiograph showing bilateral reticular pattern of lung parenchyma and hypertranslucent shadow with colonic haustral pattern below the right diaphragm.



[Table/Fig-2]: HRCT thorax showing intralobular as well as interlobular interstitial thickening with areas of honey combing predominantly in bilateral subpleural region.



[Table/Fig-3]: HRCT thorax showing interstitial fibrosis along with interposition of colon between liver and diaphragm, colonic haustral pattern is seen anteriorly through right lobe of liver showing Chilaiditi sign.

Pulmonary Rehabilitation was also given. Patient improved partially with treatment and was discharged in a stable condition after a week. Patient was in a clinically stable condition at follow-up at 3 months.

DISCUSSION

The radiographic presentation of interposition of colon between diaphragm and liver is labelled as Chilaiditi sign. It is usually asymptomatic, rare and an incidental finding on chest radiographs. Incidence ranges from 0.1 to 1%. When it is associated with symptomatology, it is called as chilaiditi's syndrome [1]. The associated symptoms can be abdominal pain, distension, vomiting, anorexia, constipation etc [2]. Respiratory distress [3], chest pain [4], volvulus of colon and acute intestinal obstruction are its rare manifestations.

In literature, Chilaiditi syndrome has been reported in association with chronic lung conditions (2.7%) [5]. There is a single case report of its association with pulmonary fibrosis in an obese patient [4]. Its association with chronic lung disease has been postulated to be due to lung disease associated with enlarged lower thoracic outlet leaving adequate space for intrusion of adjacent bowel segments [5]. The liver is pushed downwards facilitating the interposition of colon between diaphragm and liver [3]. The treatment of Chilaiditi syndrome is conservative targeting at abdominal and respiratory symptoms and include, high fibre diet, fluid supplementation and stool softeners [3].

Since Chilaiditi syndrome can cause respiratory symptoms and respiratory distress and is also reported to be associated with chronic lung diseases, it is important to exclude pulmonary involvement as one of the causes of chronic respiratory symptoms rather than attributing the respiratory symptomatology to be due to

Chilaiditi syndrome only, as was our case where detailed work up revealed the chronic lung disease as well. This differentiation is also important from management point of view as respiratory distress due to Chilaiditi's syndrome only will respond to conservative management, but the patients who have underlying lung involvement need treatment for the same. The diagnosis of an underlying ILD along with Chilaiditi syndrome and its subsequent treatment, led to partial clinical improvement in our patient.

CONCLUSION

The extent to which ILD contributed to the respiratory symptoms cannot be measured. ILD is a chronic lung condition and the extent of response to treatment is variable, as was seen in our patient who improved partially when treated for underlying ILD. Similarly, the exact extent of contribution of Chilaiditi syndrome, if any, to the respiratory symptomatology also cannot be gauged, as no clear cut distinguishing symptoms to demarcate the two entities from each other are available. Contribution of either of the two entities to the respiratory symptomatology and the subsequent management in such associations is left for open discussion.

REFERENCES

- [1] Yagnik VD. Chilaiditi sign. *Lung India*. 2010;27:190.
- [2] Matthews J, Beck GW, Bowley DM, Kingsnorth AN. Chilaiditi syndrome and recurrent colonic volvulus: A case report. *J R Nav Med Serv*. 2001;87:111-12.
- [3] Dogu F, Reisli I, Ikinçiogullari A, Fitoz S, Babacan E. Unusual cause of respiratory distress: Chilaiditi syndrome. *Pediatrics International*. 2004;46:188-90.
- [4] Hotoleanu C, Fodor D, Jurj C, Iancu M, Rusu ML. Sindrom Chilaiditi. *Medicina Moderna*. 2008;15(5):241.
- [5] Vessal K, Borhanmanesh F. Hepatodiaphragmatic interposition of the intestine (Chilaiditi's syndrome). *Clin Radiol*. 1976;27(1):113-16.

PARTICULARS OF CONTRIBUTORS:

1. Assistant Professor, Department of Pulmonary Medicine, D block, Level 5, Government Medical College and Hospital, Chandigarh, India.
2. Professor, Department of Pulmonary Medicine, AIIMS, Bhubaneswar, India.
3. Associate Professor, Department of Pulmonary Medicine, Government Medical College and Hospital, Chandigarh, India.
4. Senior Resident, Department of Pulmonary Medicine, Government Medical College and Hospital, Chandigarh, India.
5. Professor and Head, Department of Pulmonary Medicine, Government Medical College and Hospital, Chandigarh, India.

NAME, ADDRESS, E-MAIL ID OF THE CORRESPONDING AUTHOR:

Dr. Kranti Garg,
Assistant Professor, Department of Pulmonary Medicine, Government Medical College and Hospital,
Sector 32, Chandigarh, India.
E-mail: drkrantigarg@yahoo.com

FINANCIAL OR OTHER COMPETING INTERESTS: None.

Date of Submission: **Aug 16, 2016**

Date of Peer Review: **Sep 20, 2016**

Date of Acceptance: **Oct 10, 2016**

Date of Publishing: **Dec 01, 2016**