

JOURNAL OF CLINICAL AND DIAGNOSTIC RESEARCH

How to cite this article:

ANUPAMA B, PUTHRAN N, HEGDE V. CHOROIDAL DETACHMENT IN AN ELDERLY PATIENT WHO WAS TREATED POST OPERATIVELY WITH TOPICAL DORZOLAMIDE AND TIMOLOL COMBINATION. *Journal of Clinical and Diagnostic Research* [serial online] 2010 October [cited: 2010 October 31]; 4:3230-3232.

Available from

http://www.jcdr.in/article_fulltext.asp?issn=0973-709x&year=2010&volume=&issue=&page=&issn=0973-709x&id=910

CASE REPORT

Choroidal Detachment In An Elderly Patient Who Was Treated Post Operatively With Topical Dorzolamide And Timolol Combination

ANUPAMA B*,PUTHRAN N*,HEGDE V*

ABSTRACT

We report here, a case of choroidal detachment in a 76 year old man who underwent right eye cataract surgery. He was being treated for bilateral Primary open angle glaucoma in the postoperative period with a combination of timolol and dorzolamide, as the intraocular pressure remained poorly controlled with timolol. He developed choroidal detachment with the use of the Dorzolamide and timolol combination. This case highlights the fact that antiglaucoma medication in a previously operated eye causes higher risk for the development of choroidal detachment, especially in elderly patients.

Key-words: Dorzolamide and timolol, Choroidal detachment, Primary open angle glaucoma, cataract surgery, elderly.

Key Message:

All elderly patients with prior intraocular surgery, receiving topical antiglaucoma drugs, should be routinely examined for choroidal effusions.

*Department of Ophthalmology, Yenepoya Medical College, Deralakatte, India.

Corresponding Author:

Dr Anupama B ,Department of Ophthalmology
Yenepoya Medical College, Deralakatte, India.
anupamabappal@gmail.com
+91-9448388924

Introduction

It is well known that all intra ocular surgeries run the risk of post operative choroidal detachments. Recently, there have been a few reports implicating the newer potent IOP lowering agents in the development of choroidal detachments. We report here, a case of choroidal detachment following the use of topical dorzolamide and timolol in an eye which was operated for cataract.

Case History

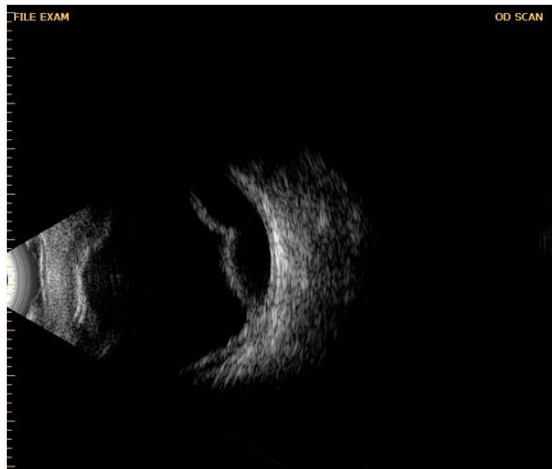
A 70 year old hypertensive and diabetic gentleman on Tab Atenolol 25 mg and oral hypoglycaemic agents since five years, reported with diminution of vision in the right eye. Both eyes had grade two nuclear sclerosis, while the right eye had a dense

posterior subcapsular cataract in addition. The posterior segment view of the right eye was markedly hazy, but the left eye showed a cup disc ratio of 0.5:1, with the presence of laminar dot sign and thinning of the superior and inferior neuroretinal rims. There was no evidence which was suggestive of diabetic retinopathy. The intra-ocular pressures were 20 mm Hg in each eye and gonioscopy showed open angles in all the quadrants of both the eyes. Perimetry of the right eye could not be done, while the visual field of the left eye was unreliable. The patient underwent an uneventful manual small incision cataract surgery by using a can opener capsulotomy and a posterior chamber intraocular lens implantation in the right eye.

The post operative vision in the right eye was 20/20. Neither wound leak nor shallowing of the anterior chamber was detected. There was no evidence of any uveal inflammation or pupillary block either. The posterior segment of the right eye could be visualized at this time and examination revealed a cup disc ratio of 0.7:1 with nasalization of the vessels and laminar dot sign. The superior and inferior neuroretinal rims were thinned. The

intraocular pressures were recorded as 28mm Hg in the right eye and 23 mm Hg in the left eye. The visual fields showed the presence of arcuate scotomas in both eyes. Antiglaucoma treatment was therefore initiated with Timolol eye drops twice a day. The intraocular pressure remained unchanged in both eyes despite two weeks of treatment with timolol monotherapy. Topical dorzolamide was therefore added for both the eyes.

Follow up after four weeks showed the intraocular pressure to be unrecordably low in the right eye and 14 mm Hg in the left eye. Posterior segment examination revealed a 360 degrees choroidal detachment in the right eye, which was documented by Ultrasound B scan ([Table/Fig 1-B] scan of the right eye showing choroidal detachment). Following discontinuation of the antiglaucoma medications, the choroidal detachment settled within two weeks, while the IOP improved to 10 mm Hg in the right eye. No choroidal effusion has developed in the left eye to date.



[Table/Fig 1]: B scan ultrasound of the right eye showing choroidal detachment four weeks after initiation of therapy with topical combination of dorzolamide and timolol

Discussion: Choroidal detachment is known to occur in the immediate post operative period after intraocular surgery. Recently, there have been a few reports which implicate that the post operative use of Latanoprost, Dorzolamide and a combination of Dorzolamide with Timolol causes Choroidal detachment in previously operated eyes.[1],[2],[3] However, there is only a single report on the abrupt development of an extensive choroidal detachment after initiation

of dorzolamide therapy in a surgically untreated eye with primary open-angle glaucoma.[4]

Our patient initially received Timolol post operatively for open angle glaucoma. The intraocular pressure in both eyes remained unchanged despite using topical Timolol for two weeks. The concurrent use of systemic beta blockers is thought to have suppressed the action of the topically administered beta blocker. [5] Since the initial antiglaucoma therapy proved to be ineffective, alternative medication in the form of adjuvant topical Dorzolamide was prescribed. Four weeks later, the choroidal detachment was detected in the right eye only. Ocular examination of the right eye ruled out wound leak or significant post operative inflammation as possible causes for the Choroidal detachment, thus suggesting that the antiglaucoma drugs were the most likely cause for the choroidal detachment which resulted from the drug induced ocular hypotony.

The patient was using the combination of Timolol and Dorzolamide in both the eyes. Yet, Choroidal Detachment developed only in the operated eye. Most other reports also mentioned Choroidal Detachment as occurring only in the operated eyes which received antiglaucoma medication. There is also a report which states that Choroidal detachment developed in an operated eye, although it was the fellow eye which was receiving topical antiglaucoma medication. [6]

Interestingly, a review of literature has shown that the development of choroidal detachments tends to occur following the use of antiglaucoma medications only in eyes which have previously undergone intraocular surgery. The surgery may have been performed at any time prior to the use of the drugs, ranging from a few days upto even twenty years.[1],[2],[3],[5],[6],[7],[8]

Although we did not find any studies showing a correlation between age and the development of post operative Choroidal Detachment, all the patients who were reported so far, were elderly, except in one case, where the patient was 36 years of age, who had post traumatic glaucoma in the left eye. [8] It therefore appears that the ageing eye with prior

intraocular surgery is vulnerable to drug induced hypotony, resulting in choroidal detachment.

Fortunately, the choroidal detachments occurring secondary to ocular hypotony generally resolve after simple cessation of the causative drugs. In our patient, the Choroidal detachment completely resolved within two weeks of stoppage of the antiglaucoma medications.

This case highlights the fact that one should be cautious while administering newer antiglaucoma medications in elderly patients with a history of prior intraocular surgery. We therefore recommend that all such patients receiving antiglaucoma drugs should be routinely examined for choroidal effusions.

References

- [1] Gupta R, Vernon SA. Choroidal detachment following extracapsular cataract extraction in a patient treated with latanoprost. *Br J Ophthalmol* 2001; 85:1268.
- [2] Mitchell S, L Jay Katz, Richard P Wilson. Topical dorzolamide-induced hypotony and ciliochoroidal detachment in patients with previous filtration surgery. *Arch Ophthalmol* 1996; 114:1031–32.
- [3] Sharma T, Salmon JF. Hypotony and Choroidal Detachment as a Complication of Topical Combined Timolol and Dorzolamide. *J Ocul Pharmacol Ther* 2007; 23:202-5.
- [4] Goldberg S, Gallily R, Bishara S, Blumenthal EZ. Dorzolamide – induced choroidal detachment in a surgically untreated eye. *Am Journal Ophthalmol* 2004; 138:285- 6.
- [5] Schuman JS. Effect of systemic beta –blocker therapy on the efficacy and safety of topical brimonidine and timolol. *Ophthalmology* 2000; 107:1171-77.
- [6] Horgan N, Kirwan RP, O’Brien CJ .Choroidal detachment associated with latanoprost use in fellow eye. *Ann Pharmacother* 2007; 41:161-62.
- [7] Davani, Delbosc, Royer, Kantelip. Choroidal Detachment induced by dorzolamide 20 years after cataract surgery. *Br J Ophthalmol* 2002; 86: 1457-58.
- [8] Sodhi PK, Sachdev MS, Gupta A, Verma LK, Ratan SK. Choroidal detachment with topical latanoprost after glaucoma filtration surgery. *Ann Pharmacother* 2004; 38:510-11.