

JOURNAL OF CLINICAL AND DIAGNOSTIC RESEARCH

How to cite this article:

CHOWTA NITHYANANDA K, ARUN S, BIPIN P, FAZIL A. CHRONIC THROMBOEMBOLIC PULMONARY ARTERY HYPERTENSION WITH DEEP VEIN THROMBOSIS DUE TO PROTEIN S DEFICIENCY. *Journal of Clinical and Diagnostic Research* [serial online] 2010 October [cited: 2010 October 15]; 4:3217-3220.

Available from

http://www.jcdr.in/article_fulltext.asp?issn=0973-709x&year=2010&volume=&issue=&page=&issn=0973-709x&id=945

CASE REPORT

Chronic Thromboembolic Pulmonary Artery Hypertension With Deep Vein Thrombosis Due To Protein S Deficiency

CHOWTA NITHYANANDA K*, ARUN S**, BIPIN P***, FAZIL A****

ABSTRACT

A 30 year old male presented with the complaint of progressive dyspnoea. Cardiovascular examination showed tachycardia and loud second sound in the pulmonary area. ECG showed T wave inversion in lead III and chest X-ray showed dilatation of the pulmonary artery. Echocardiography showed mildly dilated right atrium/right ventricle, mild tricuspid regurgitation and moderate pulmonary arterial hypertension. Venous Doppler of the bilateral lower limbs showed deep vein thrombosis of both the lower limbs. HRCT (high resolution CT) showed pleural thickening in the apical segment of the left upper lobe and scattered ground glass attenuation in the apical basal segment of both the lower lobes, which were suggestive of thromboembolism. CECT (contrast enhanced CT) of chest showed pulmonary artery thrombosis of the left lower lobe segmental and interlobar artery. Protein S activity was 25 % (normal range: 77-143%), protein C activity was 82 % (normal range: 70-130%) and antithrombin III was 119 (normal range: 80-120).

*MD, Additional Professor of Medicine, KMC Mangalore, Manipal University; **MD, Assistant Professor of Medicine, KMC Mangalore, Manipal University; ***MD, Assistant Professor of Medicine, KMC Mangalore, Manipal University; ****MD, Assistant Professor of Medicine, KMC Mangalore, Manipal University, Department(s) and institution(s) : Medicine, Kasturba Medical College, Mangalore, Manipal University

Corresponding Author

Dr. Nithyananda Chowta K
Associate Professor
Department of Medicine,
Kasturba Medical College, Mangalore, Manipal University
Mobile: 09845579112
E-mail: knchowta@yahoo.com

Introduction:

The protein C (PC) and protein S (PS) systems are the major regulatory systems of haemostasis. Protein C and protein S are vitamin K dependent proenzymes which are synthesized in the liver. The thrombin- thrombomodulin complex on the surface of endothelial cells is the site for the interaction with the proteins C and S. Protein C becomes activated after binding to these complexes. Protein S acts as a cofactor in this process. In contrast to PC, PS circulates in plasma in two forms. Approximately 60% of it is bound non-covalently to the complement component C4b binding protein; whereas, the remaining 40% is free. Only free PS has the APC cofactor activity[1]. Activated protein C

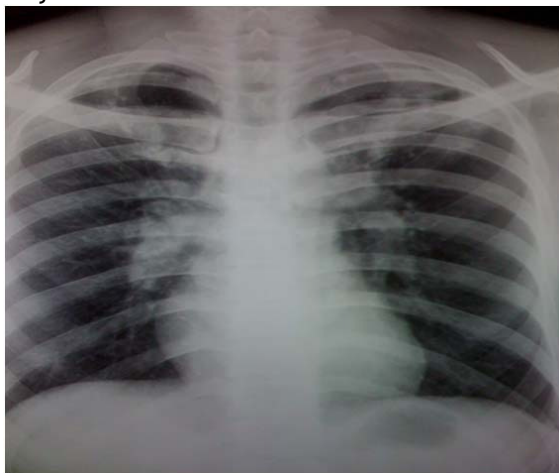(APC) inhibits factor VIIIa and factor Va, thus exhibiting its anticoagulant property and also

enhances fibrinolysis through the inhibition of the plasminogen activator inhibitor. PS interacts with the complement system and may play a role in the phagocytosis of apoptotic cells. The impact of PS deficiencies on these non anticoagulant roles is not yet known. The prevalence of hereditary PS deficiency ranges from 0.03% to 0.13%. [2],[3]

Case report:

A 30 year old male presented with complaints of dyspnoea on exertion, of 3 week's duration. The dyspnoea was of grade I-III, it was gradual in onset and was progressive. There was no history of orthopnoea/ paroxysmal nocturnal dyspnoea or history of diurnal or positional variation. The patient did not have chest pain, palpitations, syncope, cough, wheezing, fever, loss of weight or loss of appetite.

[Table/Fig 1] Chest X-ray: Dilatation of the pulmonary artery



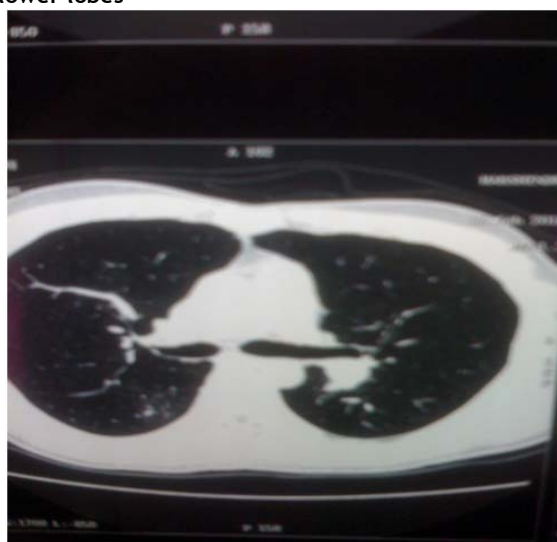The patient gave a history of chest pain, six weeks prior to the onset of the present complaints. The chest pain was of moderate intensity in the left lower chest, it was pricking in nature and lasted for 15 minutes. The pain was aggravated with respiration and was relieved spontaneously without medication. The chest pain was not radiating and was not associated with sweating, syncope, breathlessness or vomiting. There was no history of trauma/tuberculosis/asthma/hypertension/ diabetes mellitus/ ischaemic heart diseases/rheumatic or congenital heart diseases. There was no history of similar complaints in the past and also, no history of alcohol/smoking. The patient also gave a history of swelling in the calf, with pain 3 weeks prior to the onset of the present illness.

On physical examination, the patient's blood pressure level was found to be 100/84 mm Hg, his pulse rate was 102/min and his body mass index was 23.85kg/m². Respiratory, pulmonary, neurological, abdominal, and skin examination findings were unremarkable. Cardiovascular examination showed loud second sound in the pulmonary area.

ECG showed T wave inversion in lead III. Chest X-ray showed dilatation of the pulmonary artery (Fig 1). Echocardiography showed mildly dilated right atrium/right ventricle, mild tricuspid regurgitation and moderate pulmonary arterial hypertension. Venous Doppler of the bilateral lower limbs showed deep vein thrombosis (DVT) of the distal saphenous vein, the long saphenous vein of right lower limb, the distal saphenous vein and the popliteal vein of the left lower limb. HRCT (high resolution CT) showed pleural thickening in the apical segment of

the left upper lobe and scattered ground glass attenuation in the apical basal segment of both the lower lobes, which were suggestive of thromboembolism (Fig 2). CECT (contrast enhanced CT) of chest showed pulmonary artery thrombosis of the left lower lobe segmental and interlobar artery (Fig3a and Fig 3b). Haemogram, erythrocyte sedimentation rate, blood sugar, kidney function tests, liver function tests, serum electrolytes and urine analysis were normal. Prothrombin time was normal (T-16seconds, C-14.8seconds, and INR-1). CPK-MB and troponin T were also normal. Protein S activity was 25 % (normal range: 77-143%), protein C activity was 82% (normal range: 70-130%) and antithrombin III was 119 (normal range: 80-120). The levels of free and bound protein S could not be performed due to the patient's financial constraints.

[Table/Fig 2] HRCT: Pleural thickening in the apical segment of left upper lobe and scattered ground glass attenuation in apical basal segment of both lower lobes



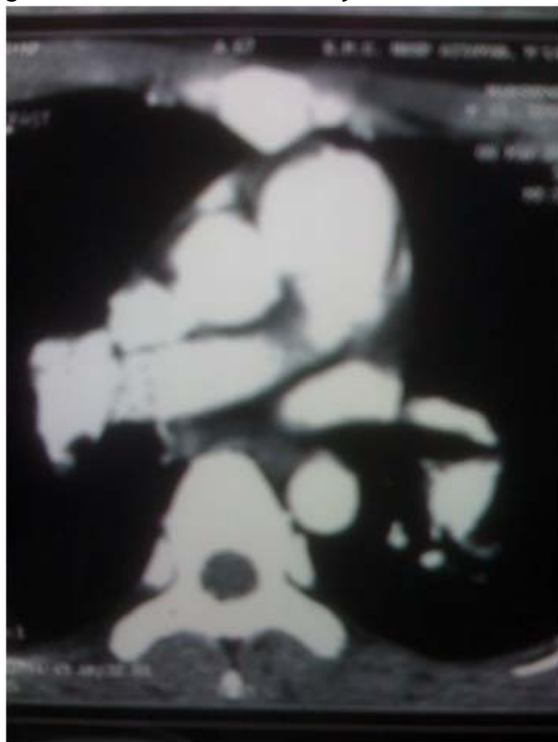
Based on these clinical findings and laboratory results, the patient was diagnosed to have chronic thromboembolic pulmonary artery hypertension with deep vein thrombosis due to protein S deficiency. The patient was started on warfarin 5mg daily and sildenafil 25mg daily.

Discussion:

PS deficiency may be quantitative or qualitative. The prevalence of hereditary PS deficiency in the general population remains largely unknown, probably because of its rarity and the difficulty of a correct diagnosis. However, a study in 3788 healthy Scottish blood donors showed a prevalence of

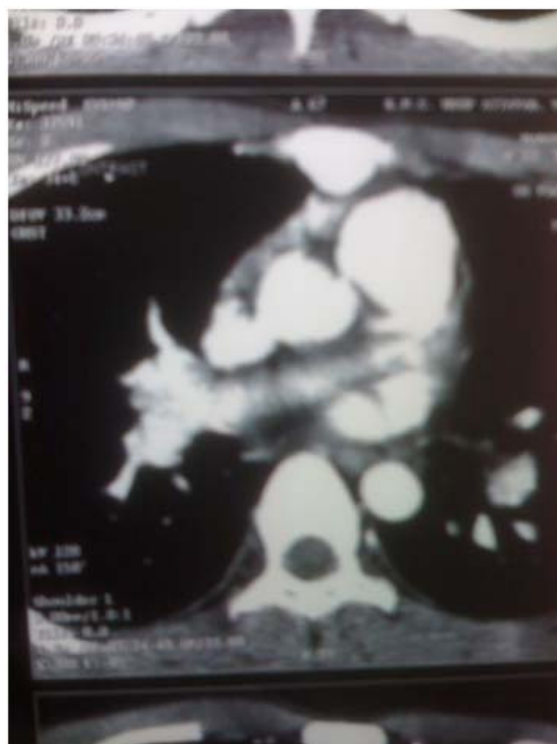hereditary PS deficiency ranging from 0.03% to 0.13%.[4] PS deficiency can be genetic (hereditary) or acquired.

[Table/Fig 3a]: CECT -CHEST
Pulmonary artery thrombosis of left lower lobe segmental and interlobar artery



In 1984, the first clinical report on PS deficiency as a risk factor for venous thromboembolism (VTE), was published.[5] Homozygous or compound heterozygous PS deficiency, though extremely rare, usually presents neonatally with massive VTE or purpura fulminans. Without treatment, this will be most likely to be lethal. Heterozygous PS deficiency is an established risk factor for VTE, but with incomplete and variable penetrance. The timing of presentation is usually before 50 years of age and the life-time risk of VTE is similar in men and women. However, probably because of the use of oral contraceptives and pregnancy or puerperium, PS-deficient women seem to be at a greater risk of developing VTE early in life (<30 years) as compared with PS-deficient men[2].

[Table/Fig 3b]: CECT -CHEST
Pulmonary artery thrombosis of left lower lobe segmental and interlobar artery



The acquired causes of protein C and S deficiencies are seen in acquired illnesses like liver disease, DIC, therapy with L-asparaginase and coumarin and acute severe bacterial infections, etc. The homozygous variety is rare and these patients have neonatal purpura fulminans[2].

Clinically, patients with protein C and S deficiencies are at an increased risk for venous thromboembolism (VTE), occasional arterial thrombosis, neonatal purpura fulminans, childhood stroke and even portal vein thrombosis. Women may have foetal loss as their only manifestation. 25% of the patients may experience arterial thrombosis, including stroke. Mortality is caused usually due to pulmonary embolism.[6],[7]

Generally, there are two types of PS assays: Immunoassays for the determination of total and free PS levels and clotting assays (functional assay) to measure the APC cofactor activity. APC cofactor activity determination results in a high rate of false-positive results because of the presence of APC resistance and high levels of prothrombin, FVIIIa and FVIIa. C4b-binding protein is an acute phase reactant, often elevated in thromboembolism, resulting in reduced free Protein S levels. Consequently, the measurement of protein S levels in acute thrombosis may yield misleading results.

Immunological assays measure the levels of either total or free protein S. Immunological assays are useful in evaluating patients who have coexisting APC resistance [2].

The initial treatment consists of unfractionated heparin or LMWH, which is overlapped with warfarin until an international normalized ratio of 2.0–3.0 is reached on two consecutive days. Warfarin treatment should be considered for up to 2 years and even life-long in the presence of concomitant thrombophilic defects, whereas it should be usually continued for 3–6 months after the first VTE in patients without thrombophilia. Asymptomatic patients should not be treated, but should be considered for prophylaxis when they experience high-risk procedures such as surgery. Patients with massive thrombosis or pulmonary embolism require thrombolytic therapy[2].

References:

- [1] Dahlback B. The tale of protein S and C4b-binding protein, a story of affection. *Thromb Haemost* 2007;98: 90-6.
- [2] Tenkate MK, van derMeer J. Protein S deficiency: a clinical perspective. *Haemophilia* 2008; 14: 1222-1228
- [3] Rezende SM, Simmonds RE, Lane DA. Coagulation, inflammation, and apoptosis: different roles for protein S and the protein S-C4b binding protein complex. *Blood* 2004; 103: 1192-201.
- [4] Dykes AC, Walker ID, McMahon AD, Islam SI, Tait RC. A study of Protein S antigen levels in 3788 healthy volunteers: influence of age, sex and hormone use, and estimate for prevalence of deficiency state. *Br J Haematol* 2001; 113: 636-41.
- [5] Schwarz HP, Fischer M, Hopmeier P, Batard MA, Griffin JH. Plasma protein S deficiency in familial thrombotic disease. *Blood* 1984; 64: 1297-300.
- [6] Brouwer JL, Veeger NJ, Kluin-Nelemans HC, van derMeer J. The pathogenesis of venous thromboembolism: evidence for multiple interrelated causes. *Ann Intern Med* 2006; 145: 807-15.
- [7] Van Vlijmen EF, Brouwer JL, Veeger NJ, Eskes TK, de Graeff PA, van derMeer J. Oral contraceptives and the absolute risk of venous thromboembolism in women with single or multiple thrombophilic defects: results from a retrospective family cohort study. *Arch Intern Med* 2007; 167: 282-9.