

Psychosis in a Case of Dandy-Walker Syndrome: A Case Report

RIPU DAMAN DAWRA¹, SAGAR KARIA², NILESH SHAH³, AVINASH DESOUSA⁴

ABSTRACT

Dandy Walker Syndrome (DWS) is a congenital malformation with brain abnormalities, intellectual disabilities, epilepsy and visible structural changes in particular brain structures. We present here a case of psychosis in an 18 year old male with DWS, epilepsy and intellectual disability. The purpose of this paper is to discuss the clinically relevant issues, psychopharmacological issues, neuropsychiatric manifestations and consultation liaison issues involved.

Keywords: Congenital malformation, Dandy walker variant, Psychosis

CASE REPORT

An 18-year-old, single, unemployed male was brought by his mother with chief complaints of repeated falls and headache since the past one month, decreased self care since six days, angry-abusive behaviour since two days. The patient was a known case of seizure disorder and intellectual impairment. His last seizure episode was a month prior to presentation. The patient was born preterm at seven months and was kept in an incubator and given multiple blood transfusions 4-5 days after birth (details of which were unknown). The patient was apparently alright till the age of three years when he started having episodes of loss of consciousness associated with frothing from mouth for which he was taken to a hospital and diagnosed as a case of seizure disorder and started on treatment (sodium phenytoin). The patient dropped out of school at 5th standard as he continued to have episodes of seizures and academic difficulties. The patient had difficulty in calculation and needed assistance in activities of daily living. The patient used to do odd jobs like working as helper in shop or sometimes as daily wage laborer to earn for himself.

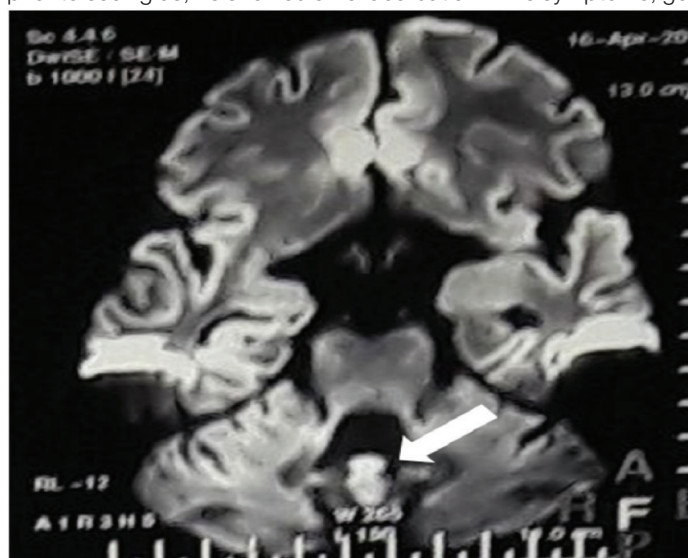
A month prior to presentation, he started having sudden onset episodes of generalized headache which were severe, continuous and sometimes associated with non-projectile vomiting. Headache did not respond to medications given by the family physician and the patient was brought to our hospital and suspected to have a Viral encephalopathy and started on by the medical team on intravenous mannitol, dexamethasone, phenytoin, ceftriaxone, vancomycin and acyclovir. Magnetic Resonance Imaging (MRI) study of the brain revealed inferior cerebellar vermian hypoplasia with fourth ventricle seen communicating with cisterna magna through a keyhole defect suggestive of Dandy Walker variant [Table/Fig-1,2].

The patient improved symptomatically on the above treatment and was discharged after two weeks with advice to continue oral medication like sodium phenytoin 100 mg thrice a day, ondansetron 4 mg twice a day, pantoprazole 40 mg once a day, calcium supplements and Carbamazepine 200 mg thrice a day.

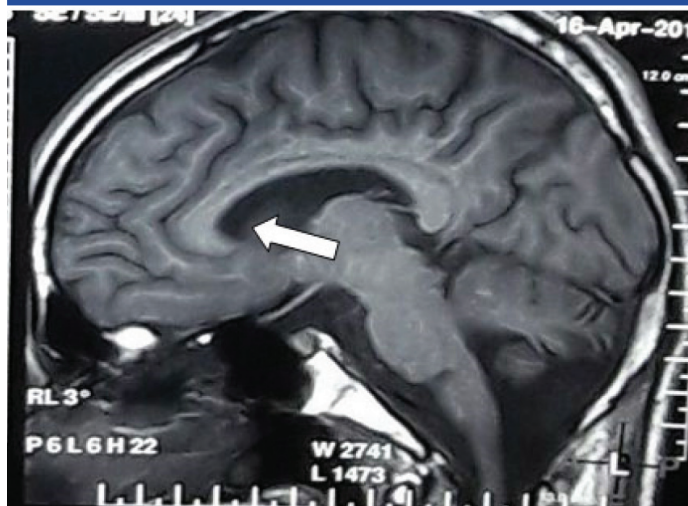
The patient was maintained on same and after about a month, without any apparent reasons, he started showing altered behaviour in form of angry-abusive behaviour towards his mother and others.

He showed decreased self care and stopped bathing. He had difficulty in eating food by self and would not allow his mother to

leave the house. He also had episodes of inappropriate laughter and crying. He occasionally complained of severe headache, would lie down on the floor and start banging his head on floor. Since a day prior to seeing us, he showed an exacerbation in his symptoms, got



[Table/Fig-1]: MRI image showing atrophy of the cerebellum and cerebellar vermis (arrow).



[Table/Fig-2]: MRI image showing enlarged ventricles (arrow).

violent and urinated on the mother, would not wear proper clothes and was brought to our hospital. There is no history of psychiatric illness in family.

Patient had difficulty in performing in school and would prefer playing with children younger to him. Mother informed us that her child was labeled as having mental retardation but she had lost the (Intelligent Quotient) report. The patient was conscious, not cooperative and minimally communicative. Eye contact was initiated but not maintained. Attention was ill sustained and the patient was fidgety. The patient was in an unkempt state and unshaven but was oriented to time, place and person. Thought assessment was not possible and rest of the mental status examination was not possible either. The patient was started on oral risperidone 2 mg per day in divided doses along with trihexyphenidyl 2 mg a day. The medication was continued till his last follow up which was after four weeks of start of treatment. He showed 90% improvement in two weeks i.e., his aggressive behaviour reduced, he started eating by self and episodes of inappropriate laughter decreased in frequency. He was maintained on the medications as mentioned above. He has not followed up thereafter though we have tried to contact him via the social work department.

DISCUSSION

DWS malformation is a congenital malformation that affects brain development and has a prevalence of 1 out of 25000-30000 live births. The malformation includes the complete or partial absence of the cerebellar vermis, cyst formation in posterior fossa of skull, and increased size and pressure in ventricles which may lead to hydrocephalus [1]. Children with DWS may present at younger ages with hydrocephalus and intellectual disability ranging from mild to severe intellectual impairment and may also show global developmental delays [2]. Less commonly the syndrome may be associated with agenesis of the corpus callosum and occasional encephalocele due to defective neuronal migration [3].

Three main types of DW complexes have been identified viz., [4]

DWS which is characterized by an enlargement of the posterior fossa, large cystic dilatation of the fourth ventricle, total or partial agenesis of the vermis, and a highly-positioned tentorium with elevated straight sinus;

Dandy Walker Variant which includes a cystic dilatation of the fourth ventricle and hypoplasia of the inferior portion of the vermis without enlargement of the posterior fossa; and

Mega Cysterna Magna, where the compressive atrophy of the vermis is associated with cystic enlargement of the cisterna magna, communicating freely across the foramen of Luschka and Magendie with the fourth ventricle and subarachnoid space.

Our case falls under the first category DWS. Many isolated case reports of psychosis in adult patients with DWS exist in literature while reports in adolescents are few [5-7]. There have been case reports of psychosis in DWS responding to antipsychotics [8], but also there has been report of patient not improving on many different antipsychotics and had to be given long acting injectable [9]. The psychiatric reference may be taken if the patient is aggressive and/or violent as well as for the management of psychotic symptoms, both of which shall respond well to antipsychotics.

Neurobiological explanations have implicated the cerebellum in the genesis of psychosis in this population [10]. Researchers have also supported a theory that implicates a cortico-thalamic-cerebellar neural circuit [11].

CONCLUSION

A sound consultation liaison approach between paediatricians, neurologists and psychiatrists is essential when treating a case of DWS. Relatives of patients with DWS need to be psycho educated about the propensity of these patients developing psychiatric disorders. The present case illustrates the need for clinicians to be vigilant about the neuropsychiatric complications like psychosis that may occur in a case of DWS.

REFERENCES

- [1] Ndu Ik, Chinawa JM, Chikani M, Ibekwe R, Aronu AE, Edelu BO, et al. Dandy Walker malformation (variant): late presentation with childhood blindness. *Niger J Paed.* 2015;42(1):73-75.
- [2] Yüceer N, Mertol T, Arda N. Surgical treatment of 13 pediatric patients with Dandy-Walker syndrome. *Pediatr Neurosurg.* 2007;43(5):358-63.
- [3] Vialard F, Robyr R, Hillion Y, Gomes DM, Selva J, Ville Y. Dandy-Walker syndrome and corpus callosum agenesis in 5p deletion. *Prenatal Diagn.* 2005 25(4):311-13.
- [4] Mataka G, Yamanouchi H, Arisaka O. Dandy-Walker syndrome and chromosomal abnormalities. *Cong Anomal.* 2007;47(4):113-18.
- [5] Ryan M, Grenier E, Castro A, Nemeroff CB. New-onset psychosis associated with Dandy-Walker variant in an adolescent female patient. *J Neuropsychiatr Clin Neurosci.* 2012;24(2):241-46.
- [6] Ferentinos PP, Kontaxakis VP, Havaki-Kontaxaki BJ, Pappas KG, Pappa DA, Soldatos CR. Refractory psychosis and prominent cognitive deficits in a patient with mega-cisterna magna. *Prog Neuro psychopharmacol Biol Psychiatry.* 2007;31(2):561-63.
- [7] Rohanachandra YM, Dahanayake DM, Wijetunge S. Dandy-Walker Malformation Presenting with Psychological Manifestations. *Case Reports in Psychiatry.* 2016;2016:9104306.
- [8] Prakash R, Singh LK, Kour J, Mishra B, Lakra A. Psychiatric comorbidities in Dandy-Walker variant disorder. *J Neuropsychiatr Clin Neurosci.* 2009;21(4):477-79.
- [9] Williams AJ, Wang Z, Taylor SF. Atypical psychotic symptoms and Dandy-Walker variant. *Neurocase.* 2016;22(5):472-75.
- [10] Sidana A, Sarkar S, Balasundaram S, Praharaj SK. Increased sensitivity to atypical antipsychotics in a patient with Dandy-Walker variant with schizophrenia. *J Neuropsychiatr Clin Neurosci.* 2013;25(3):E31-32.
- [11] Bozkurt Zincir S, Kivlicim Y, Izci F, Semiz UB. Schizophrenia-Like Psychosis and Dandy-Walker Variant Comorbidity: Case Report. *Psychiatr Investig.* 2014;11(1):102-04.

PARTICULARS OF CONTRIBUTORS:

1. Resident, Department of Psychiatry, Lokmanya Tilak Municipal Medical College, Mumbai, Maharashtra, India.
2. Medical Officer, Department of Psychiatry, Lokmanya Tilak Municipal Medical College, Mumbai, Maharashtra, India.
3. Professor and Head, Department of Psychiatry, Lokmanya Tilak Municipal Medical College, Mumbai, Maharashtra, India.
4. Research Associate, Department of Psychiatry, Lokmanya Tilak Municipal Medical College, Mumbai, Maharashtra, India.

NAME, ADDRESS, E-MAIL ID OF THE CORRESPONDING AUTHOR:

Dr. Avinash Desousa,
Carmel, 18 St. Francis Road, Off SV Road, Santacruz West, Mumbai-400054, Maharashtra, India.
E-mail: avinashdes888@gmail.com

FINANCIAL OR OTHER COMPETING INTERESTS: None.

Date of Submission: **Oct 25, 2016**

Date of Peer Review: **Dec 28, 2016**

Date of Acceptance: **Mar 03, 2017**

Date of Publishing: **May 01, 2017**